



A Late Relapse in an Initial Stage I Pediatric Adrenal Cortical Tumor: Histology was Right!

Alexia Gazeu^{1*}, Cécile Faure Conter², Frédéric Hameury³, Pierre-Yves Mure³, Daniel Orbach⁴, Frédérique Dijoud¹ and Cécile Picard¹

¹Multisite Institute of Pathology, Groupement Hospitalier Est, Hospices Civils de Lyon, France

²Department of Pediatric Oncology, Institute of Pediatric Hematology and Oncology, France

³Department of Pediatric Visceral Surgery, Groupement Hospitalier Est, Hospices Civils de Lyon, France

⁴SIREDO Oncology Center, Institute Curie, PSL University, France

Abstract

A late relapse in an initial stage I pediatric adrenal cortical tumor: Histology was right!

Stage I adrenal cortical tumor stand as tumor with good prognosis. Therefore, treatment recommendations of such benign-appearing lesions are assessed on the basis of the disease stage regardless of microscopical findings.

We present the case of a 6-year-old girl displaying an initial COG stage I disease, who relapsed at distant site about 2 years after diagnosis. Histological examination of the initial lesion was however evocative of an aggressive disease. Histological findings could have been raised as a “red flag” to discuss adjuvant therapy or strict follow-up.

Introduction

Pediatric Adrenocortical Tumors (ACTs) are rare, representing only 0.2% of all pediatric malignancies and 5% of all adrenal tumors [1]. They are distinct from their adult counterpart regarding tumorigenesis and outcome, particularly before the age of 4 years old [2]. Assessing with reliability the prognostic of these lesions is still the most challenging question in this field and has been the source of numerous publications [1-6]. The tumor staging has been proved to clearly determined malignancy. It was even claimed sufficient enough in several large series to predict with accuracy the excellent prognostic of stage I tumors, regardless of histological features [3-5]. The lack of pathognomonic pathological features of malignancy in ACTs makes the prognostic evaluation challenging, especially in discriminating benign adenoma from malignant tumor with still some tumors classified in a “grey zone” of intermediate risk. We aimed to highlight the value of histological features in a case of a 6 years old girl with initial stage I disease, who relapsed secondly at distant site.

Case Presentation

We reported the case of a 6 year-old-girl, who presented with progressive virilization, namely pubic hair and enlarged clitoris. Plasma androstenedione Dehydroepiandrosterone Sulfate (DHEA-S) concentrations were abnormally high, measured at 5930 nmol/l normal values for the age: 320 ± 250 nmol/L). An abdominal CT scan showed a left adrenal cortical tumor measuring 5 cm (Figure 1A). It appeared well-defined with neither invasion of surrounding structures nor vascular thrombosis. No other distant lesion was found at this time. A complete surgical resection was performed, including the left adrenal gland and a part of the renal capsule. The tumor resection appeared complete without tumor rupture. The tumor was well-defined, weighting 50.4 g and measuring 5 cm along its longer axis. It exhibited small central yellow areas evocative of necrosis (Figure 1B).

At microscopic examination, the tumor was made up of sheets of variable-sized polygonal cells with an eosinophilic cytoplasm. There was marked cellular pleomorphism with some multinucleated cells. Nuclei were often large and hyperchromatic. Mitoses were present, including atypical mitotic figures, with a high mitotic rate reaching 6 mitoses for 10 HPF in hot spots. There was evidence of confluent partially calcified necrosis areas. The tumor also exhibited capsular and adrenal vein invasion (Figure 2A). Tumor resection was complete without extension into the surrounding soft

OPEN ACCESS

*Correspondence:

Alexia Gazeu, Department of Pathology, Groupement Hospitalier Est, Hospices Civils de Lyon, Lyon 1 University, Lyon, France, Tel: +33-0427856235; Fax: +33-0472357067;

E-mail: alexia.gazeu@chu-lyon.fr

Received Date: 17 Mar 2021

Accepted Date: 09 Apr 2021

Published Date: 15 Apr 2021

Citation:

Gazeu A, Conter CF, Hameury F, Mure P-Y, Orbach D, Dijoud F, et al. A Late Relapse in an Initial Stage I Pediatric Adrenal Cortical Tumor: Histology was Right!. *Clin Oncol.* 2021; 6: 1796.

Copyright © 2021 Alexia Gazeu. This is an open access article distributed under the Creative Commons Attribution License, which permits unrestricted use, distribution, and reproduction in any medium, provided the original work is properly cited.

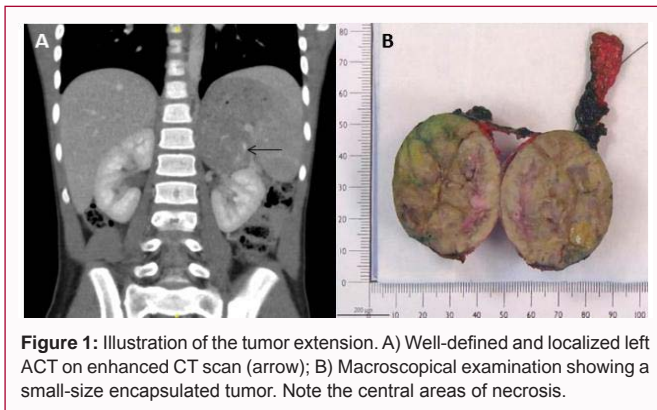


Figure 1: Illustration of the tumor extension. A) Well-defined and localized left ACT on enhanced CT scan (arrow); B) Macroscopical examination showing a small-size encapsulated tumor. Note the central areas of necrosis.

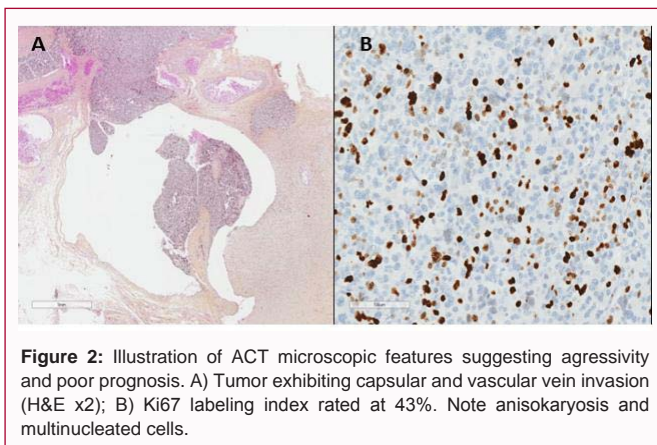


Figure 2: Illustration of ACT microscopic features suggesting aggressivity and poor prognosis. A) Tumor exhibiting capsular and vascular vein invasion (H&E x2); B) Ki67 labeling index rated at 43%. Note anisokaryosis and multinucleated cells.

tissue. The Ki67 proliferation index was strikingly high, evaluated at 43% by manual count on at least 2000 tumor cells (Figure 2B). Two lymph nodes were free of any tumoral invasion. There were no genetic or epigenetic alterations associated and neither p53 mutation nor chromosome 11p abnormalities were found. Germline *TP53* mutations and Beckwith Wiedmann syndrome were ruled out.

Then it was a local stage I disease according to the COG tumor staging (tumor completely resected with negative margins, no metastasis and weight <100 g). The Weiss and the Wieneke score were respectively 6/9 and 4/9, favoring malignancy. Microscopic five-items score was 4/5 (capsular invasion, venous invasion, confluent necrosis, and Ki67 \geq 15%). Based on stage I disease recommendations, a follow up including laboratory tests and abdominal ultrasound were initiated, without adjuvant therapy. DHEA returned to normal value after surgery and postoperative imaging showed a complete loco-regional remission. Twenty-three months after initial surgery, laboratory findings showed a significant increase of DHEA, measured at 1,1467 nmol/l in a patient experiencing a mild fatigue. A computed tomography scan objectified confluent pleuro-pulmonary lesions measuring 45 mm and mediastino-hilar and cervical lymph nodes enlargement without local relapse. A surgical biopsy of the mediastinal mass revealed an aggressive tumor lesion that shared similar microscopic features with the initial adrenal left gland tumor, confirming the diagnosis of thoracic metastasis. A chemotherapy based on etoposide-cisplatin-doxorubicin in association with mitotane was introduced. After four cycles of chemotherapy, her pleuro-pulmonary and mediastino-hilar lesions were reduced by 32% and DHEA had returned to its normal value. A surgery of the residual mediastinal lesions was performed. At microscopic

examination, there were some persistent areas of viable tumoral cells but post-chemotherapy-induced-changes were largely predominant, characterized by foamy macrophages, soft tissue calcifications and fibrosis. The surgical resection was microscopically complete (R0). Local radiation therapy is ongoing, combined with mitotane.

Discussion

We report an exceptional case of relapsing initial COG stage I ACT in a child, highlighting the crucial prognostic value of microscopic features, even in this type of tumor with a clinically benign appearing behavior. ACT occurs rarely in children and its evolution remains unpredictable in numerous cases. COG tumor staging and histology are essential prerequisites in ACT to establish prognosis and guide current treatment recommendations [2,3]. Numerous studies have highlighted specifically the independent overall good prognosis of stage I diseases [3,5,6]. This subtype represents the majority of ACT in children and depicts a 5-year event-free survival usually greater than 85%, sometimes equal to 100% [4,5]. In our large series of 95 cases, 59% of patients had stage I tumors and all were cured after surgery with no relapse occurring during follow-up [7]. Such observations conduct to define a clear consensual treatment algorithm for these patients, namely surgery alone with simple hormonal monitoring. In such cases, histological examination might think to be a minor data, appearing only relevant for clinical decision from the stage II. Stage I tumors depict indeed usually very few pejorative histologic criteria, as defined by pathological scoring.

In our study, we proposed a simple and reliable microscopic score by selecting four discriminant microscopic items, associated to the Ki-67 index [1]. This score appeared to be notably interesting to stratify tumors with favorable vs. unfavorable histology, especially in localized disease. The present patient, who belonged to our previous series, relapsed after less than 2 years despite having initial stage I, small and localized completely excised tumor according to the COG staging. Histologically, the tumor displayed unfavorable microscopic with a Wieneke score at 4/9 and a 5-item microscopic score at 4/5 including a strikingly high Ki67 index at 43%, criteria favoring malignancy [8]. She was the only stage I patient in our series with such high 5-items score and Ki67 level. Of note, only 4 out of 50 stage I tumors had an unfavorable histology (data not available for 5), with 3 displaying a 3/5 score and this sole present case a score of 4/5. These findings could have been raised as a “red flag” to discuss adjuvant therapy or strict follow-up in these peculiar cases.

We found it relevant to present this singular case to emphasize that macroscopic features and adequate resection evaluation are not sufficient on their own to ensure proper outcome prediction, even in localized stage I ACT. A discriminant score with a trustworthy threshold composed of pertinent microscopic items and Ki67 index labeling should be put forward to accurately predict the prognosis and properly assess an adequate treatment and follow-up whatever the disease staging.

Finally, this case should also be kept in mind regarding tumor size reduction after second-line chemotherapy. Indeed, in pediatric ACTs, second-line therapy has usually a very low impact on survival and is unfortunately often regarded as a palliative situation [7].

Conclusion

We described a case of an initial stage I pediatric adrenocortical tumor, which displayed reassuring macroscopic features but

unfavorable microscopic findings. Her relapse highlights that histological items are paramount in order to establish an efficient scoring system that can help to guide treatment decisions.

References

1. Picard C, Orbach D, Carton M, Brugieres L, Renaudin K, Aubert S, et al. Revisiting the role of the pathological grading in pediatric adrenal cortical tumors: Results from a national cohort study with pathological review. *Mod Pathol*. 2019;32(4):546-59.
2. Kastenber ZJ, Scaife ER. Adrenocortical tumors in children. *Semin Pediatr Surg*. 2020;29(3):150927.
3. Pinto EM, Zambetti GP, Rodriguez-Galindo C. Pediatric adrenocortical tumours. *Best Pract Res Clin Endocrinol Metab*. 2020;34(3):101448.
4. Michalkiewicz E, Sandrini R, Figueiredo B, Miranda ECM, Caran E, Oliveira-Filho AG, et al. Clinical and outcome characteristics of children with adrenocortical tumors: A report from the International Pediatric Adrenocortical Tumor Registry. *J Clin Oncol*. 2004;22(5):838-45.
5. Ribeiro RC, Pinto EM, Zambetti GP, Rodriguez-Galindo C. The International Pediatric Adrenocortical Tumor Registry initiative: Contributions to clinical, biological, and treatment advances in pediatric adrenocortical tumors. *Mol Cell Endocrinol*. 2012;351(1):37-43.
6. Beuschlein F, Weigel J, Saeger W, Kroiss M, Wild V, Daffara F, et al. Major prognostic role of Ki67 in localized adrenocortical carcinoma after complete resection. *J Clin Endocrinol Metab*. 2015;100(3):841-9.
7. Picard C, Faure-Conter C, Leblond P, Brugières L, Thomas-Teinturier C, Hameury F, et al. Exploring heterogeneity of adrenal cortical tumors in children: The French pediatric rare tumor group (Fracture) experience. *Pediatr Blood Cancer*. 2020;67(2):e28086.
8. Jehangir S, Nanjundaiah P, Sigamani E, Burad D, Manipadam MT, Lea V, et al. Pathological prognostication of paediatric adrenocortical tumours: Is a gold standard emerging? *Pediatr Blood Cancer*. 2019;66(4):e27567.