



Transanal vs. Laparoscopic Transabdominal Intersphincteric Resection for Lower Rectal Cancer: Comparison of the Operative and Functional Outcomes

Acquah Theophilus^{1,2}, Zhi-Hong Chen^{1*}, Zakari Shaibu^{1,2}, Yu Fang¹, Jun Liu¹ and Muhammad Asad Iqbal^{1,2}

¹Department of Gastrointestinal Surgery, Affiliated People's Hospital of Jiangsu University, China

²School of Medicine, Jiangsu University, China

Abstract

Background: Laparoscopic transabdominal Intersphincteric Resection (ISR) is a complex and challenging operation for lower rectal cancer.

Aim: The study's objective was to evaluate and compare the postoperative outcomes between transanal intersphincteric resection and transabdominal intersphincteric resection for rectal carcinoma patients based on operative and functional outcomes.

Materials and Methods: Between January 2009 and August 2017, 53 consecutive patients with lower rectal cancer who underwent laparoscopic curative ISR treatment were evaluated from the Department of Gastrointestinal Surgery, Affiliated People's Hospital of Jiangsu University. Patient groups were classified into as TA-ISR (n=31) and LT-ISR (n=22) groups.

Results: In total, 53 patients were analyzed. The studies investigated postoperative outcomes such as operative results, morbidity, mortality, and postoperative follow-up results. The operation's mean duration was 212 (69.9) in the transanal ISR and 180.1 (36.7) in the laparoscopic transabdominal ISR. The blood loss in the two groups was 68.7 (32.4) and 78.4 (37.9), respectively. Nevertheless, there was no perioperative mortality, complications occurred in 7 patients, and the morbidity rate was 16.1% (5/31) in the transanal ISR, including one anastomotic leakage, one anastomotic stricture, one urinary retention, 1 intra-abdominal abscess, and one subclinical dehiscence and 9.1% (2/22) in the laparoscopic transabdominal ISR consisting of 1 anastomotic stricture and 1 urinary retention and all patients with complications were managed through conservative treatments. The postoperative local recurrence was 12.9% in the transanal ISR and 4.5% with the laparoscopic transabdominal ISR.

Conclusion: Transanal and laparoscopic transabdominal ISR yielded similar operative and functional outcomes in patients with lower rectal cancer, despite the difference in follow-up time.

Keywords: Internal sphincter resection; Laparoscopic surgery; Intersphincteric resection; Rectal cancer

OPEN ACCESS

*Correspondence:

Zhi-Hong Chen, Department of Gastrointestinal Surgery, Affiliated People's Hospital of Jiangsu University, 8 Dianli Road, Zhenjiang, Jiangsu Province, 212002, China, E-mail: chengzhi-hong@163.com

Received Date: 03 Mar 2021

Accepted Date: 06 Apr 2021

Published Date: 09 Apr 2021

Citation:

Theophilus A, Chen Z-H, Shaibu Z, Fang Y, Liu J, Iqbal MA. Transanal vs. Laparoscopic Transabdominal Intersphincteric Resection for Lower Rectal Cancer: Comparison of the Operative and Functional Outcomes. *Clin Oncol.* 2021; 6: 1792.

Copyright © 2021 Zhi-Hong Chen. This is an open access article distributed under the Creative Commons Attribution License, which permits unrestricted use, distribution, and reproduction in any medium, provided the original work is properly cited.

Introduction

Rectal cancer located less than 5 cm from the edge of the tumour to the anal verge was traditionally treated with Abdominoperineal Resection (APR) operation [1]. To improve patients' quality of life with rectal adenocarcinoma, the Intersphincteric Resection (ISR) was developed in the 1980s and was well accepted in the 1990s [2]. This procedure is beneficial in the sense that it is essential in doing away with permanent colostomy in patients with rectal adenocarcinoma. The ISR procedure involves the resection of part or all of the internal sphincters from the anus and the restoration of bowel function while obtaining enough margins for rectal cancers involving or close to the anal canal [2].

The effectiveness of ISR currently makes it the preferred surgical standard for surgical treatment for sphincter preservation and excision for extremely low rectal cancer, and both the short term and oncological outcomes have been reported to be positive [3-5]. According to Yamamoto et al. [2] regardless of the positive features of the ISR, most studies on the efficacy of the procedure have been mainly on open ISR, with little on laparoscopic ISR. However, an important fact about laparoscopic

surgery is that it has the shortcoming of limited two-dimensional views. Given the limitation, laparoscopic ISR, considered the ultimate type of sphincter-saving operation for lower rectal cancer, is challenging even for well-experienced laparoscopic surgeons, particularly when faced with the narrow and curved pelvic space.

In the current report, the first operative step of all patients was laparoscopic trans-abdominal pelvic colonic mobilization. The second step of the surgery (ISR step) was divided into transanal ISR and laparoscopic transabdominal ISR. Clinical data of 53 cases were collected from patients who had undergone laparoscopic ISR treatment of lower rectal cancer and transanal ISR.

The aim of the study is to compare the operative, oncological, and functional outcomes of the two procedures, thus; transanal and laparoscopic transabdominal ISR for lower rectal cancer.

Materials and Methods

Patient recruitment

Institutional database retrieved between January 2009 and August 2017, 53 consecutive patients with lower rectal adenocarcinoma underwent laparoscopic curative ISR at the Department of Gastrointestinal Surgery, Affiliated People's Hospital of Jiangsu University. We've had TATME surgery and the outcomes we've had TATME surgery are all good. The outcomes of the TATME surgery we did were not included in this article. In 31 cases, the separation between the internal and external sphincters was performed through the anal procedure (transanal ISR group). The other 22 cases were entirely under laparoscope *via* the intra-abdominal method (laparoscopic transabdominal ISR group). Among them, there were 16 males and 15 females with an average age of 61.1 years for those who were in the Transanal (TA) ISR group while equal males and females (11:11) with an average of 60.2 years were in the Laparoscopic Transabdominal (LT) ISR group. The evaluation included physical examination, barium enema, colonoscopy with biopsy, chest, abdominal and pelvic Computed Tomography (CT), pelvic Magnetic Resonance Imaging (MRI), and endorectal ultrasonography were performed in all patients. Also the cardiorespiratory function and pulmonary metastases were examined before operation and all patients were suitable for inclusion in the standard and there was no pulmonary metastasis. All depths of tumour invasion were preoperatively proven to be less than or equal to T2 and without extension into the external anal sphincter or the levator ani muscle.

Inclusion criteria:

- Histopathology has been confirmed as rectal cancer;
- The distance of the tumor from the edge is 2.0 cm to 5.0 cm;
- Histological classification as pap, tubular adenocarcinoma (tub): High differentiation (tub and differentiation (tub 2));
- T1-2 N0/1-2 M0 is discussed in the multidisciplinary Mode of Diagnosis and Treatment (MDT);
- Between the ages of 18 and 80;
- Good blood, heart, liver and kidney function;
- Understand and volunteer to participate in this clinical trial and sign an informed consent.

Exclusion criteria:

- Persons with dysfunction;

- The tumor has been immersed in the sphincter or the muscle;
- Histological classification as hypolytic adenocarcinoma (por), inoculation of cell carcinoma (sig) and mucus cell carcinoma (muc);
- The merger has other malignant tumors;
- Received chemotherapy and anti-tumor treatment;
- Have received more than three levels of surgical treatment within one month;
- Combined with congestive heart failure;
- A history of unstable angina and myocardial infarction;
- Patients who are less dependent and unwilling to cooperate with the examination and treatment.

Surgical technique

Before the operation, all patients underwent a similar bowel preparation. The patients were placed in a Lloyd-Davis position under general anesthesia, with the perineum slightly projecting from the end of the operating table. The surgical procedure comprised of three stages.

The first step of surgery is a laparoscopic trans-abdominal pelvic procedure. The initial camera port was inserted into the right side of the umbilicus. The abdomen was insufflated with CO₂ to an intra-abdominal pressure of 12 mmHg. After careful inspection of the liver and the entire abdomen for evidence of carcinomatosis, a 5 mm port was placed in the left lower quadrant, and another 12 mm trocar was placed in the planned right lower quadrant ileostomy site. The other two 5 mm ports were placed respectively outside of the rectus abdominis that were parallel to the umbilicus. Colonic mobilization, including the release of the splenic flexure and low ligation of the inferior mesenteric artery and vein (complete dissection of no. 253 lymph nodes). The proximal division of the mesentery along with the left Toldt's space was carried out and extended down. The procedure used was the Laparoscopic Total Mesorectum Excision (LA-TME) technique with complete preservation of the autonomic nervous system. On both sides of the rectum, the lateral ligament was separated into the level of levator ani muscle. The ligation of sigmoidal colon vessels was performed with dissection of no. 252 lymph nodes.

The second step of the surgery included two procedures. All patients were treated with at least 1 cm ~ 2 cm of distal free margin (at least 2 cm for T2 tumors or 1 cm for T1 tumors). Before rectal transaction, the rectal lumen was routinely washed out. One procedure was that internal-external sphincters were separated through the operation of the anal part (Figure 1). The skin on the anus verge was dragged with suture lines at 2, 5, 7, and 10 o'clock along with the supplementary application of a self-holding retractor positioned into the anal canal with comfortable access before circular incision. The injection of diluted norepinephrine (1:2 000 000) was performed to prevent intraoperative bleeding at the anticipated circular incision. After then, a circular incision of the anoderm and internal sphincter above intersphincteric groove was performed, and the internal sphincter was separated from the external sphincter and puborectalis muscle. The anal orifice was closed with a purse-string suture after the anoderm, and subcutaneous tissue had been resected to avoid possible implantation of free tumour cells in fecal matter. To obtain an optimal distal margin of the tumour, the extent of ISR determined

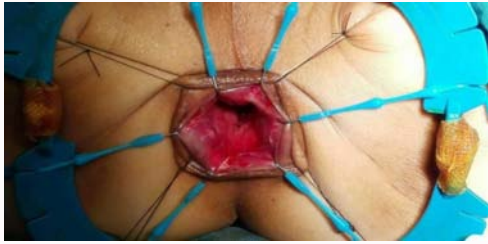

Figure 1: Surgical illustration and photographs of transanal ISR procedure.

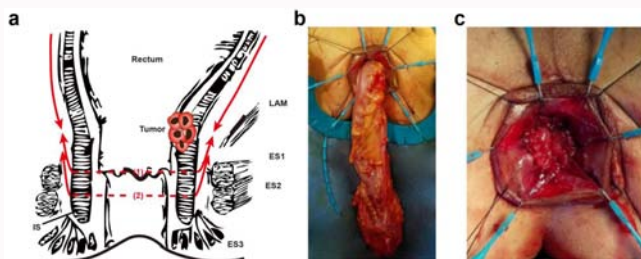


Figure 2: Surgical illustrations of transabdominal ISR procedure.

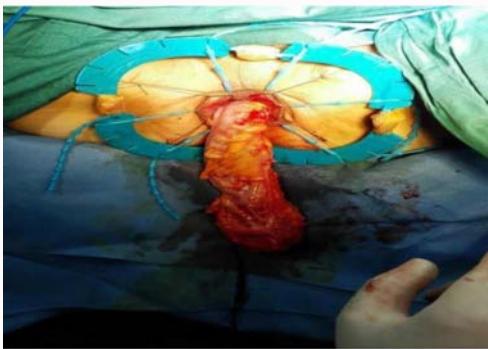

Figure 3: The specimen was pulled down *via* anus.

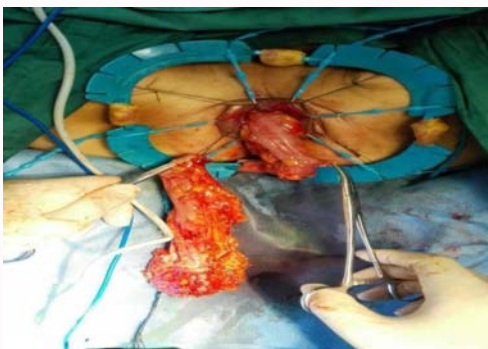


Figure 4: Resection of rectal specimen.

whether a partial or subtotal ISR was needed. The distal resection margin reached the dentate line in partial ISR, and the margin was obtained between the dentate line and the intersphincteric groove in subtotal ISR. After circular dissection of the tumour-bearing rectum, the specimen was delivered per anally (Figure 2). After resection of the rectal specimen and the corresponding mesentery (Figure 3), the coloanal anastomosis was performed between the colon and the remaining internal sphincter and anoderm using the transanal hand-sewn technique (Figure 4).

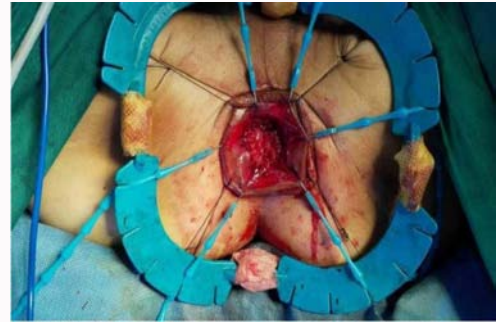


Figure 5: Coloanal anastomosis by the handsewn technique.

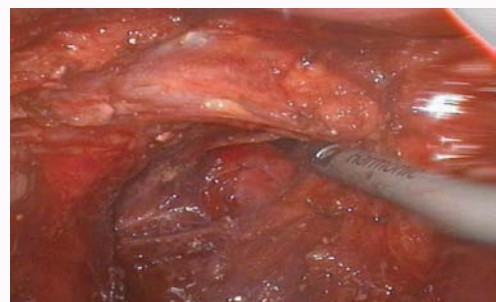

Figure 6: The internal-external sphincter separation and circular excision of the tumour-bearing rectum were performed completely under laparoscope via the rectum; external sphincter; puborectalis muscle.

Another procedure (transabdominal ISR including transabdominal ISR with transabdominal transection of 8 cases and transabdominal ISR with transanal transection of 14 cases) (overall being 22 cases) was that internal-external sphincter separation and circular excision of the tumour-bearing rectum were performed completely under laparoscope via the intra-abdominal operation (Figure 5). The extent of partial or subtotal ISR was the same as that of the transanal ISR procedure. Transabdominal transection procedure (8 cases). Rectal transection was performed with articulating endoscopic linear cutter (Ethicon Endosurgery LLC; 475 Calle C, 00969 Guaynabo, Puerto Rico USA) introduced through the 12-mm port under the condition that the anus was pushed up by a fist. A 4-cm incision was then made over the mid-lower site, and the bowel was exteriorized under wound protection and divided with appropriate proximal clearance. The anastomosis was performed using the double-stapling technique. Rectal transection was performed referring to the transanal ISR operation, a self-holding retractor was applied, a circular incision of the anoderm and internal sphincter above intersphincteric groove was performed. After specimen removal, the colon was pulled down via the anus and a coloanal anastomosis was performed using the transanal hand-sewn technique. There was no abdominal incision in laparoscopic ISR followed by hand-sewn anastomosis except for trocar ports (Figure 6).

Finally, a pelvic drain was placed laparoscopically, and a protective diverting ileostomy was created by using a port site if necessary, with closure planned for 3 months later. The drainage tube was placed inside the anal canal with the purpose of decompression.

Follow-up

Patients were followed up every 3 months for the first 2 years and every 6 months for the next 3 years, and once annually thereafter. Clinical examination, serum Carcinoembryonic Antigen (CEA),

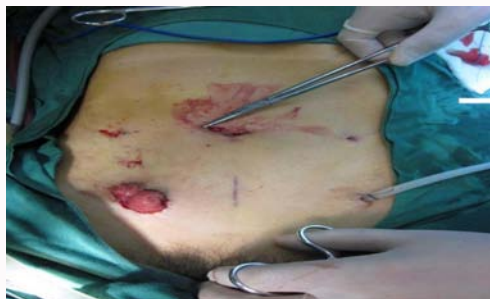

Figure 7: There was not any abdominal incision in laparoscopic transabdominal ISR followed by hand-sewn anastomosis except for trocar port.

and carbohydrate antigen 199 (CA199) were measured at each visit. Full colonoscopy was performed annually after surgery. Chest X-rays, abdominopelvic CT, and digital rectal examinations were also performed at each visit. The last follow-up was in February 2019. Eleven patients with stage II or III tumors received postoperative adjuvant systemic chemotherapy with 5-fluorouracil and leucovorin.

Anal function assessments: Functional outcomes were assessed using hospital follow questionnaires. We collected questionnaires regarding anal function from our patients 3 months after closure of the diverting stoma. In the questionnaire, patients were asked stool urgency (ability to pass stool for 10 min to 15 min), stool frequency (number of stool passed in 24 h), dyschesia (taking more than 15 min to defecate), the use of internal laxatives before defecations and need to wear a pad. Anastomotic stricture was determined when the surgeon's forefinger could not through the anastomotic site 3 months after surgery.

Statistical analysis

All statistical analyses were performed using the SAS 9.0 software (SAS Institute) for Windows. Differences between groups were assessed by ANOVA test. Variables expressed as proportions were compared using the χ^2 test or the Fisher exact test, where appropriate. $P < 0.05$ was considered statistically significant.

Results

In light of this, the two procedures grouped patients based on the clinical data obtained concerning the analysis undertaken. These groups were compared retrospectively on some fundamental and critical aspects, including; operative, oncological, and functional outcomes. For the purpose of this study, none of the patients were converted to open procedures. The result is presented as follows:

The result presented in Table 1 shows patients' characteristics representing a significant number of indicators. Comparatively, on

Table 1: Patient's characteristics.

Indicators	Transanal ISR (n=31)	Laparoscopic transabdominal ISR (n=22)	P value
Age (years)*	61.1 (11.6)	60.2 (11.40)	1.000 ^a
Gender ratio (M:F)	16:15	11:11	0.67
Distance from anal verge (mm) #	35.5 (9.81)	45.2 (9.30)	0.024*
Preoperative serum CEA (ng/ml)*	6.2 (13.9)	50.6 (118.74)	1.000 ^a
Preoperative serum CA199 (IU/ml)*	19.5 (12.50)	49.3 (115.53)	0.241
Previous abdominal surgery, n (%)	5 (11.6)	4 (9.31)	-

*Values are mean \pm standard deviation

#Distance between the distal margin of the tumor and the anal verge

^aFisher exact test

average, most of the Transanal ISR group (TA ISR) members were 61.1 years of age whilst the Laparoscopic Transabdominal ISR (LT ISR) group or patients were 60.2 years of age. Similarly, the male to female ratio for TA ISR patients was 16:15 whilst that of LT ISR was 11:11. This shows an equal sample size of gender for LT ISR patients. About BMI, TA ISR patients on average were 35.5 kg/m² whilst that of LT ISR was 45.2 kg/m². Comparatively, the result shows no significant difference between TA ISR and LT ISR patients regarding all baseline clinical characteristics, such as age, gender, Body Mass Index (BMI) and the Preoperative serum CEA, [$p > 0.05$], except for distance from anal verge that was found to be significant [$p < 0.05$]. This shows that based on clinical baseline features, only the BMI of patients differed across TA ISR and LT ISR patients. It clearly indicates that patients who underwent intersphincteric resection for lower rectal cancer differ across BMI concerning TA ISR and LT ISR.

The distance from the inferior margin of tumors to the anal verge ranged from 2.0 cm to 5.0 cm. According to preoperative histological classification, four patients with villous adenoma had recurrence after an endoscopic operation. Patients with poorly differentiated adenocarcinoma diagnosed by biopsy or impaired fecal continence and missing follow-up data were excluded. Preoperative radiotherapy or chemotherapy was not performed.

Operative and postoperative outcomes

The operative and postoperative outcomes were analyzed comparatively based on transanal ISR and laparoscopic transabdominal ISR. The result is presented in Table 2. Some of the indicators examined included ISR or operation procedure, partial and sub-total ISR, operative time, operative blood loss, protective stoma, postoperative hospital stays, and postoperative morbidity, etc.

The operative result is presented in Table 2. The summary of the result shows diverse dimensions to both operative and postoperative pathological diagnosis. About discoveries made with regards to operative results, similar outcomes were discovered in terms of the ISR operation procedure, operation time, protective stoma, postoperative hospital stay, and postoperative morbidity except for operative blood loss. This shows that all the ISR indicators were not statistically significant at [$p > 0.05$], however, blood loss was significantly different across the two ISR procedures at [$p < 0.05$]. The result implies that on average more blood is lost to laparoscopic transabdominal ISR as compared to transanal ISR due technical difficulties.

There was no postoperative mortality in either group. The patients of the two groups did not show complications of wound infection, rectovaginal fistula, anastomotic bleeding, ileus, chylous ascites and pneumonia. One patient got partial anastomotic subclinical dehiscence in a week and another patient got postoperative anastomotic leakage on the 12th day after the procedure, both of whom were managed

Table 2: Operative results and postoperative pathological diagnosis.

Indicators	Transanal ISR (n=31)	Laparoscopic transabdominal ISR (n=22)	P-value
ISR procedure	31	22	-
Partial ISR	11	15	
Sub-Total ISR	20	7	
Operation time (min)*	212 (69.9)	180.1 (36.7)	1.000 ^a
Blood loss (ml)*	68.7 (32.4)	78.4 (37.9)	0.049*
Protective Stoma, n (%)	0.67 (.48)	0.35 (.49)	0.6
Postoperative hospital stay (days)*	16.3 (10.1)	14.5 (4.9)	0.667
Morbidity, n (%)	5 (16.1)	2 (9.1)	
Anastomotic Subclinical	1 (3.2)	0 (0)	
Dehiscence intraabdominal abscess	1 (3.2)	0 (0)	
Anastomotic leakage	1 (3.2)	0 (0)	
Anastomotic Stricture	1 (3.2)	1 (4.5)	
Urinal Retention	1 (3.2)	1 (4.5)	
Tumor size (mm)* [†]	37.9 (13.2)	40.9 (22.7)	1.000 ^a
Distal margin (mm)*	1.56 (.61)	1.92 (1.54)	0.892
CRMI, n (%)	1 (3.2)	0 (0)	
Histologic differentiation, n (%)	23 (74.3)	22 (100.0)	
• Well	3 (9.7)	4 (12.9)	
• Moderate	26 (83.9)	18 (58.1)	
• Poor	2 (6.5)	1 (3.2)	
PT category, n (%) T0	31 (100.0)	22 (100.0)	
• T1	8 (25.8)	13 (41.1)	
• T2	7 (22.6)	3 (9.7)	
• T3	5 (16.1)	6 (19.4)	
PN category, n (%) N0	18 (58.1)	6 (0.27)	
N1	14 (45.2)	4 (0.18)	
N2	4 (12.9)	2 (0.09)	
PtTN Category, n (%)	31 (100.0)	22 (100.0)	
• I	19 (61.3)	18 (58.1)	
• II	5 (16.1)	28 (90.3)	
• III	7 (22.6)	25 (80.6)	

*Values are mean ± standard deviation. Values of the greatest dimension for each lesion. CRMI: Circumferential Resection Margin Involvement

[†]Fisher exact test

*Stage 0 indicates pathological complete remission

through conservative treatments. One patient got an anastomotic stricture, which required regular expansion. Additionally, the pathological examination of the specimens also showed similar outcomes in terms of the tumor size, the circumferential and distal margin status, the histologic differentiation, and pTNM stage (Table 2). Two patients were found local recurrence, and got survival with tumour after operation again during the follow-up period. On the 6th month after operation, the anal functions of all patients turned out to be on the stage I to II of Kirwan classification and one patient got anastomotic stricture, which required regular expansion. The postoperative local recurrence was 12.9% in the transanal ISR and 4.5% with the laparoscopic transabdominal ISR.

Follow-up results

It is vital to indicate that all patients completed the follow-up of oncological recurrence and anal function. Four patients (pT2N1M0, pT3N1M0; pT2N0M0, pT2N1M0) were found with local recurrence

between the 6th and 12th months after surgery and treated with APR operations again and survive with the tumour during the follow-up period. Other patients were found without local recurrence and distant metastasis during the follow-up examination period (Table 3). Also, 7 days after the operation, one patient had an opening at the anastomotic which was partially cracked, and the pelvic drainage was improved for 17 days. The anastomotic stenosis within 1 year after operation required regular anal enlargement and improvement. The ileostomy was performed at the end of 1 year after the operation, and the pulmonary embolism died during the perioperative period. Moreover, it is vital to explain that rectal and vaginal leaks were found 11 days after surgery, and the final ileostomy. Besides leakage repair was performed on the 12 postoperative days. To establish a significant difference with the two treatments based on follow-up indicators the result is shown as follows (Table 3).

The result shows that a similar outcome was discovered across

Table 3: Postoperative follow-up results.

	Transanal ISR (n=31)	Laparoscopic transabdominal ISR (n=22)	P value
Follow-up(months)*	35.4 (25.1)	18.5 (8.9)	0.009^a
Postoperative chemotherapy, n (%)	9 (29.0)	3 (9.7)	
Postoperative local recurrence, n (%)	4 (12.9)	1 (4.5)	
Anal function on the 6 th a month after surgery, n (%)			
Kirwan classification			
Stage I	5 (16.1)	5 (0.22)	
Stage II	13 (41.9)	5 (0.22)	
Stage III	0 (0)	0 (0)	

*Values are mean ± standard deviation

^aFisher exact test

the two treatment groups except for follow-up results. The follow-up result shows significant differences across the two treatment groups at [$p < 0.05$]. Besides, the anal function was evaluated according to the Kirwan classification of continence. The anal function of all patients fell into stage I and stage II in the 6th month after surgery (Table 3). All patients were satisfied with the functional results.

Discussion

Schiessel et al. [6] in 1994 described the technique of ISR for low rectal tumors. Watanabe et al. [7] in 2000 described in a technical note 7 cases of laparoscopic ISR for lower rectal cancer. The current laparoscopic ISR reports are very limited, so the surgical approach has not been described through the systematic classification [8-13]. Our report systematically describes the laparoscopic ISR operation steps.

Previous studies compared two procedures that have arguably been preferred procedures for patients with rectal cancer, as compared to the older established abdominoperineal resection procedure [1,3,14]. However, several studies have not been able to explicitly identify which of the procedures are superior. In fact, per the researcher's review of literature, not a lot of studies exist with regards to comparing the two procedures. Laparoscopic ISR provides an excellent vision of the operative field in all steps of the procedure; this is a relevant factor to avoid any accidental damage to the left ureter, the hypogastric nerves, and the pelvic plexus. The pelvic floor can be well exposed and the lowest intersphincteric dissection can be accomplished for a partial ISR and even a small amount of subtotal ISR due to the magnified vision in laparoscopy. 22 cases were treated with transabdominal ISR, among whom, 16 cases received partial ISR, the other 6 cases received subtotal ISR. Nevertheless, laparoscopic stapling can be very demanding owing to the narrow pelvic cavity and arc shape of pelvic floor. ISR is the ultimate operation of the function protection for lower rectal cancer, but people are still concerned about whether this operation will result in high local recurrence and anal sphincter function obstacle. Yamada et al. [15] reported 35 patients with low rectal cancer treated with curative ISR with a distal margin of at least 2 cm for T2 or T3 tumors or 1 cm for T1 tumors.

In our studies postoperative outcome like; operation time, protective stoma, postoperative hospital stay, and postoperative morbidity were recorded and no significant differences were noted between transanal ISR and laparoscopic transabdominal ISR patients. No postoperative death was found and only 2 patients with local tumour recurrence in the two groups during the follow-up examination period. All patients had a good continence (stage I to II

of the Kirwan classification).

Furthermore, blood loss was significantly different across the two ISR procedures at [$p < 0.05$]. The result implies that on average more blood is lost to Laparoscopic transabdominal ISR as compared to Transanal ISR. But the study by Chen et al. [16] indicated that Laparoscopic intersphincteric resection records less blood loss when compared to the open approach for low rectal cancer. This was similar to the finding by Pai et al. [17] who established that median blood loss was higher in the open intersphincteric resection approach for low rectal cancer group compared to laparoscopic intersphincteric resection group. However, in this case the result was not significant. Similarly, in the study by Lin et al. [18] which considered 12 case-control studies that covered 899 patients established that there are no significant differences with regards to blood loss between transanal total mesorectal excision and conventional laparoscopic total mesorectal excision.

The patients of the two groups did not show the complications of wound infection, rectovaginal fistula, anastomotic bleeding, ileus, chylous ascites, and pneumonia. This finding is closely linked to those of Lin et al. [18] who established that in comparing transanal total mesorectal excision and conventional laparoscopic total mesorectal excision there were no significant differences with regards to intraoperative complications, overall postoperative complication, anastomotic leakage, and ileus. Similarly, Ma et al. [19] established that in comparing transanal total mesorectal excision and laparoscopic total mesorectal excision for rectal cancer; the transanal total mesorectal excision group exhibited no significant difference with regards to anastomotic leakage, ileus, and urinary morbidity. Meanwhile, in this study the morbidity rate was 16.1% and 9.1% in the laparoscopic transabdominal ISR.

Similarly, the Postoperative phase showed some significant differences in the follow-up. However, in this phase, the postoperative chemotherapy, postoperative local recurrence, and anal function all showed no significant difference. Several specialized studies have investigated ISR for low rectal cancer, and their local recurrence rates ranged from 0% to 12% [20,21]. Laparoscopic surgery has been attractive for curing colorectal diseases [22-24]. Recently, laparoscopic ISR in anus-saving treatment of lower rectal cancer have got more and more attention [25-28]. Byung-Eun et al. [29] reported 26 patients treated with laparoscopic ISR. The 3-year Overall Survival (OS), 3-year Recurrence-Free Survival (RFS), and 3-year local RFS were respectively 88.5%, 75.0% and 91.7%. Their Wexner score of function after ISR was 14.33 ± 5.79 . Dario Scala et al. [8] reported 57 patients treated with ISR with coloanal anastomosis. In this group

the average distance of the neoplasm from the anal verge was 4.6 cm with a 100% of R0 resections, a median distal clear margin of 1.8 cm, and a local recurrence rate of 5.26%. Cancer related mortality was 3.5% (2/57). Perioperative mortality was 0%. Major complications requiring a reoperation occurred in five patients (8.7%). About 75% of patients had a good or acceptable continence.

The limitations of our study include selection bias and a potentially underpowered analysis, given the small sample sizes. Laparoscopic surgery for advanced colon cancer has not yet replaced conventional open surgery as the standard, mainly because there is insufficient clinical evidence. Furthermore, there are also controversies regarding the level of difficulty of the individual procedures, the lack of data regarding oncological long-term outcomes for cancer after curative resection, the laparoscopic skills of surgeons, the treatment strategy in consideration of medical costs, and differences in patient demographics. We think that a large scale of randomized controlled study is originally necessary.

In conclusion, transanal and laparoscopic transabdominal ISR resulted in the same postoperative outcome, oncological, and functional outcomes in patients with lower rectal cancer, despite difference in follow-up time. However, laparoscopic transabdominal ISR is much safer and effective procedure for sphincter saving approach to lower rectal cancer, because laparoscopic vision has a good advantage for the mobilization of rectum in the pelvic floor. Laparoscopic ISR followed by hand sewn anastomosis has the further advantage to avoid any abdominal incision for the specimen extraction.

But the current study cannot draw a conclusive decision as to whether transanal ISR is superior to laparoscopic transabdominal ISR, or *vice versa*, but there is a need for further study with larger sample size.

Acknowledgement

The authors thank professor Zhi-hong Chen and Dr. Zakari Shaibu for their input towards the review and completion of our paper.

Funding

This study was supported by the National Science Foundation of China (Grant Number: 81472334).

References

- Park IJ, Kim JC. Intersphincteric resection for patients with low-lying rectal cancer: Oncological and functional outcomes. *Ann Coloproctol*. 2018;34(4):167-74.
- Yamamoto S, Fujita S, Akasu T, Inada R, Takawa M, Moriya Y. Short-term outcomes of laparoscopic intersphincteric resection for lower rectal cancer and comparison with open approach. *Dig Surg*. 2011;28(5-6):404-9.
- Akasu T, Takawa M, Yamamoto S, Yamaguchi T, Fujita S, Moriya Y. Risk factors for anastomotic leakage following intersphincteric resection for very low rectal adenocarcinoma. *J Gastrointest Surg*. 2010;14(1):104-11.
- Chamlou R, Parc Y, Simon T, Bennis M, Dehni N, Parc R, et al. Long-term results of intersphincteric resection for low rectal cancer. *Ann Surg*. 2007;246(6):916-22.
- Portier G, Ghouti L, Kirzin S, Guimbaud R, Rives M, Lazorthes F. Oncological outcome of ultra-low coloanal anastomosis with and without intersphincteric resection for low rectal adenocarcinoma. *Br J Surg*. 2007;94(3):341-5.
- Schiessel R, Karner-Hanusch J, Herbst F, Teleky B, Wunderlich M. Intersphincteric resection for low rectal tumours. *Br J Surg*. 1994;81(9):1376-8.
- Watanabe M, Teramoto T, Hasegawa H, Kitajima M. Laparoscopic ultralow anterior resection combined with per anum intersphincteric rectal dissection for lower rectal cancer. *Dis Colon Rectum*. 2000;43(10):S94-7.
- Scala D, Niglio A, Pace U, Ruffolo F, Rega D, Delrio P. Laparoscopic intersphincteric resection: Indications and results. *Updates Surg*. 2016;68(1):85-91.
- Maglio R, Meucci M, Muzi MG, Maglio M, Masoni L. Laparoscopic total mesorectal excision for ultralow rectal cancer with transanal intersphincteric dissection as a first step: A single-surgeon experience. *Am Surg*. 2014;80(1):26-30.
- Funahashi K, Shiokawa H, Teramoto T, Koike J, Kaneko H. Clinical outcome of laparoscopic intersphincteric resection combined with transanal rectal dissection for T3 low rectal cancer in patients with a narrow pelvis. *Int J Surg Oncol*. 2011;2011.
- Kuo LJ, Hung CS, Wang W, Tam KW, Lee HC, Liang HH, et al. Intersphincteric resection for very low rectal cancer: Clinical outcomes of open versus laparoscopic approach and multidimensional analysis of the learning curve for laparoscopic surgery. *J Surg Res*. 2013;183(2):524-30.
- Shiomi A, Kinugasa Y, Yamaguchi T, Tsukamoto S, Tomioka H, Kagawa H. Feasibility of laparoscopic intersphincteric resection for patients with cT1-T2 low rectal cancer. *Dig Surg*. 2013;30(4-6):272-7.
- Zhang B, Zhao K, Liu Q, Yin S, Zhuo G, Zhao Y, et al. Clinical and functional results of laparoscopic intersphincteric resection for ultralow rectal cancer: Is there a distinction between the three types of handsewn coloanal anastomosis? *Int J Colorectal Dis*. 2017;32(4):587-90.
- Bretagnol F, Rullier E, Laurent C, Zerbib F, Gontier R, Saric J. Comparison of functional results and quality of life between intersphincteric resection and conventional coloanal anastomosis for low rectal cancer. *Dis Colon Rectum*. 2004;47(6):832-8.
- Yamada K, Ogata S, Saiki Y, Fukunaga M, Tsuji Y, Takano M. Functional results of intersphincteric resection for low rectal cancer. *Br J Surg*. 2007;94(10):1272-7.
- Chen K, Cao G, Chen B, Wang M, Xu X, Cai W, et al. Laparoscopic versus open surgery for rectal cancer: A meta-analysis of classic randomized controlled trials and high-quality nonrandomized studies in the last 5 years. *Int J Surg*. 2017;39:1-10.
- Pai VD, Sugoop P, Patil PS, Ostwal V, Engineer R, Arya S, et al. Laparoscopic versus open approach for intersphincteric resection-results from a tertiary cancer center in India. *Indian J Surg Oncol*. 2017;8(4):474-8.
- Lin D, Yu Z, Chen W, Hu J, Huang X, He Z, et al. Transanal versus laparoscopic total mesorectal excision for mid and low rectal cancer: A meta-analysis of short-term outcomes. *Wideochir Inne Tech Maloinwazyjne*. 2019;14(3):353.
- Ma B, Gao P, Song Y, Zhang C, Zhang C, Wang L, et al. Transanal Total Mesorectal Excision (taTME) for rectal cancer: A systematic review and meta-analysis of oncological and perioperative outcomes compared with laparoscopic total mesorectal excision. *BMC Cancer*. 2016;16(1):380.
- Maslekar S, Sharma A, Macdonald A, Gunn J, Monson JRT, Hartley JE. Mesorectal grades predict recurrences after curative resection for rectal cancer. *Dis Colon Rectum*. 2007;50(2):168-75.
- Anthuber M, Fuerst A, Elser F, Berger R, Jauch KW. Outcome of laparoscopic surgery for rectal cancer in 101 patients. *Dis Colon Rectum*. 2003;46(8):1047-53.
- Hartley JE, Mehigan BJ, Qureshi AE, Duthie GS, Lee PW, Monson JR. Total mesorectal excision: Assessment of the laparoscopic approach. *Dis Colon Rectum*. 2001;44(3):315-21.

23. Morino M, Parini U, Giraudo G, Salval M, Contul RB, Garrone C. Laparoscopic total mesorectal excision: A consecutive series of 100 patients. *Ann Surg*. 2003;237(3):335-42.
24. Leroy J, Jamali F, Forbes L, Smith M, Rubino F, Mutter D, et al. Laparoscopic Total Mesorectal Excision (TME) for rectal cancer surgery: Long-term outcomes. *Surg Endosc*. 2004;18(2):281-9.
25. Orsenigo E, Di Palo S, Vignali A, Staudacher C. Laparoscopic intersphincteric resection for low rectal cancer. *Surg Oncol*. 2007;16:117-20.
26. Lim SW, Huh JW, Kim YJ, Kim HR. Laparoscopic intersphincteric resection for low rectal cancer. *World J Surg*. 2011;35(12):2811-7.
27. Hamada M, Matsumura T, Matsumoto T, Teraishi F, Ozaki K, Nakamura T, et al. Advantages of the laparoscopic approach for intersphincteric resection. *Surg Endosc*. 2011;25(5):1661-3.
28. Zhou Z, Zheng X, Song H, Jiang F, Wang Z, Zuo Z, et al. Laparoscopic total mesorectal excision combined with intersphincteric resection for ultra-low rectal cancer. *Zhonghua Wei Chang Wai Ke Za Zhi*. 2011;14(6):440-2.
29. Yoo BE, Cho JS, Shin JW, Lee DW, Kwak JM, Kim J, et al. Robotic versus laparoscopic intersphincteric resection for low rectal cancer: Comparison of the operative, oncological, and functional outcomes. *Ann Surg Oncol*. 2015;22(4):1219-25.