



SARS-CoV-2 Infection in an Adolescent after Haploidentical Stem Cell Transplantation

Massei MS¹, Capolsini I¹, Cerri C¹, Gurdo G¹, Mastrodicasa E¹, Perruccio K¹, Brogna M¹, Gorello P², Ruggeri L³, Rosignoli D³, Marchesi M⁴, Luciani Pasqua B⁴, Mencacci A³, Caniglia M¹ and Arcioni F^{1*}

¹Department of Pediatric Oncology-Hematology, Santa Maria della Misericordia Hospital, Italy

²Institute of Hematology and Center for Hemato-Oncology Research, University and Hospital of Perugia, Italy

³Department of Medicine, University of Perugia, Italy

⁴Department of Immunohematology, Santa Maria della Misericordia Hospital, Italy

Abstract

COVID-19 infection currently represents the global health emergency that all health professionals must face. In particular, many aspects remain to be clarified regarding morbidity and causes of mortality in the general population. Even more are the aspects to be clarified regarding the characteristics of this infection in the immunocompromised population. In particular, in patients undergoing bone marrow transplantation there are only sporadic observations about the course of the disease, this also because the transplanted patient observes the rules of social distancing unrelated to the pandemic, resulting consequently involved in rare cases by the infection. However, the degree of lethality of COVID-19 infection, in the rare observations available up to now, appears to be lower in the immunocompromised patient. In April 2020 the European Society for Blood and Marrow Transplantation (EBMT) therefore developed recommendations for transplant programs and physicians treating HSCT patients. We describe the case of a haploidentical bone marrow transplanted patient who contracted COVID-19 infection at day +110 from transplantation during immunosuppressive treatment for the presence of GvHD. The study and observation of these rare cases could help hematologists and transplantologists to better manage the infections that will continue to present themselves given the pandemic course, and could also help to better understand the mechanisms of morbidity of the virus to search for some physiopathological and therapeutic aspects that can be transferred to the general population.

Keywords: Stem cell transplantation; SARS-CoV-2 infection; Acute leukemia

Introduction

Patients that undergo Hematopoietic Stem Cell Transplantation (HSCT) are very susceptible to Respiratory Viral Infections (RVIs), most of which possibly fatal [1,2]. The current spread of the COVID-19 pandemic is a challenge for hematologist, although most of the cases in immunocompromised patients reported a mild course of the disease [3]. To date, there are very few reports on the clinical course and outcome of the coronavirus disease after HSCT, even less in pediatric patients [4-6].

We report a 14 years old male with T lymphoblastic leukemia, diagnosed in Perù, (white blood cells >500.000/mm³, no molecular and cytogenetics data available) who contracted SARS-CoV2 at day +110 from haploidentical HSCT.

After a complete remission obtained with AIEOP-BFM ALL 2009 protocol, during maintenance an early extramedullary (right optical neuritis) and medullary relapse occurred. After intensive chemotherapy and radiotherapy the patient obtained a second complete remission and received haplo-HSCT with regulatory and conventional T-cell adoptive immunotherapy (protocol ID 02/14 and as NCT03977103 in ClinicalTrials.gov) from maternal NK alloreactive donor [7,8] (conditioning regimen: Hyperfractionated TBI total dose 13.5 Gy, thiotepa 10 mg/Kg, fludarabine 160 mg/m², cyclophosphamide 30 mg/Kg and Rituximab 200 mg/m²). The megadose of T-depleted CD34+ cells (13 × 10⁶/kg) was preceded by the infusion of T regulatory cells (2 × 10⁶/kg) on day -4, and T conventional cells (0.5 × 10⁶/kg) on day -1. No GvHD pharmacological prophylaxis was administered (neutrophil engraftment +11, platelet engraftment +20). Chimerism was 100% donor, and CD3+/CD4+ lymphocyte count was 137/mm³, CD3+/CD8+ 1644/mm³, CD3-/CD56+ 521/mm³ at 30

OPEN ACCESS

*Correspondence:

Francesco Arcioni, Department of Pediatric Oncology-Hematology, Santa Maria della Misericordia Hospital, Perugia, Piazza Menghini 1, 06132, Italy, Tel: 0039755782202; Fax: 0039755782204; E-mail: Francesco.arcioni@ospedale.perugia.it

Received Date: 22 Feb 2021

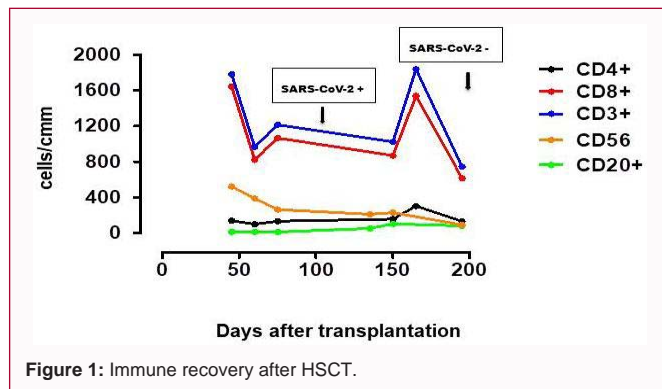
Accepted Date: 10 Mar 2021

Published Date: 16 Mar 2021

Citation:

Massei MS, Capolsini I, Cerri C, Gurdo G, Mastrodicasa E, Perruccio K, et al. SARS-CoV-2 Infection in an Adolescent after Haploidentical Stem Cell Transplantation. Clin Oncol. 2021; 6: 1787.

Copyright © 2021 Arcioni F. This is an open access article distributed under the Creative Commons Attribution License, which permits unrestricted use, distribution, and reproduction in any medium, provided the original work is properly cited.

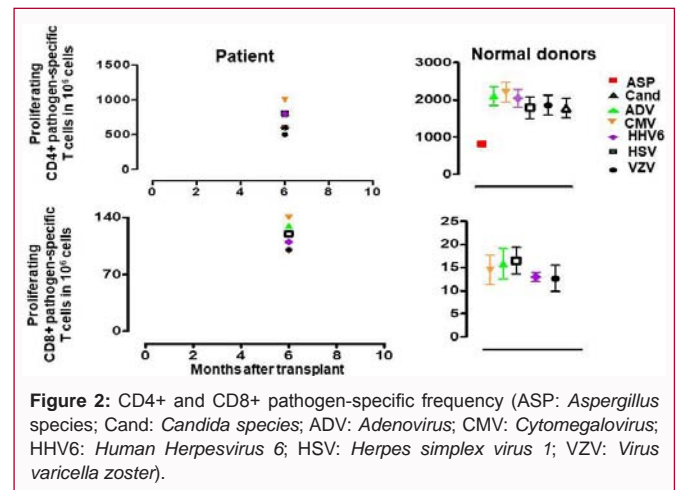


days from HSCT. At day +15 a grade 1 cutaneous and gastrointestinal acute GvHD occurred, treated with hydrocortisone 100 mg/day and extracorporeal photopheresis, then with beclomethasone dipropionate 10 mg/day and ruxolitinib 5 mg/bid with quick steroids tapering-off. At +120 cough, headache, nausea, epigastric pain, lack of appetite and weight loss occurred and emerged positivity for SARS-CoV-2 (by Real-Time RT-PCR on nasopharyngeal swab Cepheid E gene 13th cycle, N gene 16th cycle). At the admission in the Infectious Disease Department normal blood oxygen saturation and gas analysis were normal; the chest CT-scan showed multiple ground glass areas bilaterally. Remdesivir was started (200 mg loading dose on day 1, followed by 100 mg daily for 9 more days), 0.4 g/Kg of polyspecific intravenous human immunoglobulins and 3 convalescent-plasma infusions (200 ml with 1:300 titer neutralizing antibodies at day 1,3,4) were administered with interruption of the immunosuppressive therapy. The SARS-CoV-2 swabs was positive with high viral load, without the production of specific antibodies. A second CT scan showed improvement; patient didn't need any further support and at +160 was discharged with molecular SARS-CoV2 positivity; SARS-CoV-2 IgG (LIASON SARS-CoV-2 Diasorin test) were 20.1 AU/mL (positivity >15). More than two months after the first one, swab was still persistently positive (RT-PCR, S gene 21st cycle, N gene 22nd cycle), no symptoms of COVID-19 neither of GvHD were present. At +200, the chimerism was 100% donor, with a CD3+/CD4+ lymphocyte count of 302/mm³, CD3+/CD8+ 1537/mm³, CD3-/CD56+ 227/mm³ (Figure 1). Finally the patient has repeatedly tested negative for SARS-CoV-2 with strongly positive antibodies (78.6 AU/mL). The limiting dilution assay to evaluate pathogen-specific responses in CD4+ T and CD8+ T cells was performed and specific CD4+ and CD8+ lymphocytes against opportunistic pathogens such as HHV-6, *Aspergillus fumigatus*, *Candida albicans*, CMV, *Adenoviridae*, Herpes simplex virus, *Human herpesvirus 3* and *Toxoplasma* soon emerged (Figure 2) [7].

Discussion

A nationwide case series of 2,135 pediatric patients affected by COVID-19 showed that more than 90% of them had no severe disease [9]. Some studies conducted on children [10] and young immunocompromised patients corroborate the hypothesis that patients with lymphopenia have a less severe morbidity, because their lack of T lymphocytes may reduce the risk of acute respiratory distress syndrome and other hyper-inflammatory conditions. Furthermore, until now only a few cases of SARS-CoV-2 infection after HSCT were reported.

The role of the immune system in SARS-CoV-2 infection is still not completely clear and conflicting evidence exists on the connection



among virus replication, inflammatory response and tissue damage. Following the infection, SARS-CoV-2 binds to alveolar epithelial cells and activates innate and adaptive immune responses. CD4+ and CD8+ T cells act in balancing the adaptive immunity and the excessive inflammation [11,12]. Activation of CD8+ T cells is very important for the virus clearance from infected cells but it may also cause tissue immune injury [13]. Furthermore, activated CD4+ T cells become pathogenic T-helper 1 cells that generate proinflammatory cytokines and chemokines which cause the recruitment of lymphocytes and leukocytes to the site of infection and an immune response amplification can be created, up to the cytokine release syndrome [11,14].

Siddiqi and Mehra [15] hypothesize that there are 2 pathologic subsets; the first one triggered by the virus itself and the second by the host response. There would be 3 escalating phases of COVID-19 disease progression: Stage I (early infection), stage II (pulmonary phase) and stage III (hyperinflammation phase) with associated phase-specific signs, symptoms and therapies. Stage I suggests that this phase is similar in immunosuppressed and non-immunosuppressed patients, while stages II and III seem to be milder and less frequent in the immunosuppressed [15,16].

Conclusion

Our patient contracted SARS-CoV-2 four months after HSCT, while on anti-GvHD therapy and with a high viral load. Nevertheless he had a mild clinical course.

Immunological recovery after HSCT is crucial for infection control and, according to the immunodeficiency scoring index by Shah et al. [17], the patient could be grouped in the high-risk stratum, fulfilling the criteria of severe post-transplant immunodeficiency. The role of the immune response appears to be harmful rather than protective in the SARS-CoV-2 and it may differ from some other respiratory viruses. CD4+ T cells in this patient at the time of infection were low (137/mm³) due to the incomplete immunological reconstitution; so the immunosuppressive therapy may have played a protective role towards the COVID-19. The lymphocytopenia of the patient may have reduced the inflammatory response that could have caused more severe respiratory complications. This might suggest that the severity of COVID-19 could depend mainly on the organism immune response [18]. Furthermore, the patient was treated with ruxolitinib, which preclinical and clinical data suggest that can mitigate the severity of COVID-19 by reducing the JAK1/

JAK2 mediated cytokine storm. Ruxolitinib was suspended after the first positivity, but its effect is perhaps prolonged over time [19,20]. It should be emphasized that the patient was still positive after 70 days from the first positivity, even though asymptomatic. This suggests that the clinical severity of COVID-19 could be independent from SARS-CoV-2 viral load. The virus clearance was late, as well the production of specific antibodies, 72 days after the first positive nasopharyngeal swab, when the absolute count of CD19+ and CD20+ is 79/mmc and immunoglobulin blood levels are 315 mg/dL.

The actual CD3+/CD8+'s count (1537/mmc), without any sign of GvHD exacerbation, may suggest a late but specific T lymphocyte response to SARS-CoV2, in absence of COVID-19 disease.

Our report suggests that in case of SARS-CoV-2 infection contracted after a haploidentical-HSCT with T-regulatory and T-conventional cell adoptive immunotherapy, the immunocompromised condition may have acted as a protective factor against the COVID-19. This could corroborate the hypothesis that in case of SARS-CoV-2 infection, a major role in the development of severe cases of COVID-19 disease and its mortality might be played by the immune response.

Acknowledgment

The authors would like to thank Dr. Vesna Mićunović for English language editing of this paper.

References

- Pochon C, Voigt S. Respiratory virus infections in hematopoietic cell transplant recipients. *Front Microbiol.* 2019;9:3294.
- Abbas S, Raybould JE, Sastry S, De la Cruz O. Respiratory viruses in transplant recipients: More than just a cold. *Clinical syndromes and infection prevention principles.* *Int J Infect Dis.* 2017;62:86-93.
- Coronavirus disease (COVID-2019) situation reports.
- Ljungman P, Mikulska M, de la Camara R, Basak GW, Chabannon C, Corbacioglu S, et al. The challenge of COVID-19 and hematopoietic cell transplantation; EBMT recommendations for management of hematopoietic cell transplant recipients, their donors, and patients undergoing CAR T-cell therapy. *Bone Marrow Transplant.* 2020;55:2071-6.
- Fisler G, Haimed A, Levy CF, Stiles J, Capone CA, Fish JD, et al. Severe coronavirus disease 2019 infection in an adolescent patient after hematopoietic stem cell transplantation. *Chest.* 2020;158(4):e139-42.
- Jarmoliński T, Matkowska-Kocjan A, Rosa M, Olejnik I, Górczyńska E, Kałwak K, et al. SARS-CoV-2 viral clearance during bone marrow aplasia after allogeneic hematopoietic stem cell transplantation-a case report. *Pediatr Transplant.* 2020;18:e13875.
- Di Ianni M, Falzetti F, Carotti A, Terenzi A, Castellino F, Bonifacio E, et al. Tregs prevent GVHD and promote immune reconstitution in HLA-haploidentical transplantation. *Blood.* 2011;117(14):3921-8.
- Martelli MF, Di Ianni M, Ruggeri L, Falzetti F, Carotti A, Terenzi A, et al. HLA-haploidentical transplantation with regulatory and conventional T-cell adoptive immunotherapy prevents acute leukemia relapse. *Blood.* 2014;124(4):638-44.
- Centers for Disease Control and Prevention. Coronavirus Disease 2019 (COVID19) Infection Control Guidance.
- Wolf TFW, Attarbaschi A, Balduzzi A, Bernardo ME, Bomken S, Borkhardt A, et al. COVID-19 - Impact on Childhood Haematology Patients. *HemaSphere.* 2020;4(5):e465.
- Li G, Fan Y, Lai Y, Han T, Li Z, Zhou P, et al. Coronavirus infections and immune responses. *J Med Virol.* 2020;92(4):424-32.
- Cecere TE, Todd SM, Leroith T. Regulatory T cells in arterivirus and coronavirus infections: Do they protect against disease or enhance it? *Viruses.* 2012;4(5):833-46.
- Maloir Q, Ghysen K, von Frenckell C, Louis R, Guiot J. Acute respiratory distress revealing antisynthetase syndrome. *Rev Med Liege.* 2018;73(7-8):370-5.
- Yonggang Z, Binqing F, Xiaohu Z, Dongsheng W, Changcheng Z, Yingjie Q, et al. Pathogenic T cells and inflammatory monocytes incite inflammatory storm in severe COVID-19 patients. *Natl Sci Rev.* 2020;7(6)998-1002.
- Siddiqi HK, Mehra MR. COVID-19 illness in native and immunosuppressed states: A clinical-therapeutic staging proposal. *J Heart Lung Transplant.* 2020;39(5):405-7.
- Li F, Cai J, Dong N. First cases of COVID-19 in heart transplantation From China. *J Heart Lung Transplant.* 2020;39(5):496-7.
- Shah DP, Ghantaji SS, Ariza-Heredia EJ, Shah JN, El Taoum KK, Shah PK, et al. Immunodeficiency scoring index to predict poor outcomes in hematopoietic cell transplant recipients with RSV infections. *Blood.* 2014;123(21):3263-8.
- Melenotte C, Silvin A, Goubet AG, Lahmar I, Dubuisson A, Zumla A, et al. Immune responses during COVID-19 infection. *Oncoimmunology.* 2020;9(1):1807836.
- Yeleswaram S, Smith P, Burn T, Covington M, Juvekar A, Li Y, et al. Inhibition of cytokine signaling by ruxolitinib and implications for COVID-19 treatment. *Clin Immunol.* 2020;218:108517.
- Saraceni F, Scortechini I, Mancini G, Mariani M, Federici I, Gaetani M, et al. Severe COVID-19 in a patient with chronic graft-versus-host disease after hematopoietic stem cell transplant successfully treated with ruxolitinib. *Transpl Infect Dis.* 2021;23(1):e13401.