



# A Case of a Rare Pseudoaneurysm of the Proximal Part of the Facial Artery in a 54-Year-Old Man

Anna Majewska\*, Dorota Miętkiewska-Leszniowska and Małgorzata Wierzbicka

Department of Otolaryngology, Head and Neck Surgery, Poznan University of Medical Sciences, Poland

## Abstract

The report describes the case of a 54-year-old man who was treated for tongue cancer primarily with chemoradiotherapy. He was not consented for surgical treatment. He was known to have type II diabetes and arterial hypertension. Prior to his chemotherapy, a gastrostomy and tracheotomy were performed. Following these procedures, the healing process was notably prolonged. A further long-term consequence of chemoradiotherapy was the development of a massive phlegmon of the floor of the mouth, neck and chest. He also experienced extensive bleeding from the base of the tongue. Finally, the diagnosis of bleeding from the base of the tongue on the right side in the course of a facial artery pseudoaneurysm and radionecrosis in the base of the tongue, tonsil-glossal angle and lateral wall of the throat on the right side was made. Embolization of the aneurysm was performed resulting in termination of the bleeding. The article discusses the process of pseudoaneurysms formation, reasons for their occurrence, as well as methods of treatment.

**Keywords:** Pseudoaneurysm; Tongue cancer; Chemoradiotherapy; Phlegmon

## Introduction

Most aneurysms in the head and neck region occur intracranially [1]. A true aneurysm is a dilatation of an intact vessel wall, consisting of all three layers: Inner, middle, and outer. The pseudoaneurysm does not have these three layers in histological examination [2]. Pseudoaneurysms of the head and neck, including those of the facial artery, are rare. Most branches of the external carotid artery are protected by soft tissue; however, they are located superficially in certain regions and therefore more prone to damage. The most susceptible to injury are the branches of the superficial temporal, maxillary, and distal part of the facial artery. Approximately 85% of pseudoaneurysms (of traumatic etiology) occur within the superficial temporal artery [3]. Very few cases of pseudoaneurysms of the proximal part of the facial artery are reported in the literature [2]. Pseudoaneurysms are formed as a result of damage to the arterial wall. Blood escapes through the injured vessel wall to the surrounding tissues until the average arterial pressure and pressure in the pseudoaneurysm equalizes [4,5]. The aneurysm communicates directly with the vessel's lumen. Due to the arterial pressure, it may constantly expand until it finally ruptures. This growth may be prolonged for weeks or years [6]. The most frequent causes of damage to the integrity of the facial artery wall are trauma and surgery. Surgical intervention on the mandibular branch has been associated with the formation of such pseudoaneurysms [1,4,7]. Cases of infectious etiology have also been described, as once they were the most common cause of this condition [1,8,9]. Radiotherapy, malnutrition or neoplastic infiltrations are other factors predisposing to pseudoaneurysm development [2]. Moreover, a case of a facial artery pseudoaneurysm was attributed to a metallic foreign object penetrating the vessel wall [10]. These lesions are most often asymptomatic, but the following manifestations may occur: The appearance of pulsating mass, head and neck pain, local nerve pressure, or rupture of the vessel causing sudden massive bleeding [1]. Diagnosis is usually achieved using Computed Tomography (CT). Ultrasonography can be used for superficially localized lesions. Using ultrasound as a screening test is suggested. Considering that it is easy to perform and reduces exposure to radiation [11,12]. Nevertheless, angiography is frequently considered an essential tool to confirm diagnosis [2]. The preferred method of treatment is embolization, which is the least invasive, most selective, and is favorable in locations with difficult surgical access [4,6]. However, endovascular treatment carries the risk of complications such as: local inflammation, bleeding, skin and soft tissue necrosis, neurological and ophthalmic damage. Other risks include facial nerve paralysis; pulmonary embolism, thrombosis, and aneurysm rupture [3]. Surgical intervention is beneficial in treating easily accessible, superficial lesions, or when exposure to radiation must be reduced [4]. It is also possible to ligate the vessel with or without resection.

## OPEN ACCESS

### \*Correspondence:

Anna Majewska, Department of Otolaryngology, Head and Neck Surgery, Poznan University of Medical Sciences, Poland,  
E-mail: [ania.majewska2@gmail.com](mailto:ania.majewska2@gmail.com)

Received Date: 14 Jan 2021

Accepted Date: 05 Feb 2021

Published Date: 11 Feb 2021

### Citation:

Majewska A, Miętkiewska-Leszniowska D, Wierzbicka M. A Case of a Rare Pseudoaneurysm of the Proximal Part of the Facial Artery in a 54-Year-Old Man. *Clin Oncol.* 2021; 6: 1771.

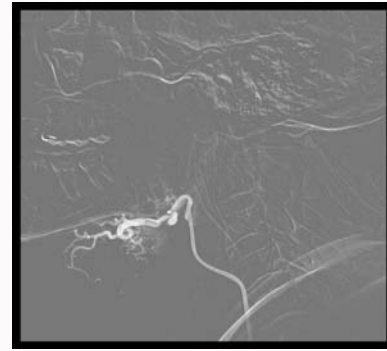
Copyright © 2021 Anna Majewska.

This is an open access article distributed under the Creative Commons Attribution License, which permits unrestricted use, distribution, and reproduction in any medium, provided the original work is properly cited.

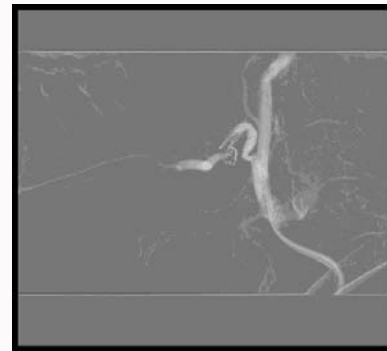
Complications after surgical treatment may include: Damage to the facial nerve branches, excessive bleeding, infection, or scar formation [3]. Other methods of treatment include progressive compression of the pseudoaneurysm under ultrasound control until its closure, or injection of thrombin into the lesion [2,11].

## Case Presentation

A 53-year-old patient first visited the ENT clinic in December 2018. At that time, he had been suffering from increasing pain in the right side of the tongue for 3 weeks, associated with difficulties in swallowing. The past medical history of the patient included hypertension and type 2 diabetes mellitus. On examination a hard infiltration on the ventral surface of the tongue on the right side was found. The lesion was biopsied. Histopathologic examination showed no evidence of neoplastic infiltration. Computed Tomography (CT) showed the presence of a mass measuring 39 mm × 18 mm × 29 mm in the right half of the body of the tongue; with infiltration of the hyoglossus and mylohyoid muscle. Due to the suspicion of malignancy, in January 2019, further biopsies were obtained and the diagnosis of squamous cell carcinoma was confirmed. A repeat CT showed progression of the tumor. The patient was counseled about the need for a total glossectomy with reconstruction of the free flap. The patient did not consent to the recommended treatment, therefore a course of primary chemoradiotherapy was proposed. Prior to these therapies, in February 2019, the patient had both a Percutaneous Endoscopic Gastrostomy (PEG) and a lower tracheotomy performed. The postoperative period was complicated by the inflammation, for which he received antibiotic therapy. After completing chemoradiotherapy, during a routine visit in May 2019, there was no evidence of relapse. However, in June 2019, an asymmetry of the tongue was noted. In August 2019, halitosis and a purulent discharge from the right tonsil-glossal angle were observed. The patient was hospitalized and underwent a biopsy in September 2019. No neoplastic lesions were found. At the end of September, inflammatory swelling of his neck recurred, which failed to respond to antibiotic therapy. In October, the patient required hospitalization due to a phlegmon of the floor of the mouth, neck, and chest. On CT the tonsil-glossal angle on the right side appeared the likely source. During the patient's hospitalization, the phlegmon was drained, a Vacuum Assisted Closure (VAC) system was applied, and a total of 4 units of packed red blood cells were transfused. In the postoperative period the patient suffered from ileus, however he responded well to conservative management. The general condition of the patient improved, his wounds were healing, and therefore he was discharged. In November 2019, during routine clinic appointments, adequate healing was observed, with no purulent discharge noted. On the morning of November 24<sup>th</sup>, 2019, the patient presented to the Emergency Room (ER) complaining of bleeding from the nose and oral cavity and nose. This subsided after treatment in Emergency Room (ER). The same day, following a PEG feed he experienced sudden onset hematemesis, in addition to fainting. A gastroscopy was performed in the ER, during which a potential bleeding spot was located in the region of the right base of the tongue. A repeat CT was requested on November 26<sup>th</sup>, 2019 which showed no local relapse. On the night of November 29<sup>th</sup>, 2019, there was further bleeding from the tonsil-glossal angle on the right side. The oropharynx and hypopharynx were tamponaded with an antibiotic-soaked rolled bandage. Around 4 AM, there was renewed bleeding from the oral cavity/pharynx - the tamponade was changed. Around 6.30 AM, a nasal tamponade was applied due to nasal bleeding. Four units of packed red blood cells were transfused. On the



**Figure 1:** A pseudoaneurysm of the initial section of the facial artery before embolization.



**Figure 2:** A pseudoaneurysm of the initial section of the facial artery after embolization.

morning December 1<sup>st</sup>, 2019, the oral cavity tamponade was removed. Around 4 AM on December 2<sup>nd</sup>, 2019, a further massive bleed from the oral cavity was witnessed. It was managed by using four rolled bandages to tamponade the oral cavity. Around 6.20 AM, the oral cavity tamponade was soaked in blood and bleeding from both nasal cavities was observed. Another nasal tamponade was applied resulting in the bleeding stopping. Around 7 PM an angiography of the right common carotid artery and the right external carotid artery was performed, which showed the presence of a pseudoaneurysm of the initial part of right facial artery. Subsequently, two coils were used to embolize the facial artery. The procedure was successful and went without complications. On December 4<sup>th</sup>, 2019, the tamponade was removed. No further bleeding was observed whilst he remained an inpatient. The patient was deemed fit for discharge. During the regular check-ups at the outpatient clinic after hospitalization, healing was satisfactory and following embolization, there was no re-bleeding. In June 2020 the tracheotomy was removed (Figure 1 and 2).

## Conclusion

The main vascularization of the tongue comes from the lingual artery, a branch of the external carotid artery. It is also supplied by small branches from the facial and ascending pharyngeal artery, which was particularly significant in this case. In this case there was no prior trauma or surgery to attribute the formation of the pseudoaneurysm to. Previous chemotherapy or massive neck and thoracic phlegmon were the likely causes of this pseudoaneurysm. The radiation may have weakened the wall of the vessel causing inflammation. Radiotherapy affects all vessels, both small and large, within the treatment site. It most often leads to the occlusion of blood vessels, but can also cause

endothelial degeneration, vacuolization, and thickening of intima associated with modifications in elastic fibers. Radiation-related vascular changes can occur throughout the period ranging from 4 months to 23 years after treatment [8,13]. Pseudoaneurysms resulting from the injury may become symptomatic after many months or years [14]. In this particular case, bleeding appeared about six months after the completion of radiotherapy, and about one month after extensive neck and thoracic phlegmon. The damage to the arterial wall resulting in a pseudoaneurysm formation was likely caused by both radiotherapy and inflammation.

## References

1. Al-Saadi NJ, Bakathir A, Al-Mashaikhi A, Al-Hashmi A, Al-Habsi A, Al-Azri F. Maxillary artery pseudoaneurysm as a complication of maxillofacial injuries: Report of three cases and literature review. *Sultan Qaboos Univ Med J*. 2019;19(4):e364-8.
2. Shetty NK, Shandilya R, Pawar S, Gadre PK, Gadre K, Singh D. Management of late post-traumatic facial artery pseudoaneurysmal cyst: Review of literature. *J Maxillofac Oral Sur*. 2015;14(2):201-5.
3. Payami A, Montazem AH. Surgical treatment of facial artery pseudoaneurysm following blunt trauma: Report of a Case. *J Oral Maxillofac Surg*. 2017;75(2):362.e1-362.e5.
4. Dudaryk R, Horn DB, Green JM. Facial artery pseudoaneurysm: Challenges of airway management. *Anesth Prog*. 2018;65(1):52-5.
5. Juszkat R, Korytowska A, Łukomska Z, Zarzecka A. Facial artery pseudoaneurysm and severe bleeding after tonsillectomy - endovascular treatment with PVA particle embolization. *Pol J Radiol*. 2010;75(1):88-91.
6. Jo HW, Kim YS, Kang DH, Lee SH, Kwon TG. Pseudoaneurysm of the facial artery occurred after mandibular sagittal split ramus osteotomy. *Oral Maxillofac Surg*. 2013;17(2):151-4.
7. de Lima Neto TJ, de Albuquerque Maranhão CA, de Oliveira Neto PJ. Pseudoaneurysm of facial artery after orthognathic surgery. *J Craniofac Surg*. 2019;30(7):e607-9.
8. Kamath G, Naalla R, Pai VB, Narayanan R. Left maxillary artery pseudoaneurysm: A rare and late postoperative complication after head and neck cancer treatment. *Case Reports*. 2014;2014:bcr2013203078.
9. Dunn GP, Uppaluri R, Hessler JL, Layland MK, Derdeyn CP, Sunwoo JB. Mycotic pseudoaneurysm of the internal maxillary artery: Case report and review of the literature. *Arch Otolaryngol Head Neck Surg*. 2007;133(4):402-6.
10. Cohen MA. False (traumatic) aneurysm of the facial artery caused by a foreign body. *Int J Oral Maxillofac Surg*. 1986;15(3):336-8.
11. Abulfaraj MM, Deanehan JK. Facial artery pseudoaneurysm in a child diagnosed with point of care ultrasound. *Pediatr Emerg Care*. 2019;35(10):733-5.
12. Partridge E, Zwirewich CV, Salvian AJ. Facial artery pseudoaneurysm: Diagnosis by colour Doppler ultrasonography. *Can Assoc Radiol J*. 1995;46(6):458-60.
13. Yucesoy K, Feiz-Erfan I, Spetzler RF, Han PP, Coons S. Anterior communicating artery aneurysm following radiation therapy for optic glioma: Report of a case and review of the literature. *Skull Base*. 2004;14(3):169-73.
14. Germiller JA, Myers LL, Harris MO, Bradford CR. Pseudoaneurysm of the proximal facial artery presenting as oropharyngeal hemorrhage. *Head Neck*. 2001;23(3):259-63.