



# Targeted Therapy's Skin Toxicities after Immunotherapy: Skin Toxicity of Tyrosine Kinase Inhibitor Therapy Following Nivolumab Therapy for Metastatic Renal Cell Carcinoma

Benjamin Verret<sup>1</sup>, Cécile Badoual<sup>1,2</sup>, Pierre Combe<sup>1,2</sup>, Agnes Carlotti<sup>1,2</sup> and Stephane Oudard<sup>1,2\*</sup>

<sup>1</sup>Hôpital Européen Georges Pompidou, France

<sup>2</sup>Université Paris Descartes, Paris

## Abstract

Anti-programmed cell death antibodies (anti-PD-1) are currently under development for the treatment of metastatic renal cell carcinoma (mRCC) and safety of subsequent treatment by VEGFR tyrosine kinase inhibitors (TKI) is not known. We report two cases of unexpectedly severe skin rashes occurring on initiation of treatment by the tyrosine kinase inhibitor (TKI) sorafenib after prior treatment with the anti-PD-1 nivolumab. Attention is drawn to the potential skin toxicity of TKI treatment after anti-PD-1 administration.

**Keywords:** Immunotherapy; Anti-PD1; Nivolumab; Sorafenib; Renal cell carcinoma; Skin rashes; Drugs sequence

## Abbreviations

Anti-PD-1: Anti-programmed Cell Death Antibodies; mRCC: Metastatic Renal Cell Carcinoma; TKI: Tyrosine Kinase Inhibitor; VEGFR: Vascular Endothelial Growth Factor Receptor; PDGFR: Platelet-derived Growth Factor Receptor; PFS: Progression-free Survival; OS: Overall Survival; mTOR: Mammalian Target of Rapamycin

## OPEN ACCESS

### \*Correspondence:

Stéphane Oudard, Service d'oncologie médicale, Hôpital Européen Georges Pompidou 20 rue Leblanc, 75015 Paris, France,

E-mail: [Stephane.oudard@aphp.fr](mailto:Stephane.oudard@aphp.fr)

**Received Date:** 15 Aug 2016

**Accepted Date:** 25 Sep 2016

**Published Date:** 01 Dec 2016

### Citation:

Verret B, Badoual C, Combe P, Carlotti A, Oudard S. Targeted Therapy's Skin Toxicities after Immunotherapy: Skin Toxicity of Tyrosine Kinase Inhibitor Therapy Following Nivolumab Therapy for Metastatic Renal Cell Carcinoma. *Clin Oncol.* 2016; 1: 1153.

**Copyright** © 2016 Oudard S. This is an open access article distributed under the Creative Commons Attribution License, which permits unrestricted use, distribution, and reproduction in any medium, provided the original work is properly cited.

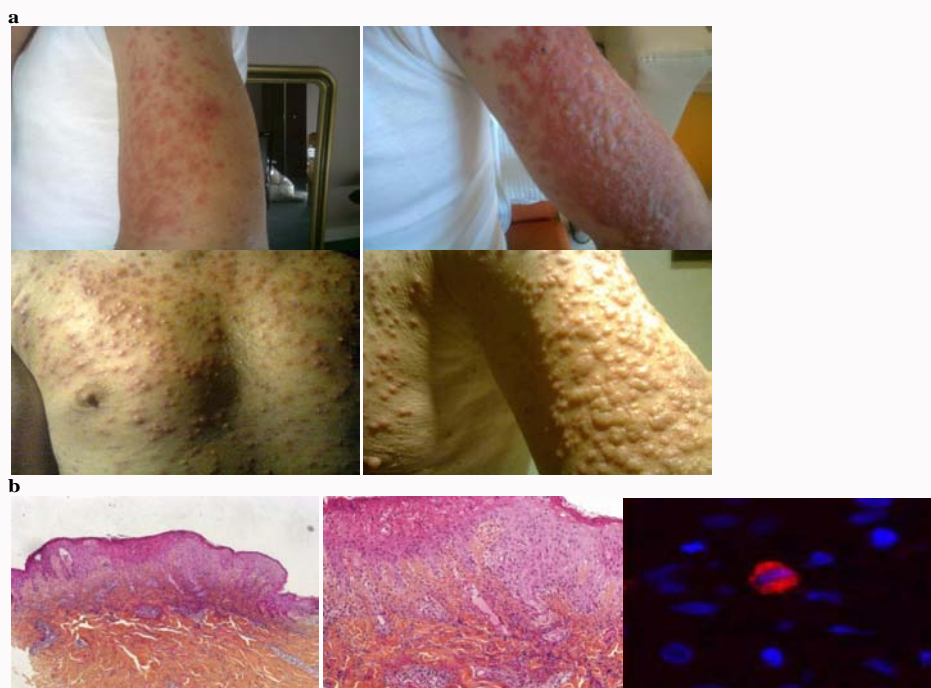
## Introduction

The customary first-line treatment of mRCC in 70% of cases is the TKI sunitinib, an inhibitor of vascular endothelial growth factor receptor (VEGFR) and platelet-derived growth factor receptor (PDGFR), which has been shown to significantly improve progression-free survival (PFS) and overall survival (OS) [1,2]. Second line therapies in advanced RCC generally are associated with diminished probability and duration of response compared to first-line interventions. For this reason, there are substantial clinical research efforts to find more effective therapies including immunotherapies, which can be associated with longer duration of responses compared to extant targeted therapies. The drugs in most common second-line use are the TKI sorafenib, an orally active multikinase inhibitor, which has shown improved PFS and OS after cytokine-based treatment [3], the TKI axitinib [4], and inhibitors of the mammalian target of rapamycin (mTOR) such as everolimus [5]. Anti-programmed cell death antibodies (anti-PD-1) are currently under development for the treatment of metastatic renal cell carcinoma (mRCC) and safety of subsequent treatment by VEGFR tyrosine kinase inhibitors (TKI) is not known. We report two cases of unexpectedly severe skin rashes occurring on initiation of treatment by the tyrosine kinase inhibitor (TKI) sorafenib after prior treatment with the anti-PD-1 nivolumab.

## Cases Presentation

### Case 1

A 63-year old man who presented with back pain and hematuria was diagnosed with Fuhrman Grade III clear-cell RCC and lung metastases. He received the TKI sunitinib (50 mg/day for 4 weeks/6) until radiographic progression at 1 year followed by the anti-PD1 drug nivolumab (3 mg/kg solution intravenously every 2 weeks) (BMS CA209-025 trial) [6] until documented disease progression at 5 months. The third-line drug was the TKI sorafenib. After just one week of sorafenib therapy, however, the patient was admitted to intensive care for a grade 4 skin rash (Figure 1a and



**Figure 1:** Case 1: Skin toxicity on sorafenib initiation after nivolumab treatment. (a) Grade 4 erythematous skin rash at Day 7 on arms and chest, (b) Skin biopsy showing epidermal necrolysis and lymphocytic infiltration of the skin. Presence of rare regulating FOXP3 positive cells situated under the malpighian epithelium.

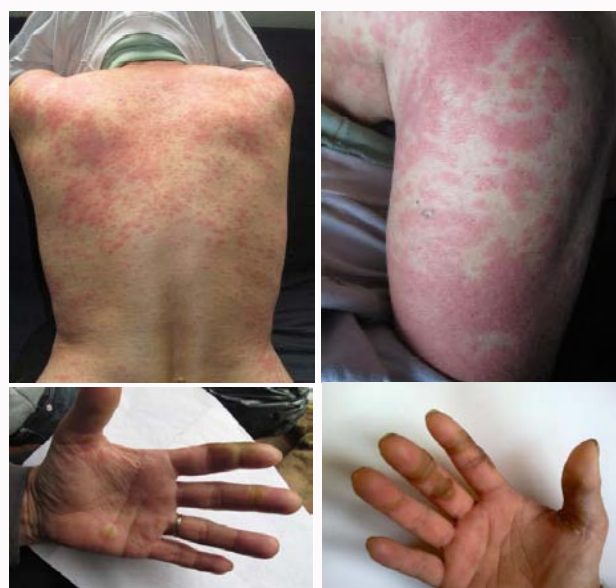b). Cyclosporin was initiated for suspected toxic epidermal necrolysis. Polymerase chain reaction tests for cytomegalovirus (CMV), Epstein-Barr virus (EBV), herpes virus HHV6 and parvovirus B19, as well as serology tests for human immunodeficiency virus (HIV) and syphilis, were negative. A skin biopsy confirmed epidermal necrolysis and lymphocytic infiltration of the skin with rare FOXP3 positive cells under the malpighian epithelium (Figure 1b). Severe toxidermitis was diagnosed. The patient was discharged from hospital after 7 days. Two months later, treatment by everolimus was initiated without inducing any severe side-effects.

### Case 2

A 60-year old woman with clear-cell RCC and pancreatic metastases received first-line TKI therapy (sunitinib, 50 mg/day 4 weeks/6) for 30 months until radiographic progression, followed by second-line nivolumab (8 infusions of 3 mg/kg every 2 weeks) until progression at 3 months (BMS CA209-025 trial), followed by third-line tasquinimod which had, however, to be discontinued after 5 months because of lung toxicity (dyspnea). Sorafenib treatment was initiated but, after just 2 weeks, the patient experienced a grade 4 skin rash and grade 3 hand-foot syndrome (Figure 2). After a 6-month respite period, treatment was switched to cabozantinib with no severe adverse effects (METEOR XL184-308 trial) [7].

### Discussion

The recently developed anti-PD-1 nivolumab (BMS-936558) increases survival and helps to reverse the exhausted phenotype of T cells expressing PD-1 and has shown promise as second- or higher-line therapy in patients with advanced non-small-cell lung cancer, melanoma and RCC [8]. PD-1 is a key immune checkpoint receptor that is expressed by activated T-cells and mediates immunosuppression. It functions mainly in peripheral tissues when T-cells encounter immunosuppressive PD-1 ligands (PD-L1 (B7-H1) and PD-L2 (B7-DC)) expressed by tumor and/or stromal cells. In



**Figure 2:** Case 2 : Skin toxicity on sorafenib initiation after nivolumab treatment with skin rash and "hand and foot syndrome".

experimental studies, inhibition of the interaction between PD-1 and PD-L1 enhanced T-cell responses and mediated antitumor activity [9]. The hand-foot skin reaction associated with the TKI sorafenib is well known. The reported occurrence of skin rash of any grade is about 40%; with very few cases of grade 3-4 rashes [3]. Grade 4 rashes resulting in toxic epidermal necrolysis and admission to intensive care are extremely rare with sorafenib. According to a phase 1 trial of 296 patients, nivolumab has acceptable short-term safety. The most common adverse events were fatigue, decreased appetite, diarrhea, nausea, cough, dyspnea, constipation, vomiting, rash, pyrexia, and headache, with 3 drug-related deaths from grade 5 pneumonitis [8].

**Table 1:** Cases of severe skin toxicity on initiation of TKI treatment after progression on anti-PD-1 treatment.

Patient (age)	Type of cancer	Anti-PD-1		Interval anti-PD-1 to TKI (months)	Time from TKI initiation to skin rash (days)
		Drug	Duration (months)		
Male (63 yr)	mRCC	Nivolumab	5	1	7
Female (60 yr)	mRCC	Nivolumab	5	5	14

Data on its long-term use in the wake of a TKI are, however, scarce. In a multicenter retrospective study of VEGFR-TKI administration after PD1/PD-L1 inhibition in 43 patients with mRCC, the median time to treatment failure was 6.9 months, with no notable toxicity [10]. However, this study concerned a small size of patient and some rare adverse events might not be detected.

Neither of our patients had a history of autoimmune or of skin disease that might have been omened skin toxicity, suggesting that nivolumab may have contributed toward the onset of the skin toxicity observed on initiation of sorafenib therapy. As the interval between nivolumab and sorafenib therapy was 3 weeks or longer, it would seem that the skin toxicity was due to exacerbation by immune sensitization rather than cumulative toxicity (Table 1). The rapid onset of the skin toxicity also suggested that the cause was immunological. We found rare FOXP3 positive cells under the malpighian epithelium, FOXP3 is a key regulatory gene for the action of T cells [11] and it is one more argument for an immune mechanism. The exact pathogenesis remains unknown, but we can hypothesize that nivolumab enhance T-cell responses against tumor cell but also some unspecific T-cell responses that can improved immune adverse event and so skin toxicity of sorafenib. This hypothesis means that this rash was not caused by a specific T-cell reaction against sorafenib but by an unspecific immune response triggered by TKI due to prior use of anti-PD-1.

The rationale of anti-PD-1 therapy is to enhance T-cell responses to tumor cells but we hypothesize that such therapy might also trigger unwanted immune responses such as skin toxicity worsening. Our case reports pinpoint the need to further examine which drug sequences are most appropriate in patients with mRCC. Consent to publish: Consent was obtained from patients and their family.

## Acknowledgement

We acknowledge ARTIC (Association pour la recherche de thérapies innovantes en cancérologie) for supporting this work.

## References

- Motzer RJ, Hutson TE, Tomczak P, Michaelson MD, Bukowski RM, Rixe O, et al. Sunitinib versus interferon alfa in metastatic renal-cell carcinoma. *N Engl J Med.* 2007; 356: 115–124.
- Heng DYC, Wells JC, Rini BI, Beuselinck B, Lee J-L, Knox JJ, et al. Cytoreductive nephrectomy in patients with synchronous metastases from renal cell carcinoma: results from the International Metastatic Renal Cell Carcinoma Database Consortium. *Eur Urol.* oct 2014; 66: 704-710.
- Escudier B, Eisen T, Stadler WM, Szczylik C, Oudard S, Siebels M, et al. Sorafenib in advanced clear-cell renal-cell carcinoma. *N Engl J Med.* 2007; 356: 125–134.
- Rini BI, Escudier B, Tomczak P, Kaprin A, Szczylik C, Hutson TE, et al. Comparative effectiveness of axitinib versus sorafenib in advanced renal cell carcinoma (AXIS): a randomised phase 3 trial. *Lancet Lond Engl.* 3 déc 2011; 378:1931-1939.
- Motzer RJ, Escudier B, Oudard S, Hutson TE, Porta C, Bracarda S, et al. Phase 3 trial of everolimus for metastatic renal cell carcinoma : final results and analysis of prognostic factors. *Cancer.* 15 sept 2010;116: 4256-4265.
- <http://clinicaltrials.gov/show/NCT01668784>.
- <http://clinicaltrials.gov/show/NCT01865747>.
- Topalian SL, Hodi FS, Brahmer JR, Gettinger SN, Smith DC, McDermott DF, et al. Safety, activity, and immune correlates of anti-PD-1 antibody in cancer. *N Engl J Med.* 2012; 366: 2443–2454.
- Topalian SL, Hodi FS, Brahmer JR, Gettinger SN, Smith DC, McDermott DF. Targeting the PD-1/B7-H1(PD-L1) pathway to activate anti-tumor immunity. *Curr Opin Immunol Avr* 2012; 24: 207-212.
- Albiges L, Fay AP, Xie W, Krajewski K, McDermott DF, Heng DYC, et al. Efficacy of targeted therapies after PD-1/PD-L1 blockade in metastatic renal cell carcinoma. *Eur J Cancer Oxf Engl* 1990. nov 2015; 51: 2580-2586.
- Hori S, Nomura T, Sakaguchi S. Control of regulatory T cell development by the transcription factor Foxp3. *Science.* 14 févr 2003; 299: 1057 - 1061.