



Treatment for Acute Cholecystitis after Metal Stent Placement in Patient with Malignant Biliary Obstruction using Double Bare Metal Stent

Takeshi Ogura*, Atsushi Okuda, Akira Miyano, Nobu Nishioka, Kazuhide Higuchi

Department of Internal Medicine, Osaka Medical College, Japan

Abstract

Endoscopic stent placement using Fully Covered Self-Expandable Metal Stent (FCSEMS) is gold standard method of treating for malignant biliary obstruction. However, if cystic duct is not occluded by malignant tumor, when FCSEMS was placed across cystic duct, acute cholecystitis may occur. In this condition, uncovered self-expandable metal stent (UCSEMS) or plastic stent may be selected as alternative drainage stent, however, stent patency is shorter than FCMS placement. Recently, novel UCSEMS is available (Double bare metal stent). This stent may have clinical impact for long stent patency compared with UCSEMS because preventing tumor in growth may be obtained, and prevent cholecystitis compared with FCSEMS because cystic duct is not occluded. Herein, we reported successful treatment for acute cholecystitis after FCSEMS placement using this double layer metal stent. Double bare metal stent may be effective to prevent acute cholecystitis after stent placement.

Keywords: ERCP; Double Bare Metal Stent; Metal Stent; Biliary

Introduction

Endoscopic stent placement using Fully Covered Self-Expandable Metal Stent (FCSEMS) is gold standard method of treating for malignant biliary obstruction [1]. However, if cystic duct is not occluded by malignant tumor, when FCSEMS was placed across cystic duct, acute cholecystitis may occur [2,3]. In this condition, Uncovered Self-Expandable Metal Stent (UCSEMS) or plastic stent may be selected as alternative drainage stent, however, stent patency is shorter than FCMS placement. Recently, novel UCSEMS is available (Double bare metal stent, EGIS Biliary Stent; S&G Biotech Inc. Korea) (Figure 1). This stent may have clinical impact for long stent patency compared with UCSEMS because preventing tumor in growth may be obtained, and prevent cholecystitis compared with FCSEMS because cystic duct is not occluded. Herein, we reported successful treatment for acute cholecystitis after FCSEMS placement using this double layer metal stent.

Case Report

A76-year-old man was admitted to our hospital because of obstructive jaundice due to unresectable pancreatic carcinoma. FCSEMS (10mm × 6cm, BONASTENT; Standard Sci-Tech Inc, Seoul, South Korea) placement was attempted. However, after 2 days, abdominal pain and fever up were seen. Computed Tomography (CT) showed acute cholecystitis (Figure 2). Because of cystic duct was not occluded by pancreatic carcinoma according to pre-operative CT, therefore, Stent exchange from FCSEMS to double bare metal stent was attempted. Firstly, duodenoscope (JF 260V, Olympus Optical, Tokyo, Japan) was inserted into the ampulla of Vater. Then, FCSEMS removal was attempted using snare basket catheter, and successfully performed. Next, we inserted Endoscopic Retrograde Cholangiopancreatography (ERCP) (MTW, Endoscopy, Dusseldorf, Germany) cannula and the 0.025 inch guidewire (VisiGlide 1; Olympus Medical Systems, Tokyo, Japan). Next, we injected the contrast medium. According to cholangiography, cystic duct was patency, and biliary obstruction was seen in lower bile duct (Figure 3). We inserted double layer metal stent delivery system (Figure 4), and successfully performed stent placement (Figure 5). This patient underwent chemotherapy, and stent dysfunction was not encountered until he died one year later.

Discussion

Stent placement under ERCP guidance is the gold standard technique to treat malignant biliary

OPEN ACCESS

*Correspondence:

Takeshi Ogura, Department of Internal Medicine, Osaka Medical College, Japan, Tel: 81-527626111; Fax: +81-527635233;

E-mail: oguratakeshi0411@yahoo.co.jp

Received Date: 06 Feb 2018

Accepted Date: 03 Mar 2018

Published Date: 13 Mar 2018

Citation:

Ogura T, Okuda A, Miyano A, Nishioka N, Higuchi K. Treatment for Acute Cholecystitis after Metal Stent Placement in Patient with Malignant Biliary Obstruction using Double Bare Metal Stent. Clin Oncol. 2018; 3: 1435.

Copyright © 2018 Takeshi Ogura. This is an open access article distributed under the Creative Commons Attribution License, which permits unrestricted use, distribution, and reproduction in any medium, provided the original work is properly cited.



Figure 1: Double bare metal stent (10mm×6cm, EGIS Biliary Stent; S&G Biotech Inc. Korea); Century Medical Inc., Tokyo, Japan).

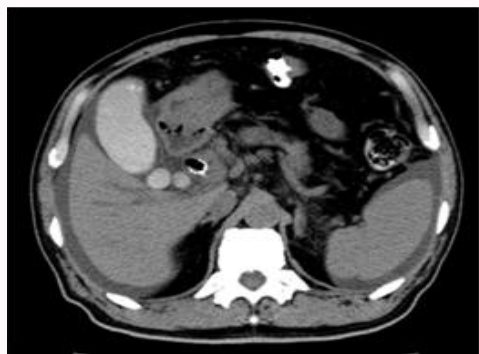


Figure 2: The gallbladder was swelling and contrast medium was presence.

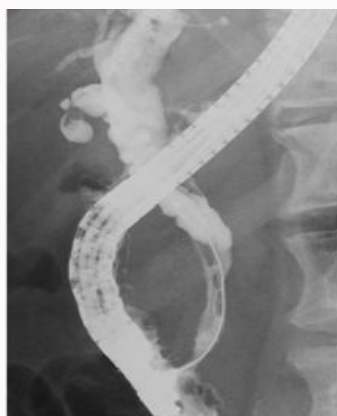


Figure 3: Endoscopic retrograde cholangiography showed stenosis of lower biliary duct and cystic duct was not occluded.

obstruction. For patients having advanced malignant tumor, metal stent placement may be preferred compared with plastic stent because stent patency may be longer. Kitano et al [4] conducted comparison study between FCSEMS and UCSEMS placement for patients complicated with distal malignant biliary obstruction. According to this study, stent patency was significantly longer in FCSEMS than in the UCSEMS (mean±s.d.: 291.3±159.1 vs 166.9±124.9 days; $P=0.047$). Therefore, FCSEMS may be more suitable for patients with advanced malignant tumor. However, FCSEMS has also several disadvantages such as stent migration or cystic duct obstruction due to metal stent of covered site. Ho et al [5] reported of complications of Partially Covered Self-Expandable Metal Stent (PCSEMS). In this study, total 396 patients were included, and stent migration was seen in 9 cases (2.3%). In addition, acute cholecystitis was also seen in 13 patients (3.3%). Park et al [6] retrospectively reviewed 98 consecutive patients who underwent FCSEMS placement and 108 consecutive patients who underwent UCSEMS placement. According to this study, although there were not significant differences, acute cholecystitis was frequently occurred in 5 patients (6.1%) compared with UCSEMS

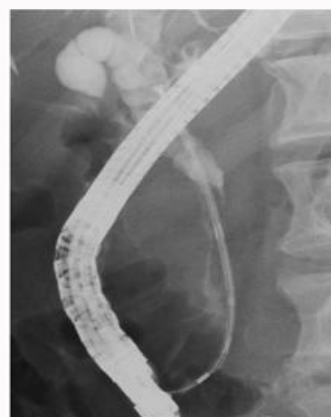

Figure 4: We inserted 8Fr delivery system into the common bile duct.

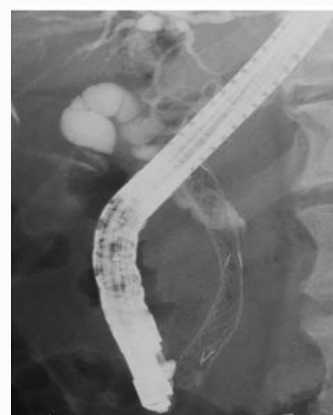

Figure 5: We successfully performed double layer metallic stent placement.

(1/100, 1%) ($P=0.104$). In addition, stent migration was seen in only FCSEMS group (6.1% vs 0%, $P=0.011$).

To overcome these matters, novel double bare metal stent has been emerged. This UCSEMS is made of braided nitinol with weaving into a cross and hook structure. Compared single UCSEMS, this stent has a unique double-layered structure to improve conformability and maintain the radial force and flexibility created by crossing two stents. As result, diameter cell size is small (1-1.5, 2mm at each end) [7]. This stent may be effective to prevent tumor in growth through the mesh compared with conventional UCSEMS. Indeed, Lee et al compared stent patency between double bare metal stent and UCSEMS [7]. In this study, although rate of adverse events were not significantly differences, mean stent patency of double bare metal stent was significantly longer than of UCSEMS (212 days vs 124 days, $P=0.022$). Although comparison study between FCSEMS and double bare metal stent is needed, this stent may have possibility of first-line stent according to preventing stent migration and obtaining long stent patency. In addition, double bare metal stent may be effective to prevent acute cholecystitis after stent placement.

Author Contribution

Takeshi Ogura wrote a paper. Takeshi Ogura, Atsushi Okuda, Akira Miyano, Nobu Nishioka, and Kazuhide Higuchi played roles of interpretation of data for the work, revising it critically for important intellectual content, final approval of the version to be published, agreement to be accountable for all aspects of the work in ensuring that questions related to the accuracy or integrity of any part of the

work are appropriately investigated and resolved.

References

1. Isayama H, Komatsu Y, Tsujino T, Sasahira N, Hirano K, Toda N, et al. A prospective randomised study of “covered” versus “uncovered” diamond stents for the management of distal malignant biliary obstruction. *Gut*. 2004;53(5):729-34.
2. Isayama H, Kawakubo T, Nakai Y, Tsujino T, Sasahira N, Yamamoto N, et al. Cholecystitis after metallic stent placement in patients with malignant biliary obstruction. *Clin Gastroenterol Hepatol*. 2006;4(9):1148-53.
3. Suk KT, Kim HS, Kim JW, Baik SK, Kwon SO, Kim HG, et al. Risk factor for cholecystitis after metal stent placement in malignant of distal malignant biliary obstruction. *Gastrointest Endosc*. 2006;64(4):522-9.
4. Kitano M, Ho H, Mahajan A, Gosain S, Jain A, Brock A, Rehan ME, et al. Management of complications associated with partially covered biliary metal stents. *Dis Dis Sci*. 2010;55(2):516-22.
5. Park DH, Kim MH, Choi JS, Lee SS, Seo DW, Kim JH, et al. Covered versus uncovered wallstent for malignant extrahepatic biliary obstruction: a cohort comparative analysis. *Clin Gastroenterol Hepatol*. 2006;4(6):790-6.
6. Lee HJ, Chung MJ, Park JY, Park SW, Nam CM, Song SY, et al. A prospective randomized study for efficacy of an uncovered double bare metal stent compared to a single bare metal stent in malignant biliary obstruction. *Surg Endosc*. 2017;31(8):3159-67.