



Transjugular Liver Biopsy: What to do if there is an Unfavorable Cavo-Hepatic Angle?

Kaci M¹, Bassaid T², Baghdadi M¹, Bouakline H³ and Zatir S^{4*}

¹Department of Gastroenterology, Oran Military Hospital, Algeria

²Department of Medical Imaging, Oran Military Hospital, Algeria

³Department of Pathology Anatomy, Oran Military Hospital, Algeria

⁴Department of General Surgery, Military Hospital of Oran, Algeria

Abstract

Introduction: The lack of catheterization of the hepatic vein is the leading cause of failure of transjugular liver biopsy. Indeed, in some situations and following anatomical changes, the cavo-hepatic angle becomes too high, not favorable to the access of the needle, making the biopsy difficult or impossible.

Several techniques have been described to overcome this difficulty; the purpose of this work is to show the interest of manual modification of the distal curvature of the metal cannula and its adaptation to the cavo-hepatic angle of the patient.

Materials and Methods: In 28 patients with chronic liver disease who were candidates for transjugular liver biopsy, the cavo-hepatic angle was measured systematically. A semi-automatic needle (18 gauges Quick-core set) with a rigid cannula with a 30° preformed distal end was used. The cavo-hepatic angle was estimated by tracing, on a digitized plate, a tangent to the dorsal spine, and that of the catheter in the hepatic position. When this angle was not favorable to the passage of the metal cannula, the distal end of the metal cannula was manually modified and adapted to the cavo-hepatic angle of the patient.

We analyzed the values, the situations that can modify the cavo-hepatic angle and the methods used to facilitate the passage in the hepatic vein.

Results: The cavo-hepatic angle averaged 48.2° (30° to 72°). In 32 patients (84.2%), he was less favorable at 60°. In 5 patients (18.5%), this angle was high, estimated on average at 68.1° (62° to 72°) unfavorable, it constituted an anatomical obstacle to the access of the metal cannula in the hepatic vein right. It was hypotrophic cirrhosis in 4 cases (66.6%) and ascites displacing the diaphragm upwards in 2 cases (33.3%).

After failures of two attempts of its establishment at the hepatic level, the cannula was manually modified, accentuating its curvature to form a new angle measuring on average 50°. The biopsy was successfully performed in 4 cases.

A failure was due to the impossibility of accessing the right hepatic vein despite the technical modification, in a cirrhotic patient with significant hepatic atrophy having a cavo-hepatic angle at 72°.

Liver tissue samples were obtained with 2 passages. The average length of the fragments was 13.5 mm (5 mm to 20 mm). A histological diagnosis was made in 20 cases (76.9%). Two minor complications were identified: spontaneously resolving supra-ventricular tachycardia related to the passage of the metallic guidewire in the right atrium, and bleeding at the cervical puncture site. No major complications have occurred.

Conclusion: The manual modification of the distal curvature of the semi-automatic needles and its adaptation to the cavo-hepatic angle of the patient makes it possible to access the liver with greater ease and safety and to reduce the failures of the hepatic biopsy by transjugular.

Keywords: Transjugular liver biopsy; Liver cavity angle; Tru-cut needle modification

OPEN ACCESS

*Correspondence:

Zatir S, Department of General Surgery,
Regional Military Hospital of Oran,
Algeria,

E-mail: s.zatir@yahoo.com

Received Date: 03 Oct 2019

Accepted Date: 01 Nov 2019

Published Date: 15 Nov 2019

Citation:

Kaci M, Bassaid T, Baghdadi M,
Bouakline H, Zatir S. Transjugular
Liver Biopsy: What to do if there is an
Unfavorable Cavo-Hepatic Angle?. Clin
Oncol. 2019; 4: 1668.

Copyright © 2019 Zatir S. This is an open access article distributed under the Creative Commons Attribution License, which permits unrestricted use, distribution, and reproduction in any medium, provided the original work is properly cited.

Introduction

Transjugular Liver Biopsy (BHT) is a method for taking a liver sample without crossing the hepatic capsule and peritoneum and is an alternative to transcutaneous liver biopsy in patients at high risk of bleeding [1].

The technique was described by Dotter [2] in 1964 and applied in humans in 1967 or several series using aspiration needles have been published [2-7].

In Algeria, the first transjugular biopsies were performed with aspiration needles in 2002, in a series of 50 patients [8]. In recent years, aspirating Ross needles have been replaced by semi-automatic needles (Set Quick-core biopsy). These have the advantage, the ease of use, the safety and the better quality of the samples obtained [9-13]. However, their cannula metal is thicker with standard preformed angulation of 30° [14,15].

The lack of catheterization of the hepatic vein is the first cause of failure of transjugular liver biopsy [16,17]. Indeed, the cavo-hepatic angle formed by the right hepatic vein and the vein. The lower cellular is variable; when it is too high it constitutes an anatomical obstacle and becomes unfavorable to the access of the metal cannula [17].

Several techniques have been described to overcome this difficulty, the purpose of this work is to show the interest of measuring the cavo-hepatic angle, to analyze the factors that can modify it as well as the contribution of manual modification of the radius of curvature of the rigid cannula and its adaptation to the patient's ACSH.

Materials and Methods

Prospective recruitment study in a population at high risk of hemorrhage, including 28 patients with chronic liver disease and candidates for transjugular liver biopsy. The study group consisted of (16 men and 12 women, whose average age was 38 years (17-70)).

The procedure was performed using a biopsy device, including a rigid cannula whose distal angulation is preformed at 30° and a 60 cm long, semi-automated Quick core needle of 18 gauges with a 20 min sampling slot (Figure 1).

The right internal jugular vein is punctured under ultrasound guidance thanks to a dedicated 7.5 MHz probe, followed by the introduction of an introducer fitted with an anti-reflux valve which limits bleeding during the procedure (Figure 2a,2b).

Liver biopsy is performed via the right hepatic vein, which is catheterized according to the Seldinger technique, by introducing a 0.035I hydrophilic guide in a 5F multipurpose catheter making progress all the up to VSHD under electrocardiographic monitoring and under intermittent fluoroscopic control (Figure 3a).

A hepatic vascular opacification is performed systematically to verify the correct position of the catheter and estimer sur a digitized image in frontal incidence value of the Cavo-Hepatic-Hepatic Angle (ACSH). This is formed by the tangent of the thoracic spine and that of a catheter in the hepatic position (Figure 3b).

The metal cannula is slipped on the guide and positioned in the vein above right hepatic (Figure 4a,4b).

When the ACSH is too high, the metal-rigid and inflexible cannula may be difficult to push up to the hepatic vein. In this situation and

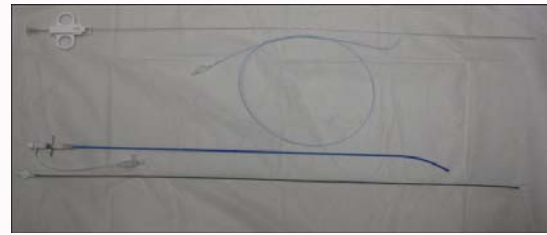


Figure 1: Semi-automatic system (Set Quick-core) for access and transjugular liver biopsy.

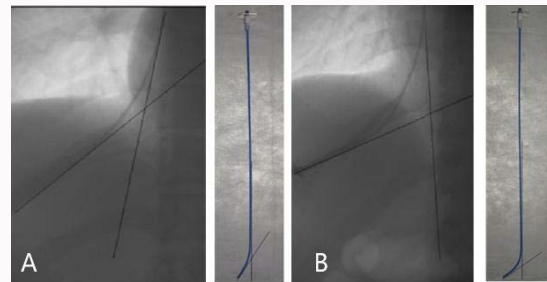


Figure 2: Adaptation of the patient's ACSH equipment to facilitate hepatic access. A) ACSH normal does not require modification of the cannula. B) ACSH not favorable 72° and adaptation of the distal curvature of the cannula.

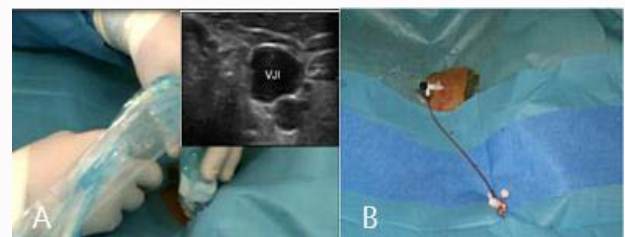


Figure 3: Chinstrap. A) Puncture of the internal jugular vein under ultrasound tracing. B) Setlet with valve set up at the right internal jugular vein.

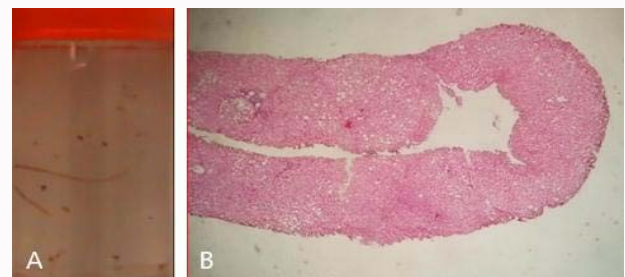


Figure 4: Hepatic fragment obtained with a Tru-cut needle. A) Liver samples in fixation fluid. B) Non-fragmented 2 cm liver biopsy. HES low magnification staining.

after failure of two attempts, the rigid cannula is withdrawn and the capillary curve is then uniformly relieved, according to the ACSH (Figure 5).

With the rigid cannula in place, the armed needle is then introduced to the hepatic parenchyma, allowing hepatic biopsy with safety in one or more passages. The macroscopic quality of the biopsy was judged on length and fragmentation, and then placed in the fixation fluid.

At the end of the procedure, opacification is performed to check

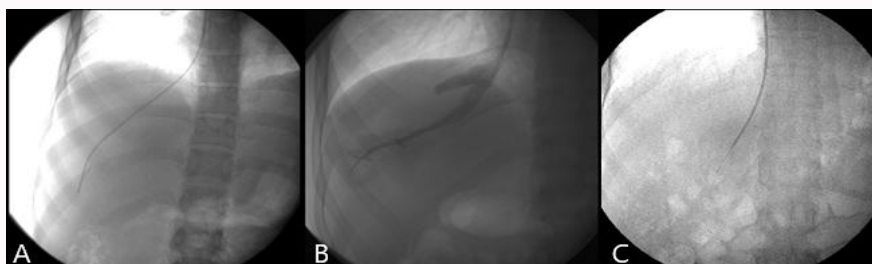


Figure 5: High hepatic access and biopsy with a semi-automatic needle. A) Catheterization of the right hepatic vein. B) High hepatic venography. Vs. (C) Biopsy needle in the hepatic parenchyma.

the absence of break-in of the capsule, liver access and Désilets are then removed, with implementation of compression bandage. Le patient remains in lying position during 6 h with regular hemodynamic monitoring.

Results

The transvenous route was indicated for coagulation disorders (TP<50% and/or platelet count <60000/mm) in 53.5% of cases (n=15), of which two had associated ascites. Other indications were hemodialysis in 25% of cases (n=7), massive ascites isolated in 10.7% (n=3), suspicion of cardiac liver in 7.1% (n=2) and liver amyloidosis in 3.5% of cases (n=1).

Puncture of the right internal jugular vein was successfully performed in 96.4% (n=27).

The hepatic catheterization concerned only the right hepatic vein.

The mean angle between the inferior vena cava and the hepatic vein was 48.2° (30° to 72°).

The value of ACSH varied according to the etiology, it was higher, in 3 cirrhotic patients with significant fibrosis ACSH=70.3° (69° to 72°) and in 2 patients with abundant ascites ACSH=66°.

We classified ACSH values into 6 increasing categories and estimated the difficulties of catheterization of the hepatic vein, requiring the modification of the curvature of the rigid cannula for each category of angle (Table 1).

Rigid cannula placement in the hepatic vein was more difficult when ACSH exceeded 60°, which involved five patients (18.5%) for whom ACSH was negative averaged 68.2°. (62° to 72°) (Table 2).

In these cases, the angulation of the cannula was manually altered in a harmonious way, increasing its radius of curvature proportionally to the calculated CADS, with successful placement in 15.3% (n=4 cases).

We counted two failures of the transjugular liver biopsy: one attributed to the impossibility of puncture of the right internal jugular vein and the second related to the failure of the introduction of the metal cannula at the VSHD level.

The average number of passages was 2 per procedure (1-3). Biopsies were considered fragmented in 8 patients, which represented a fragmentation rate of 30.7%. The average length of samples per pass before fixation was 13 mm (5 mm to 20 mm). The anatomopathological analysis determined the number of spaces gates on 22 samples (84.6%), it varied from 3 to 9 spaces gates with an average of 6.5 spaces gates. In 4 cases (15.3%), this criterion was not specified because of a fragmentation with excessive fibrosis in 3 cases

Table 1: Indication of the hepatic access set modification according to the cavo-hepatic angle.

| ACSH | Patients N=27 | Modification N=5 | Pas de modification N=22 |
|--------|---------------|------------------|--------------------------|
| | ACSH=48.2° | ACSH =68.1% | ACSH<60° |
| 30-39° | 8 | 0 | 8 |
| 40-49° | 9 | 0 | 9 |
| 50-59° | 5 | 0 | 5 |
| 60-69° | 2 | 2 | - |
| >70° | 3 | 3 | - |

Table 2: Success and technical failure after manual adaptation of the cannula in 6 cases.

| Over-hepatic catheterization | Patient ayant un ACSH >60° (N=5) |
|------------------------------|----------------------------------|
| Succès | 4 |
| Echec | 1 |

and infiltration by neoplastic cells in one case.

A histological diagnosis was determined in 20 cases (76.9%): carcinoma metastasis (1 case), autoimmune hepatitis (5 cases), primary biliary cirrhosis (2 cases), amyloidosis (1 case), chronic viral hepatitis with fibrosis extensive (5 cases), heart liver (2 cases), steatohepatitis (2 cases), Gaucher disease (1 case) and normal liver (1 case).

Two minor complications were identified: the first spontaneously resolving supraventricular tachycardia related to the passage of the metallic guidewire in the right atrium, and the second related to bleeding at the cervical puncture site in a patient with severe thrombocytopenia. No major complications have occurred.

Discussion

The development of semi-automatic needles and ultrasound guidance for VJI puncture has significantly improved the safety and efficacy of BHTJ [12-15,17,18].

However, the rigid and inflexible nature of the cannula of the hepatic access set makes it more difficult to pass through the ACSH and is the main cause of technical failure, reported in 43% of cases [9,14,17].

In fact, in a normal adult subject, the right hepatic vein forms an angle of 60° on average with the main axis of the vena cava. This angulation may be more important and constitute an anatomical obstacle in the case of atrophic liver, abundant ascites pushing up the liver and the diaphragm upwards, paralysis of the right diaphragmatic dome or in front of certain malformative vascular anomalies [9-12,19,20].

The failure of transjugular liver biopsy is then due to the impossibility of setting up or maintaining a rigid cannula while these veins can be catheterized with a flexible probe.

In our work, we estimated the value of this angle during the procedure. The mean value was 48.2°; this angle was high in four patients with liver fibrosis and two patients with abundant ascites.

In situations where cavo-hepatic angle is important, several methods can be used to facilitate the passage of the rigid metal cannula; the simplest is to ask the patient to take a deep breath to decrease the ACSH. However, this method requires the cooperation of the patient and the expected decrease in blood flow is limited to a few degrees [14,17,20]. The second method is to use a very rigid guide, allowing to vary the cavo-sus-hepatic angle, in order to cross it; however, this traumatic and unphysiological maneuver can lead to significant liver mobilization, which causes severe pain in patients and instability of the needle [12,20].

The third method consists in manually modifying the radius of curvature of the metal cannula of the hepatic access set; indeed, the angle preformed by the manufacturer is 30°, adapted to a normal anatomy of the ACSH, but not adapted to anatomical modifications [14].

Chevalier et al. [14], reported in a prospective study the interest of manual modification of the curvature of semiautomatic needles in case of non-favorable ACSH, indeed the duration of the realization of the procedure was relatively longer; but in these cases, there is often associated liver fibrosis and fragmentation of the biopsy core requiring multiple passes, however, modification of the cannula radius of curvature facilitates the catheterization of the adverse ACSHs, with a reduction in procedure of at least 10 min and consequently a reduction of the irradiation dose, by bringing to the procedures without modifications concerning these same angulations.

The success rate obtained with the semi-automatic system varies from 91% to 100% in the different series of the literature [9,17,21-24], in our study it was 92.8%. In order to easily access the liver and to limit technical failures, we voluntarily modified the angulation and the radius of curvature of the metal cannula of the hepatic access set in 6 patients (%) with a high ACSH. This modification was done manually to obtain a new curvature that can adapt to the angle of the patient, which allowed us to avoid 5 catheter failures.

Difficulty in puncturing IJV is the second leading cause of reported failure (26.8%); according to Soyer [11], this failure rate can be divided by four with ultrasound guidance [11,17,25]. In our series the jugular access was facilitated by the systematic use of ultrasound, a failure occurred in a dialysis patient, having had a central dialysis catheter with periorgular fibrous changes.

The majority of the complications described in the literature are minor in 6.5% [9,17,18,25-28]. Local cervical complications such as hematoma (0.6%), accidental carotid puncture and pneumothorax have become less common with ultrasound guidance because the needle can be followed until it enters the vein [11,17]. None of these complications occurred in our series through the systematic use of ultrasound. Bleeding at the point of cervical puncture is confined to major coagulation disorders as was the case in one of our patients with severe thrombocytopenia [9,17,28]. Major complications are rare (0.6%); the most serious are ventricular arrhythmia (0.04%) and hemoperitoneum secondary to perforation of the Glisson capsule

(0.2%) [28-30] this has been searched systematically.

Conclusion

Manual modification of the distal curvature of the semi-automatic needles and its adaptation to the cavo-hepatic angle of the patient makes it possible to access the liver with greater ease and safety, and to reduce the failures of the liver biopsy by transjugular way.

References

1. Nousbaum JB, Cadranet JF, Bonemaison G, Bourliere M, Chiche L, Chor H, et al. Recommendations pour la pratique clinique pour la réalisation de la ponction biopsie hépatique. *Gastroenterol Clin Biol*. 2002;26:848-78.
2. Dotter CT. Catheter biopsy Experimental technic for transvenous liver biopsy. *Radiology*. 1964;82(2):312-4.
3. Hanafee W, Weiner M. Transjugular percutaneous cholangiography. *Radiology*. 1967;88(1):35-9.
4. Rosch J, Antonovic R, Dotter CT. Transjugular approach to the liver, biliary system, and portal circulation. *Am J Roentgenol Radium Ther Nucl Med*. 1975;125(3):602-8.
5. Rathod K, Deshmukh H, Nihal L, Basappa S, Rathi P, Bhatia S. Transjugular liver biopsy using Tru-cut biopsy needle: KEM experience. *J Assoc Physicians India*. 2008;56:425-8.
6. Smith TP, Presson TL, Heneghan MA, Ryan JM. Transjugular biopsy of the liver in pediatric and adult patients using an 18-gauge automated core biopsy needle: a retrospective review of 410 consecutive procedures. *AJR Am J Roentgenol*. 2003;180(1):167-72.
7. Banares R, Alonso S, Catalina MV, Casado M, Rincon D, Salcedo M, et al. Randomized controlled trial of aspiration needle versus automated biopsy device for transjugular liver biopsy. *J Vasc Interv Radiol*. 2001;12(5):583-7.
8. Debzi N. La biopsie hépatique par voie transjugulaire : introduction et développement de la technique en Algérie (à propos de 50 cas). Thèse 2004, Alger.
9. Dohan A, Guerrachea Y, Boudiafa M, Gavini JP, Kaci R, Soyer P. Biopsie hépatique par voie transjugulaire: Indications, technique et resultants. *Journal de Radiologie Diagnostique et Interventionnelle*. 2014;95(1):13-8.
10. Ble M, Procopet B, Miquel R, Hernandez-Gea V, García-Pagán JC. Transjugular Liver Biopsy. *Clin Liver Dis*. 2014;18(4):767-78.
11. Soyer P, Fargeaudou Y, Boudiaf M, Rymer R. Transjugular liver biopsy using ultrasonographic guidance for jugular vein puncture and an automated device for hepatic tissue sampling: a retrospective analysis of 200 consecutive cases. *Abdom Imaging*. 2008;33(6):627-32.
12. Behrens G, Feral H. Tranjugular liver biopsy. *Semin Interv Radiol*. 2012;29(2):111-17.
13. Ishikawa T, Kamimura H, Tsuchiya A, Togashi T, Watanabe K, Seki K, et al. Comparison of a new aspiration needle device and the Quick-Core biopsy needle for transjugular liver biopsy. *World J Gastroenterol*. 2006;12(39):6339-42.
14. Chevallier P, Dausse F, Berthier F, Saint-Paul MC, Denys A, Schnyder P, et al. Transjugular liver biopsy: prospective evaluation of the angle formed between the hepatic veins and the vena cava main axis and modification of a semi-automated biopsy device in cases of an unfavorable angle. *Eur Radiol*. 2007;17(1):169-73.
15. Choo SW, Do YS, Park KB, Kim SH, Han YH, Choo I. Transjugular liver biopsy: modified Ross transseptal needle versus Quick-corebiopsy needle. *Abdom Imaging*. 2000;25(5):483-5.
16. Bruzzi JF, O'Connell MJ, Thakore H, O'Keane C, Crowe J, Murray JG. Transjugular liver biopsy: assessment of safety and efficacy of the Quick-Core biopsy needle. *Abdom Imaging*. 2002;27(6):711-5.

17. Kalambokis G, Manousou P, Vibhakorn S, Marelli L, Cholongitas E, Senzolo M, et al. Transjugular liver biopsy-indications, adequacy, quality of specimens, and complications- a systematic review. *J Hepatol.* 2007;47(2):284-94.
18. Mammen T, Keshava SN, Eapen CE, Raghuram L, Moses V, Gopi K, et al. Transjugular Liver Biopsy: A retrospective Analysis of 601 cases. *J Vasc Interv Radiol.* 2008;19(3):351-8.
19. De Hoyos A, Loredó ML, Martínez MA, Gil MR. Use of a stiff guide wire in transjugular liver biopsy in patients with a pronounced angle of the suprahepatic veins. *Ann Hepatol.* 2004;3(2):72-3.
20. Keshava SN, Mammen T, Surendrababu NRS, Moses V. Transjugular liver biopsy: What to do and what not to do. *Indian J Radiol Imaging.* 2008;18(3):245-8.
21. Miraglia R, Maruzzelli L, Minervini MI, Volpes R, Vizzini G, Gruttadauria S, et al. Transjugular liver biopsy in the transplant patients using an 18 gauge automated core biopsy needle. *Eur J Radiol.* 2011;80(3):e269-72.
22. Cholongitas E, Burroughs AK. Liver: Transjugular liver biopsy yields high-quality samples. *Nat Rev Gastroenterol Hepatol.* 2012;9(9):491-2.
23. Ishikawa T, Kamimura H, Tsuchiya A, Togashi T, Watanabe K, Seki K, et al. Comparison of a new aspiration needle device and the Quick-Core biopsy needle for transjugular liver biopsy. *World J Gastroenterol.* 2006;12(39):6339-42.
24. Maciel AC, Marchiori E, de Barros SG, Cerski CT, Tarasconi DP, Ilha Dde O. Transjugular liver biopsy: histological diagnosis success comparing the trucut to the modified aspiration Ross needle. *Arq Gastroenterol.* 2003;40(2):80-4.
25. Ble M, Procopet B, Miquel R, Hernandez-Gea V, García-Pagán JC. Transjugular Liver Biopsy. *Clinics in Liver Disease.* 2014;18(4):767-78.
26. Dinkel HP, Wittchen K, Hoppe H, Dufour JF, Zimmermann A, Triller J. Transjugular liver core biopsy: indications, results, and complications. *Rofo.* 2003;175(8):1112-9.
27. Cholongitas E, Burroughs AK. Is it difficult to obtain an optimal liver biopsy specimen? *Hepatology.* 2010;51(1):355-6.
28. Fricker Z, Levy E, Kleiner D, Taylor JG 6th, Koh C, Holland SM, et al. Case series: biliary leak after transjugular liver biopsy. *Am J Gastroenterol.* 2013;108(1):145-7.
29. Koshy CG, Eapen CE, Lakshminarayan R. Transvenous embolization to treat uncontrolled hemobilia and peritoneal bleeding after transjugular liver biopsy. *Cardiovasc Intervent Radiol.* 2010;33(3):624-6.
30. Dohan A, Derrache Y, Dautry R, Boudif M, Ledref O, Sirol M, et al. Complications majeures de la biopsie hépatique transjugulaire. *J De Radiologie Diagnostique et Interventionnelle.* 2015;96(2):142-8.