Clinics in Oncology

Research Article
Published: 02 Feb, 2024

Small Nodes Big Problem LN-RADS Classification Structure Reporting for Lymph Nodes

Chudobinski C[1], Kołacinska A[2], Gottwald L[3] and Cieszanowski A[1]*

[1]Department of Radiology, Copernicus Memorial Hospital, Poland

[2]Department of Surgery, Copernicus Memorial Hospital, Poland

[3]Department of Radiotherpy, Copernicus Memorial Hospital, Poland

Introduction

There is real need for creation and implementation simple tool for better communication between radiologists, clinicians and pathologists concerning LNs assessment; especially giving clear signal, describing risk of cancer involvement. At present, despite many valuable papers touching upon only single method, region of the body or cancer type, there is no universal system for LNs assessment, which allows to express in simple way what kind of lymph node we are dealing with. LN may be described with many radiological features such as long axis diameter, short axis diameter, shape, margins, structure, echogenicity, vascularity, elasticity, density, enhancement pattern, signal intensity in T2 WI, T1 WI, signal intensity in diffusion WI and ADC maps, etc. Radiological evaluations of lymph nodes are not standardized - sometimes short and enigmatic e.g. "... 10 mm lymph node..." another time very long, sophisticated, full of specialistic terms making them time-consuming and difficult for understanding for non-radiologists. The RECIST criteria are based on 10 mm short axis diameter, CHESON criteria have 15 mm long axis diameter as cut off value but they do not take into consider smaller structural changes such early malignant infiltration and macrometastases (Figure 1).

This article is the proposal of easy and intuitive system for lymph nodes assessment - LN-RADS, analogous to well-known and commonly using BI-RADS and PI-RADS systems. This universal idea will improve communication between radiologists, pathologists and clinicians making more accurate further therapeutic decisions.

In the background authors present interesting cases and review of contemporary radiological tools for LNs assessment.

Discussion

The meaning of lymph nodes seems to be depreciated, however in all neoplastic tumors it's crucial for proper staging in TNM and taking further treatment decisions. For instance, involvement of lymph nodes in head and neck squamous cell carcinoma is most important prognostic factor [1]. According to Som the presence of a single ipsilateral or contralateral metastatic node reduces survival by 50% and bilateral disease by a further 50% [2]. Wrong assessment of lymph nodes involvement with cancer leads to miss-staging and failure. We can depict two major aspects of misdiagnosis: First - social, individual aspect of every patient - personal tragedy of man who lose chance for optimal treatment and the second one - global, economical effect of increasing costs of hospitalization and compensation due to medical mistake claims. Also, we can observe high rate of patient referred for lymph nodes biopsy meanwhile they are only palpable or seems to be enlarged but in real, during ultrasound scan, turns out they have no structural features of malignancy. In consequence people are stigmatized, suffer from fear of cancer, do not believe in negative diagnosis, demanding additional examinations what causes in medical system overloading with unnecessary procedures.

It is obvious that the wrong assessment of lymph nodes is dangerous in both situations as well false positive diagnosis, when patient is excluded from lifesaving treatment as false negative, when patient is undergone, in assumption, radical surgery which appears finally ineffectual.

It seems that the one of the reasons of this situation is lack of precise, but also, simple system of lymph nodes assessment overstepping RECIST's 10 mm diameter paradigm and going beyond it, to methods and criteria which exists in contemporary radiology but are not used enough.

OPEN ACCESS

***Correspondence:**
Cezary Chudobinski, Department of Radiology, Copernicus Memorial Hospital, Lodz, Poland

Received Date: *13 Jan 2024*
Accepted Date*: 28 Jan 2024*
Published Date*: 02 Feb 2024*

Citation:
Chudobinski C, Kołacinska A, Gottwald L, Cieszanowski A. Small Nodes Big Problem LN-RADS Classification Structure Reporting for Lymph Nodes. Clin Oncol. 2024; 9: 2054.

ISSN: 2474-1663

Let's look at exemplary radiological lymph nodes evaluations and try to decide how to treat them - like malignant or not?

1. …10 mm axillary node…

2. …50 mm inguinal lymph node…

3. ...27 mm × 11 mm submandibular ln with hypoechoic cortex, mainly central vascularity in Color Doppler, with vessels along the hilum, low resistance doppler spectrum, and elasticity score 3…

4. …24 mm × 8 mm iliac lymph node with restricted diffusion and low ADC value ca 700...

5. …24 mm × 13 mm axillary lymph node with strong enhancement and curve type III (washout)

Despite of given measurements, structural and functional information, for many doctors, especially non-radiologists, it may be problematic to say what kind of lymph nodes we are dealing with, and probably this phenomenon will be growth up parallel to radiology development.

According to well-known RECIST 1.1 pathologically enlarged lymph node is defined as a node ≥ 10 mm in the short axis [3]. CHESON criteria established that lymph nodes should be considered abnormal if the long axis is more than 1.5 cm regardless of the short axis [4], in last consensus from 2014, apart from FDG-PET, there are not changes in guidelines concerning lymph node assessment [5]. It means that, excluding mentioned PET-CT, contemporary radiological assessment of lymph nodes in oncology and hematology is based on size criteria, not more complex valuable assessment using modern radiology methods. Therefore, the emerging question is - should we go beyond?

Comment ad case 1. "… 10 mm axillary node…"

The presented description is an exemplary of quick and minimalistic radiological approach. We have the only one diameter and we don't know which one - longest or short axis diameter. First - it's absolutely to little information to classify lymph node as malignant or not, secondly - size is important but not crucial. In prostate cancer only 30% of metastatic lymph nodes are detected, 83% of metastatic LN had long axis only 5 mm and 50% are barely 3 mm [6]. Using only 10 mm short axis criteria we miss over 80% of metastatic lymph nodes, despite possible features of malignancy in smaller nodes. The Figure 2 presents breast cancer tumor (star) and tree lymph nodes in the right axilla. The largest one (two arrows) is normal-fatty node (LN-RADS 2), a bit closer to the breast tumor, there are two smaller but suspicious for metastases Lymph Nodes (LN-RADS 4); the first (one arrow) has irregular shape, strong contrast enhancement, without medulla-cortex differentiation, the second one tiny – 5 mm × 4 mm with focal cortical thickening and focal enhancement (two arrowheads) which are radiological appearance of macrometastases. It's proven that lymph node size is not a reliable parameter for the evaluation of metastatic involvement [7-9] and therefore we should analyze additional structural features - shape which is rounded or irregular, especially with focal cortical thickening, as well as normal fatty hilum absence [10,11]. Choi et al. revealed that cortical thickness greater than 3 mm was the most accurate indicator, with 4.14 times increased risk of the presence of an axillary lymph node metastasis as compared to cortical thickness less than 3 mm.

The absence of a hilum showed the highest specificity for axillary lymph node metastasis (94.6%) [12]. Sceptics will say that even best radiological tools do not show micrometastases and they are obviously right, but do we need really visualize micromets? Probably not, because outcomes may be dependent to amount of cancer cells in lymph nodes; if "critical mass" is reached, the prognosis get worse dramatically. This phenomenon was observed by Huvos, who compared prognosis of patient with breast cancer in context of axillary nodes levels involvement and its type - macro *vs.* micrometastases. Macrometastases by definition having diameter 2 mm or more present a volume 100 to 100,000 times that of micrometastases measuring less than 2 mm. It turned out that patients with Ist level micrometastases had very similar prognosis to patients with no meets and quite different prognosis to group with macrometastases at the

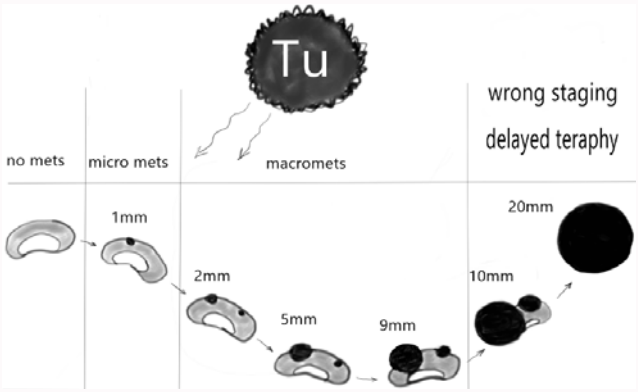

Figure 1: The development of metastases in LNs.

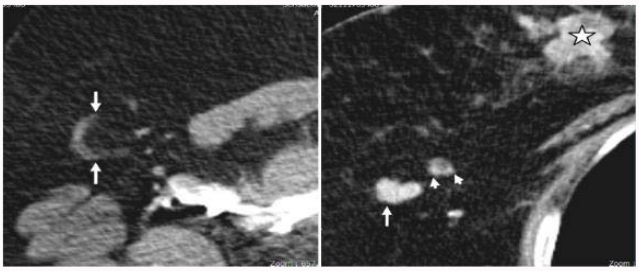

Figure 2: The images above present breast cancer tumor (star) and tree lymph nodes in the right axilla. The largest one (two arrows) is normal-fatty node (LN-RADS 2), a bit closer to the breast tumor there are two smaller but suspicious for metastases lymph nodes (LN-RADS 4) - the first one (single arrow) has irregular shape, strong contrast enhancement, without medulla-cortex differentiation, the second one tiny - 5x4mm has focal cortical thickening and focal enhancement (two arrowheads).

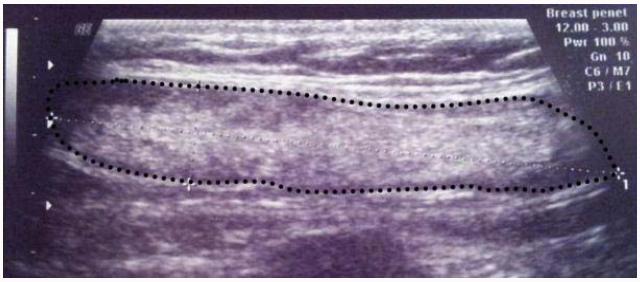

Figure 3: The images above present typical enlarged but benign steatotic lymph node with extended fatty hilum and thin regular atrophic cortex (according to proposed new classification LN-RADS 2). Worth mentioning is that sometimes cortex is extremely narrowed and lymph nodes if surrounded by fat are pretty difficult to espy. The border is marked by dots.

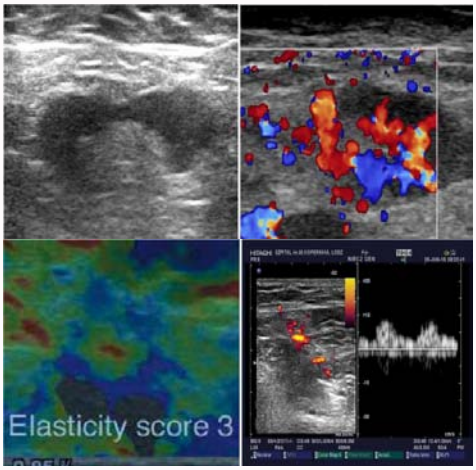

Figure 4: The images above present mentioned features in B-mode, Color Doppler, Spectral Doppler and elastography – lymph node - enlarged, with hypoechoic regular wide cortex, well-defined hiperechoic hilum.

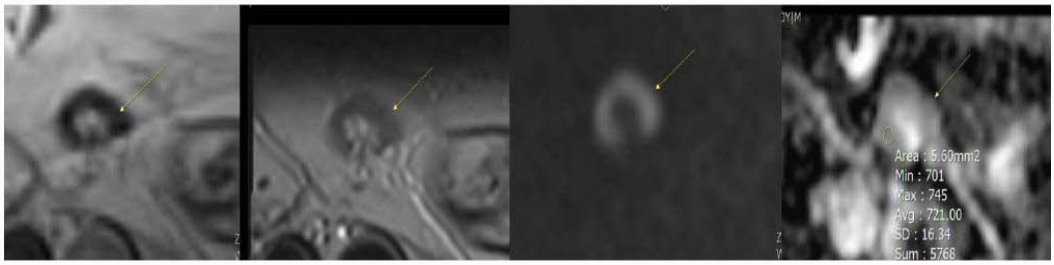

Figure 5: Iliac lymph node in T1WI, T2WI, DWI and ADC. Images present normal anatomy of lymph node but evident restriction of diffusion - high signal in DWI with low ADC value.

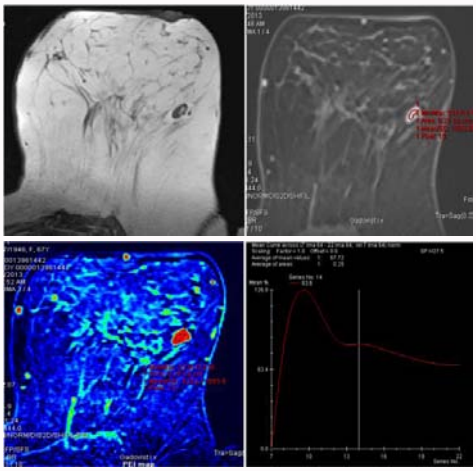

Figure 6: It is known that dynamic contrast enhancement curve type III, called washout is typical feature of breast cancer, but on the other hand it's frequent pattern of enhancement normal or reactive lymph nodes, if localized intramammary mimicking malignant lesion [4].

same Ist level [13]. According to this observation micrometastases have small influence for the outcome, on the other hand macrometastases seems to be key point in treatment improvement. The contemporary radiological tools have enough resolution to find foci of macrometastases – between 2 mm to 10 mm which are ignored by present approach based on RECIST 10 mm diameter.

Comment ad case 2… 50 mm inguinal lymph node…

Alarming diameter 5 cm looks dangerous, but print from ultrasound scan demonstrates typical benign fatty infiltration, regular and atrophic very thin cortex and despite large long axis size there is no need for further investigations. It's very common phenomenon when adipose tissue growths in the node from the hilum toward the cortical zone, producing distention of the capsule and causing atrophy of the lymphoid tissue, sometimes attain considerable volume suggesting neoplasm [14].

According to size criteria many of these fatty lymph nodes are enlarged and because of size maybe incorrectly treated as pathologic (metastatic). It is an exemplary of misunderstanding caused by

thinking about lymph nodes only through the lens of size. There is needed additional information describing general probability of metastases involvement. We know that fatty lymph nodes are quite usual findings in region of axilla or groin, especially at elderly people. It is an example of LN-RADS 2 category (Figure 3).

Comment ad case 3... 27 mm × 11 mm submandibular lymph node with hypoechoic cortex, central vascularity in Color Doppler, with vessels along the hilum, and low resistance spectrum, and elasticity score 3…

Case 3. It's kind of "reader's confusing depiction", probably for most of clinicians and many radiologists. Despite lot of information, it's still open question: What should I do with this patient?

The majority of authors agree that most important are B-mode features like well-preserved hyperechoic hilum and oval shape, Longest to Transverse diameter ratio (L/T) over 2, regular hypoechoic cortex which are typical of benign – normal or reactive lymph nodes, on the contrary metastatic lymph nodes are more rounded or irregular, without hilar echo, sometimes with blurred borders due to capsule infiltration [15-18] (Figure 4).

Power Doppler and Color Doppler may be helpful but its value is controversial and color-flow criteria have fewer predictive advantages. Ariji et al. [19] reported that the hilar blood flow was shown only in reactive lymph nodes and never appeared in the metastatic nodes. In contrast, Tschammler et al. [20] found that hilar blood flow appeared both in the reactive and metastatic lymph nodes at equivalent rates. Both authors raised that parenchymal blood flow pattern or subcapsular vessels indicates metastatic lymph nodes. Toru in the study of HNSCC confirmed that hilar blood flow was shown exclusively in reactive lymph nodes. Difference between outcomes may be caused by technical issues, type of neoplasm and size of lymph nodes. Hilar flow is node size dependent and therefore in small nodes may be very week - below transducer sensitivity, in larger normal lymph nodes is usually visible, in bigger reactive nodes is strong. Summarize, flow pattern assessment using Power or Color Doppler should be performed in wider context, including many factors, especially body region and type of pathology cancer/lymphoma/tuberculosis/others.

Elastography is pretty novel ultrasound option which demonstrates color maps of elasticity of examined structures. According to many researchers' metastatic lymph nodes present lower elasticity in comparison to normal or reactive lymph nodes. Sensitivity, specificity, and accuracy of elastography was 83%, 100%, and 89% [21]. With a cutoff between elasticity scores of 2 and 3, elastography showed 80.7% sensitivity, 66.7% specificity, and 73.4% accuracy. With a cutoff between B-mode sonographic scores of 1 and 2, B-mode sonography showed 74.2% sensitivity and 78.8% specificity. Combined B-mode and Elastography sonography showed higher sensitivity (87.1%) than B-mode sonography alone. With a strain ratio cutoff point of 2.3, sensitivity was 82.8%, and specificity was 56.3% [22].

The method is highly subjective, examiner dependent and difficult for standardization, especially between different departments or hospitals equipped with various apparatus and software, what makes it not easy for wider implementation, however may be useful in certain cases. In presented exemplary submandibular lymph node does not contain stiff/rigid/hard regions what is feature of benignity, suggesting reactive lymph nodes.

Reactive lymph nodes are due to inflammation and therefore clinical history is very important factor of final diagnosis especially in submandibular region (field IB) reactive nodes enlargement is very common. Among all body area head and neck are localization of 55% of adenopathy. Statistics show that lymphadenopathy is frequent disorder - 0.6% annual incidence in the general population [23]. Fijten analyzed population of 2,556 patients who presented with unexplained lymphadenopathy to GP, 256 (10%) were referred to a subspecialist and 82 (3.2%) required a biopsy, but only 29 (1.1 %) had a malignancy [24]. Very important factor is age - patients 40 years of age and older with unexplained lymphadenopathy have about a 4% risk of cancer versus a 0.4% risk in patients younger than age 40 [23]. Despite high value of age related and other statistic factors every patient should be treated individually and independently. This data shows how important and necessary is using direct radiological criteria rather than classical clinical criterion "palpable *vs.* nonpalpable" with statistical factors, especially in the neck region where lymph nodes are easily available for precise high frequency ultrasound.

In clear inflammatory process and typical appearance of reactive lymph node category LN-RADS 3 should be stated. If there are any morphological deviations or oncological background, category LN-RADS 4 should be considered.

Comment ad case 4.… 24 mm × 8 mm iliac lymph node with restricted diffusion and low ADC value ca 700...

Diffusion-Weighted Imaging (DWI) is a functional technique having ability to depict level of movement of water molecules. The magnitude of these Brownian motions in such tissue environment is expressed as Apparent Diffusion Coefficient (ADC). Diffusion-weighted imaging is very important part of contemporary MRI imaging in oncology. It's proved that tissue of many types of cancers, characterized by dense cellular structure, cause restriction of water's Brownian motions, increasing signal on DWI images and giving low value on ADC maps. Moreover, value of ADC may be a measurement of malignancy - ADC values were found to be negatively correlated with the postsurgical Gleason grade in patients with prostate cancer as well as ADC values also significantly predict tumor aggressiveness [25-31]. DWI may help in monitoring the response to chemo or radiotherapy [32]. This tool also may be useful in lymph node assessment, however differentiation between benign and metastatic LNs is problematic, because even normal nodes can reduce diffusion due to primary high cellularity (Figure 5).

Despite mentioned difficulties with natural high cellular density of lymph nodes and high range of standard deviation of lymph nodes ADC value between patients, some authors search for solutions overcoming it. Ouki Yasui found that lymph node ADC to tumor ADC ratio (LN\T) is more reliable and improving accuracy in metastatic lymph nodes detection with sensitivity 76.6% and specificity 80.2% [33]. Apart from attempts of differentiation normal and metastatic LNs on ADC maps there is another advantage of DWI. Thanks to natural high tissue density even small nodes are very well visible in DWI especially on high b value images, giving opportunity for their quick localization, for further morphological evaluation in other sequences [34]. Next important reason for exploring DWI potential is "wait-and-see policy" for clinical complete responders after chemoradiation for rectal cancer, where is real need, for early finding recurrence in lymph nodes [35]. Summarize DWI is valuable method in node assessment but because of its complexity very difficult for interpretation for non-radiologists therefore LN-RADS

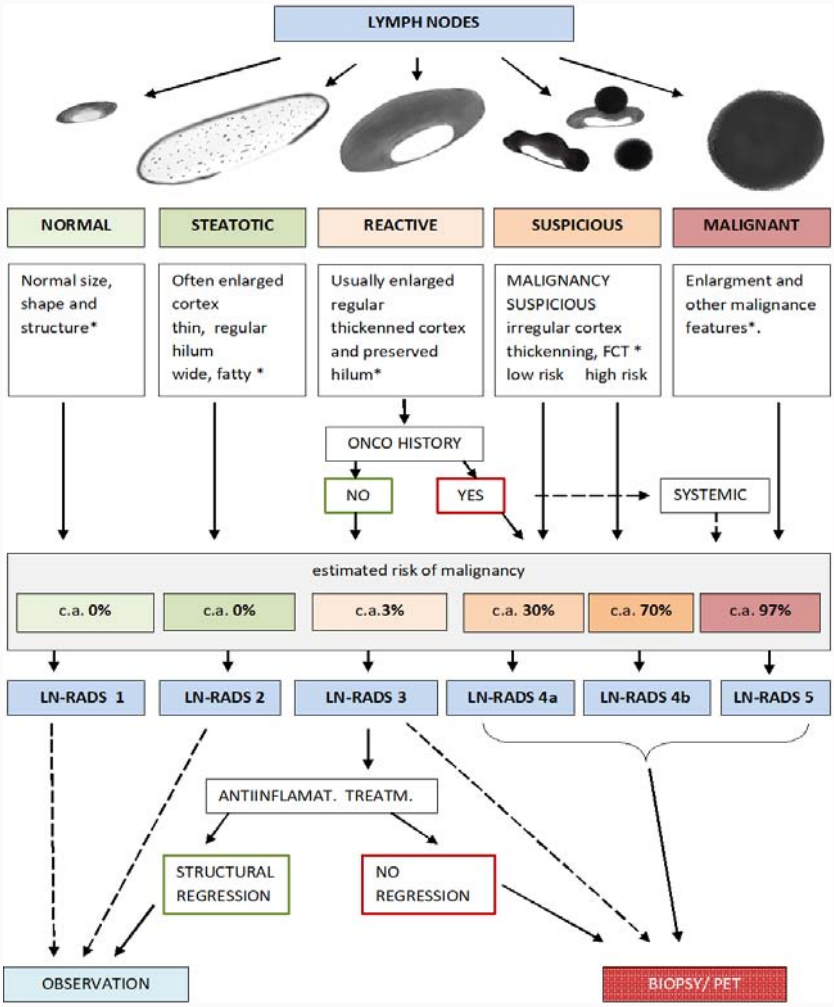

Figure 7: Lymph Nodes.

classification would be very helpful.

Comments ad case 5.... 24 mm × 13 mm axillary lymph node with strong enhancement and curve type III (washout)

It is widely known that dynamic contrast enhancement curve type III, called washout curve is typical feature of breast cancer and it can be read out as symptom of malignancy [36].

In really washout is frequent pattern of enhancement of normal or reactive lymph nodes as well axillary as intramammary, in last case mimicking malignant breast lesion. The knowledge of that phenomenon allows to avoid invasive procedures. A lot of intramammary lymph nodes are visible in second look ultrasound scan, having typical echo structure of normal or reactive lymph nodes. This case is warning against free transfer of radiological rules from primary tumor to lymph nodes (Figure 6).

Summarize

As we see in presented material, plenitude of radiological methods, plurality of features describing lymph nodes and also multiplicity of possible anatomical variants of them makes that communication between radiologist and oncologist, surgeon, pathologists and other specialists may be difficult and leads to misdiagnosis.

The LN-RADS scoring system, universal for any kind of diagnostic tool, realizes the idea of simplifying it. According to LN-RADS scoring LN-RADS 1 including normal LNs – oval, no changes in architecture, size and vascularization; LN-RADS 2 fatty, post-inflammatory LN - may be enlarged, with fatty hilum and regular thin cortex, without others changes; LN-RADS 3 describe reactive, probably benign due to active inflammatory LN - usually moderately enlarged, with regular cortex, maybe hypervascularized, with central regular vessels; LN-RADS 4 its group of suspicious for malignancy LNs with irregular cortex with focal thickening, especially abnormal architecture of vascularization, size maybe normal; LN-RADS 5 group presents high probability of malignancy LNs - enlarged, rounder than oval, without normal differentiation for hilum and cortex, especially with abnormal vascularization architecture or blurred borders – Table 1.

LN-RADS seems to be promising tool for categorization of LDs, however we can foresee growth of false positive diagnosis but on the other hand it's known that underestimation of metastatic lymph nodes is pretty high. Regarding to 20% risk of occult lymph nodes metastases, tendency to overestimation in LN-RADS seems to reduce false negative diagnosis and stand us closer to real state of nodal involvement. LN-RADS gives additional value in targeted therapies such radiotherapy, being very helpful in planning GTV including small but suspicious lymph nodes. Classification may be very useful

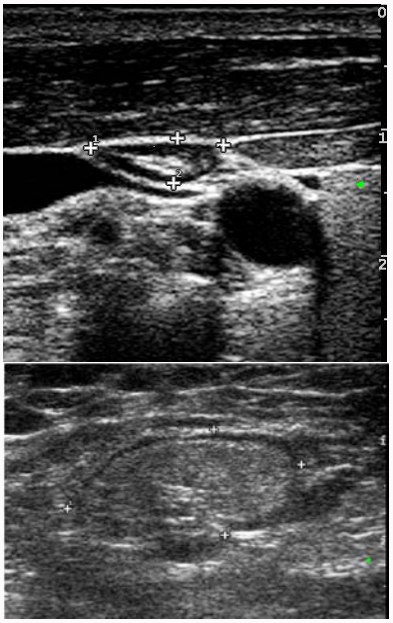

Figure 8a: LN-RADS 1 normal LN 10 mm × 3.5 mm History: Local cervical pain (HP negative).
Figure 8b: LN-RADS 2 - steatotic LN 23 mm × 11 mm. History: Palpable LN enlargement (HP negative).

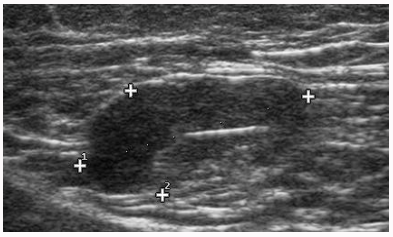

Figure 9: LN-RADS 3 - reactive LN 29 mm × 16 mm; acute laryngitis- (HP negative).

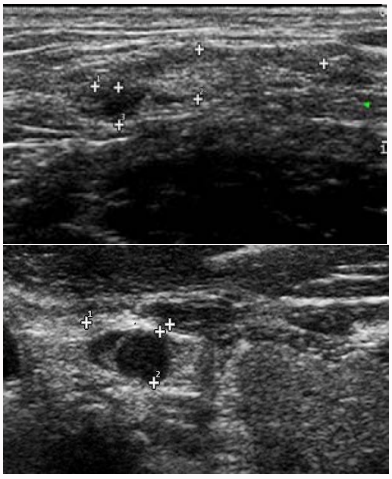

Figure 10a: LN-RADS 4a - low suspicinous; 20 mm × 2.6 mm with focal thickening of cortex. History of Melanoma malignum. (HP Melanoma malignum)
Figure 10b: LN-RADS 4b LN 8.5 mm × 4 mm with 4 mm FCT. History: Cervical lymphadenopathy. HP: Non-small cell cancer.

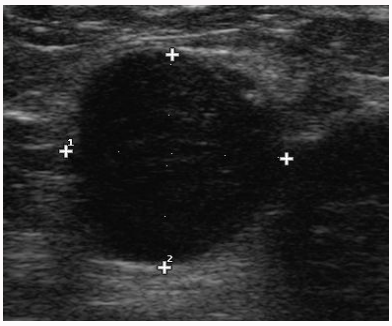

Figure 11: LN-RADS 5 LN 21 mm × 21 mm History: Merkel Cell Carcinoma. HP: Small cell cancer.

primary assessment as well in follow-up of regional lymph nodes after melanoma malignant excision with high risk of recurrence.

The strength of proposed LN-RADS is simplicity. The assessment is universal for all radiological methods - US, CT, MRI and specialistic tools - power Doppler, spectral Doppler, CEUS, elastography, DCE, DWI, ADC, etc.

LN-RADS Classification Structure Reporting for Lymph Nodes

LN-RADS 1 normal LN – oval, no changes in architecture, size and vascularization.

LN-RADS 2 fatty, post-inflammatory LN - may be enlarged, with fatty hilum and regular thin cortex.

LN-RADS 3 reactive probably benign due to active inflammatory LN - usually moderately enlarged, with regular cortex, maybe hypervascularized, with central regular vessels.

LN-RADS 4 suspicious for malignancy (LN-RADS 4a low suspicious; LN-RADS 4b high suspicious of malignancy) irregular cortex with focal thickening, especially abnormal architecture of vascularization, size maybe normal.

LN-RADS 5 very high probability of malignancy LN - usually enlarged, rounder than oval, without normal differentiation for hilum and cortex, especially with abnormal vascularization architecture or blurred borders etc. More information in next chapter in Table 1 and 2 (Figures 7-11).

References

1. Woolgar JA, Rogers SN, Lowe D, Brown JS, Vaughan ED. Cervical lymph node metastasis in oral cancer: the importance of even microscopic extracapsular spread. Oral Oncol. 2003;39:130-7.
2. Som PM. Detection of metastasis in cervical lymph nodes: CT and MR criteria and differential diagnosis. AJR. 1992;158:961-9.
3. Eisenhauer EA, Therasse P, Bogaerts J, Schwartz LH, Sargent D, Ford R, et al. New response evaluation criteria in solid tumors: Revised RECIST guideline (version 1.1). Eur J Cancer. 2009;45(2):228-47.
4. Cheson BD, Pfistner B, Juweid ME, Gascoyne RD, Specht L, Horning SJ, et al. Revised response criteria for malignant lymphoma. J Clin Oncol. 2007;25(5):579-86.
5. Barrington SF, Mikhaeel NG, Kostakoglu L, Meignan M, Hutchings M, Müeller SP, et al. Role of imaging in the staging and response assessment of lymphoma: Consensus of the international conference on malignant lymphomas imaging working group. J Clin Oncol. 2014;32:3048-58.
6. Hovels AM, Heesakkers RA, Adang EM, Jager GJ, Strum S, Hoogeveen YL, et al. The diagnostic accuracy of CT and MRI in the staging of pelvic lymph nodes in patients with prostate cancer: a meta-analysis. Clin Radiol.

2008;63:387-95.

7. Leslie A, Fyfe E, Guest P, Goddard P, Kabala JE. Staging of squamous cell carcinoma of the oral cavity and oropharynx: A comparison of MRI and CT in Tand N-staging. J Comput Assist Tomogr. 1999;23:43-9.

8. Prenzel KL, Monig SP, Sinning JM, Baldus SE, Brochhagen HG, Schneider PM, et al. Lymph node size and metastatic infiltration in non-small cell lung cancer. Chest. 2003;123:463-7.

9. Tiguert R, Gheiler EL, Tefilli MV, Oskanian P, Banerjee M, Grignon DJ, et al. Lymph node size does not correlate with the presence of prostate cancer metastasis. Urology. 1999;53:367-71.

10. Yoshimura G, Sakurai T, Oura S, Suzuma T, Tamaki T, Umemura T, et al. Evaluation of axillary lymph node status in breast cancer with MRI. Breast Cancer. 1999;6:249-58.

11. Jager GJ, Barentsz JO, Oosterhof GO, Witjes JA, Ruijs SJ. Pelvic adenopathy in prostatic and urinary bladder carcinoma: MR imaging with a three-dimensional T1-weighted magnetization-prepared-rapid gradient-echo sequence. AJR. 1996;167:1503-7.

12. Choi YJ, Ko EY, Han BK, Shin JH, Kang SS, Hahn SY. High-resolution ultrasonographic features of axillary lymph node metastasis in patients with breast cancer. Breast. 2009;18(2):119-22.

13. Huvos AG, Hutter RV, Berg JW. Significance of axillary macrometastases and micrometastases in mammary cancer. Ann Surg. 1971;173(1):44-6.

14. Leborgne R, Leborgne F, Leborgne JH, Soft-tissue radiography of axillary nodes with fatty infiltration. Radiology. 1965;84(3).

15. Ahuja A, Ying M. An overview of neck node sonography. Invest Radiol. 2002;37:333-42.

16. Chikui T, Yonetsu K, Nakamura T. Multivariate feature analysis of sonographic findings of metastatic cervical lymph nodes: Contribution of blood flow features revealed by power doppler sonography for predicting metastasis. AJNR Am J Neuroradiol. 2000;21:561-7.

17. Rubaltelli L, Proto E, Salmaso R, Bortoletto P, Candiani F, Cagol P. Sonography of abnormal lymph nodes in vitro: correlation of sonographic and histologic findings. AJR Am J Roentgenol 1990;155:1241-4.

18. Sutton RT, Reading CC, Charboneau JW, James EM, Grant CS, Hay ID. US guided biopsy of neck masses in postoperative management of patients with thyroid cancer. Radiology. 1988;168:769-72.

19. Ariji Y, Kimura Y, Hayashi N, Onitsuka T, Yonetsu K, Hayashi K, et al. Power Doppler sonography of cervical lymph nodes in patients with head and neck cancer. AJNR Am J Neuroradiol 1998;19:303-7.

20. Tschammler A, Ott G, Schang T, Seelback-Goebel B, Schwager K, Hahn D. Lymphadenopathy: Differentiation of benign from malignant disease: color Doppler US assessment of intranodal angioarchitecture. Radiology. 1998;208:117-23.

21. Alam F, Naito K, Horiguchi J, Fukuda H, Tachikake T, Ito K. Accuracy of sonographic elastography in the differential diagnosis of enlarged cervical lymph nodes: Comparison with conventional B-mode sonography. AJR. 2008;191:604-10.

22. Choi JJ, Kang BJ, Kim SH, Lee JH, Jeong SH, Yim HW, et al. Role of sonographic elastography in the differential diagnosis of axillary lymph nodes in breast cancer. J Ultrasound Med. 2011;30:429-36.

23. Ferrer R. Lymphadenopathy: Differential diagnosis and evaluation. Am Fam Physician. 1998;58(6):1313-20.

24. Fijten GH, Blijham GH. Unexplained lymphadenopathy in family practice. An evaluation of the probability of malignant causes and the effectiveness of physicians' workup. J Fam Pract. 1988;27:373-6.

25. Nagarajan R, Margolis D, Raman S, Sheng K, King C, Reiter R, et al. Correlation of Gleason scores with diffusion-weighted imaging findings of prostate cancer. Adv Urol. 2012;2012:374805.

26. As NJ, Souza NM, Riches SF, Morgan VA, Sohaib SA, David PD, et al. A study of diffusion-weighted magnetic resonance imaging in men with untreated localised prostate. Eur Urol. 2009;56:981-7.

27. Zelhof B, Pickles M, Liney G, Gibbs P, Rodrigues G, Kraus S, et al. Correlation of diffusion-weighted magnetic resonance data with cellularity in prostate cancer. BJU Int. 2009;103:883-8.

28. Tamada T, Sone T, Jo Y, Toshimitsu S, Yamashita T, Akira Y, et al. Apparent diffusion coefficient values in peripheral and transition zones of the prostate: Comparison between normal and malignant prostatic tissues and correlation with histologic grade. J Magn Reson Imaging. 2008;28:720-26.

29. Turkbey B, Shah VP, Pang Y, Bernardo M, Xu S, Kruecker J, et al. Is apparent diffusion coefficient associated with clinical risk scores for prostate cancers that are visible on 3-T MR images? Radiology. 2011;258:488-95.

30. Itou Y, Nakanishi K, Narumi Y, Nishizawa Y, Tsukuma H. Clinical utility of Apparent Diffusion Coefficient (ADC) values in patients with prostate cancer: can ADC values contribute to assess the aggressiveness of prostate cancer? J Magn Reson Imaging. 2011;33:167-72.

31. Hambrock T, Somford DM, Huisman HJ, Oort IM, Witjes JA, Hulsbergen-van de Kaa CA, et al. Relationship between apparent diffusion coefficients at 3.0-T MR imaging and Gleason grade in peripheral zone prostate cancer. Radiology. 2011;259:453-61.

32. Liu L, Wu N, Ouyang H, Dai JR, Wang WH. Diffusion-weighted MRI in early assessment of tumour response to radiotherapy in high-risk prostate cancer. Br J Radiol. 2014;87(1043):20140359.

33. Yasui O, Sato M, Kamada A. Diffusion-weighted imaging in the detection of lymph node metastasis in colorectal cancer. Tohoku J Exp Med. 2009;218(3):177-83.

34. Verma S, Rajesh A, Morales H, Lemen L, Bills G, Delworth M, et al. Assessment of aggressiveness of prostate cancer: correlation of apparent diffusion coefficient with histologic grade after radical prostatectomy. AJR Am J Roentgenol. 2011;196(2):374-81.

35. Maas M, Beets-Tan RG, Lambregts DM, Lammering G, Nelemans PJ, Engelen SM, et al. Wait-and-see policy for clinical complete responders after chemoradiation for rectal cancer. Clin Oncol. 2011;29(35):4633-40.

36. Kuhl CK, Mielcareck P, Klaschik S, Leutner C, Wardelmann E, Gieseke J, et al. Dynamic breast MR imaging: are signal intensity time course data useful for differential diagnosis of enhancing lesions? Radiology. 1999;211:101-10.