



Tuberculosis of the Breast

Orerah GI* and Wasike RW²

¹Department of Surgery, Aga Khan University Hospital, Kenya

²Department of Head of Breast Service, Aga Khan University Hospital, Pakistan

Abstract

Tuberculosis of the breast is an extremely uncommon presentation of an otherwise common disease especially in developing countries. Clinical presentation is usually of a solitary, ill-defined, unilateral hard lump situated in the upper outer quadrant of the breast and may mimic breast carcinoma or breast abscess. Appropriate diagnosis precludes surgery as medical management suffices. We present two cases of this rare presentation that highlight the peculiarities of tuberculosis of the breast as well as a review of the literature.

Keywords: Breast disease; Breast tuberculosis

Introduction

Tuberculosis is the most widespread and persistent human infection in the world. The infection can involve any organ and mimic other illness; hence it is called the great mimicker.

Breast tuberculosis (TB) was first defined by Sir Astley Cooper in 1829 [1]. It is an extremely uncommon disease responsible for 0.025-1.04% of all breast pathologies [2]. It is an uncommon disease even in countries where the incidence of tuberculosis is high.

The disease is very rare in males. In a review by Gupta *et al.* [3] comprising 160 patients, only 6 were males. In Japan, only two cases were reported in males out of 52 cases of mammary tuberculosis over a period of 15 years from 1986 to 2000 [4].

In this article we report a case of male breast tuberculosis in a 70 year old alongside another case of a lady with tuberculous abscess.

Case Presentation

Case 1

A 70 year old man presented with a 6-month history of a lump in his left breast, associated with mild pain, fever, night sweats, loss of appetite and weight loss. He had a history of lymphoma 5 years prior (2009) for which he underwent chemotherapy and cervical lymph node dissection. There was no family history of tuberculosis.

On examination, he was in obvious respiratory distress as evidenced by inability to complete full sentences and tachypnea. He had reduced breath sounds and crepitations evident on his right mid and lower lung zones.

On breast examination, there was an obvious left breast mass, estimated 4 by 4 cm that was centrally located. The mass was firm with minimal tenderness. It was not mobile and was attached to the underlying tissues but not the overlying skin. There were no skin or nipple changes. No nipple discharge was evident.

Patient was sent for an ultra-sound guided aspiration and core needle biopsy of the mass. PCR mycobacterium identification and sensitivity was positive. With this a diagnosis of tuberculosis of the breast was made.

The patient was placed on a regimen of anti-tuberculosis quadritherapy with significant improvement a month later. He is still on treatment and follow-up.

Case 2

A 58 year old postmenopausal lady known to have diabetes and hypertension. She presented with complaints of right breast lump for six weeks. The lump had been slowly increasing in size with associated discomfort. She had nipple discharge of whitish and sometimes bloody fluid one week prior to her presentation. She had no other symptoms like fever, weight loss, loss of appetite

OPEN ACCESS

*Correspondence:

George Isaya Orerah, Department of Surgery, Aga Khan University Hospital, PO Box 62950 00200 Nairobi, Kenya, E-mail: orerahokoth@gmail.com

Received Date: 03 Aug 2016

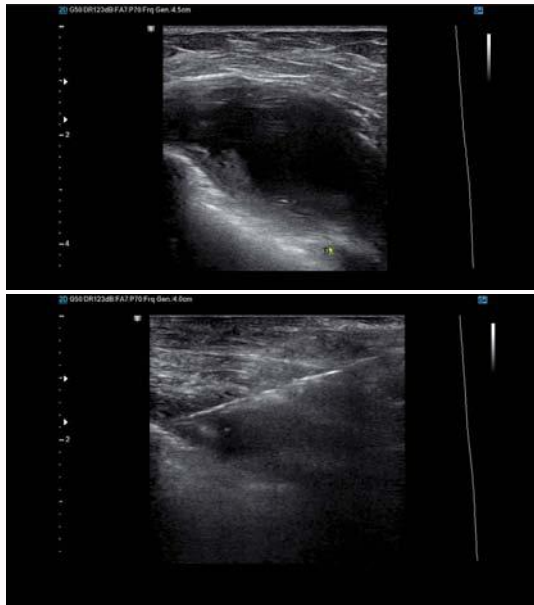Accepted Date: 25 Aug 2016

Published Date: 02 Sep 2016

Citation:

Orerah GI, Wasike RW. Tuberculosis of the Breast. *Clin Oncol.* 2016; 1: 1068.

Copyright © 2016 Orerah GI. This is an open access article distributed under the Creative Commons Attribution License, which permits unrestricted use, distribution, and reproduction in any medium, provided the original work is properly cited.



Breast ultra-sound done showed hypoechoic left breast mass 56*45*36 mm.

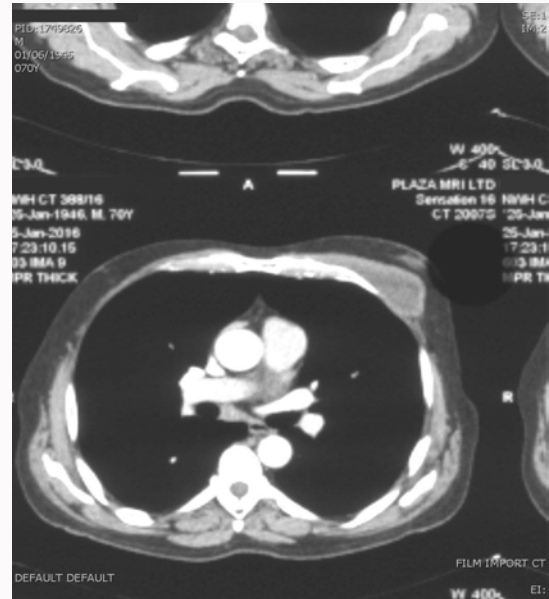
or malaise. On examination, she had a right lower inner quadrant breast mass measuring 4 by 4 cm with moderate tenderness and cystic consistency. There was nipple retraction and erythema around the mass. She did not have lymphadenopathy. Her other systemic examination were all normal. An impression of a right breast abscess was made and she was taken for an incision and drainage procedure. Samples were taken for microscopy, culture and sensitivity. The cultures turned positive for granulomatous inflammation suspicious of mycobacterium tuberculosis. She was promptly referred to the tropical medicine specialists for initiation of anti TB therapy and follow up. She also continued with dressing changes of the wound which has healed well.

Discussion

TB remains one of the leading causes of death from infectious diseases worldwide. Breast TB is one of its rarest forms [5]. The first case was recorded by Sir Astley Cooper in 1829 who called it 'scrofulous' swelling of the bosom [6]. It comprises 3% of all breast diseases and is 5 times less common than carcinoma of the breast [7]. It can be classified as primary when no demonstrable tuberculous focus exists, or it can be secondary to a lesion elsewhere in the body [8,9].

Breast TB almost exclusively affects women and occurs mostly in multiparous lactating women between the ages of 20 and 40 years [10]. This parallels the highest incidence of pulmonary tuberculosis [11]. This could be because the female breast undergoes frequent changes during the period of childbearing activity and is more susceptible to trauma and infection [12].

The disease is very rare in males. In India, a review by Gupta *et al.* [3] comprising 160 patients, only 6 were males comprising 3.75%. In Japan, only two cases were reported in males out of 52 cases of mammary tuberculosis over a period of 15 years from 1986 to 2000 [4]. In this case presentation, it occurred in a male of 70 years. Clinical presentation is usually of a solitary, ill-defined, unilateral hard lump situated in the central or upper outer quadrant [11,13-15], similar to our case. TB can also present with nipple discharge, skin thickening,



He had a needle aspirate microscopy which was negative for acid fast bacilli (ZN staining).

CT scan of the chest showed a left chest wall soft tissue mass measuring 31mm*56mm*54mm which was attached to the chest wall muscles. The overlying breast tissue was of normal attenuation.

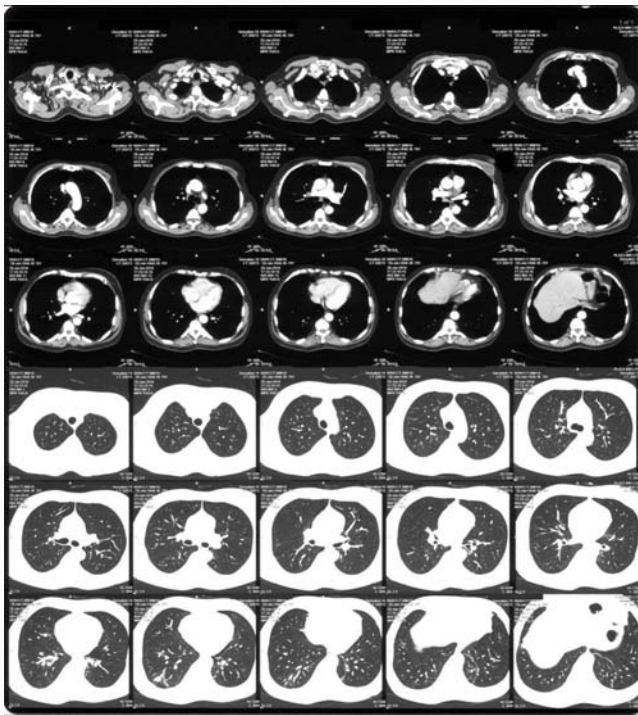
or discharging sinuses in the breast or axilla, seen in our second case presentation. The lesion may be indistinguishable from carcinoma breast, being irregular, hard, and at times, fixed to either skin or muscle or even chest wall [16]. Pulmonary involvement occurs only rarely [13]. Constitutional symptoms of fever, anorexia, failing health, weight loss and night sweats have been reported before [17] and was in our patient as well.

It is generally thought that the breast gets involved in tuberculosis by retrograde lymphatic extension from the mediastinal, axillary, and cervical region [18]. This hypothesis is supported by the involvement of axillary nodes, frequently ipsilateral nodes, in 50% to 75% of tuberculous mastitis cases [16,19].

Breast TB can mimic breast carcinoma or breast abscess, clinically and radiographically [5,15]. In our case, the lady presented with a breast abscess. Radiological imaging is not diagnostic. Mammographic imaging may show a dense tract connecting an ill-defined breast mass to an area of skin thickening and a skin bulge. Ultrasound may demonstrate a complex, predominantly cystic mass.

Diagnosis is based on identification of typical histological features or the tubercle bacilli under microscopy or culture. Shah *et al.* [20] performed AFB smear, AFB culture, and the DAT (Amplificor assay) on 1090 tissue and body fluid specimens. They found PCR test to be very useful for detecting *M. tuberculosis* in non-respiratory samples, which have lower frequency of positive AFB smear [21].

Medical therapy is the mainstay of therapy with anti-tuberculous therapy. Surgical intervention was needed in up to 14% of the patients in some series, either due to lack of response to chemotherapy or large painful ulcerative lesions involving the entire breast [22,23]. Simple mastectomy is rarely needed now-a-days and is reserved for patients with extensive disease comprising large painful ulcerated mass involving the entire breast and draining axillary lymph nodes.



The lung parenchyma appeared normal.

Conclusion

Tuberculosis of the breast is rare and tuberculosis of the male breast is not a recognised entity. The clinical and radiological feature of mammary tuberculosis can be very confusing and easily mistaken for breast cancer. Symptoms suggestive of tuberculosis warrant a biopsy to exclude possible cancer. Incorporating a highly sensitive technique like polymerase chain reaction (PCR) may be helpful in establishing the usefulness of such technology and can aid in confirming the diagnosis early [24]. The disease is curable with antitubercular drugs, and surgery is rarely required.

References

- Cooper A. Illustration of the Diseases of the Breast. Part I. London: Longman, Rees, Orme, Brown and Green; 1829. 7.
- Bani-Hani KE, Yaghan RJ, Matalka II, Mazahreh TS. Tuberculosis mastitis: a disease not to be forgotten. *Int J Tuberc Lung Dis.* 2005; 9: 920-925.
- Gupta PP, Gupta KB, Yadav RK, Agarwal D. Tuberculous mastitis: A review of seven consecutive cases. *Indian J Tub.* 2003; 50: 47-50.
- Khanna R, Prasanna G V, Gupta P, Kumar M, Khanna S, Khanna A K. Mammary tuberculosis: report on 52 cases. *Postgrad Med J.* 2002; 78: 422-424.
- Sen M, Gorpelioglu C, Bozer M. Isolated primary breast tuberculosis: report of three cases and review of the literature. *Clinics (Sao Paulo).* 2009; 64: 607-610.
- Cooper A. Illustrations of the Diseases of the Breast, Part I. London: Longman, Rees, Orme, Brown and Green; 1829. 73.
- Khanna R, Prasanna GV, Gupta P, Kumar M, Khanna S, Khanna AK. Mammary tuberculosis: report on 52 cases. *Postgrad Med J.* 2002; 78: 422-424.
- Shinde SR, Chandawarkar RY, Deshmukh SP. Tuberculosis of the breast masquerading as carcinoma: a study of 100 patients. *Word J Surg.* 1995; 19: 379-381.
- Kakker S, Kapila K, Singh MK, Verma K. Tuberculosis of the breast. A cytomorphologic study. *Acta Cytol.* 2000; 44: 292-296.
- Elsiddig KE, Khalil EA, Elhag IA, Elsafi ME, Suleiman GM, Elkhidir IM, et al. Granulomatous mammary disease: ten years' experience with fine needle aspiration cytology. *Int J Tuberc Lung Dis.* 2003; 7: 365-369.
- Jaideep C, Kumar M, Klianna AK. Male breast tuberculosis. *Postgrad Med J.* 1997; 73: 428-429.
- Raw N. Tuberculosis of the breast. *Br Med J.* 1924; 1: 657-658.
- Jalali U, Rasul S, Khan A, Baig N, Khan A, Akhter R. Tuberculous mastitis. *J Coll Physicians Surg Pak.* 2005; 15: 234-237.
- Banerjee A, Green B, Burke M. Tuberculous and granulomatous mastitis. *Practitioner.* 1989; 233: 754-756.
- Baharoon S. Tuberculosis of the breast. *Ann Thorac Med.* 2008; 3: 110.
- Shinde SR, Chandawarkar RY, Deshmukh SP. Tuberculosis of the breast masquerading as carcinoma: A study of 100 patients. *World J Surg.* 1995; 19: 379-381.
- Bouti K, Soualhi M, Marc K, Zahraoui R, Benamor J, Bourkadi JE, et al. Postmenopausal Breast Tuberculosis-Report of 4 cases. *Breast Care (Basel).* 2012; 7: 411-413.
- Sen M, Gorpelioglu C, Bozer M. Isolated primary breast tuberculosis: report of three cases and review of the literature. *Clinics (Sao Paulo)* 2009; 64: 607-610.
- Mukerjee P, George M, Maheshwari HB, Rao CP. Tuberculosis of the breast. *J Indian Med Assoc.* 1974; 62: 410-412.
- Shah S, Miller A, Mastellone A, Kim K, Colaninno P, Hochstein L, et al. Rapid diagnosis of tuberculosis in various biopsy and body fluid specimens by the AMPLICOR Mycobacterium tuberculosis polymerase chain reaction test. *Chest.* 1998; 113: 1190-1194.
- Vlasopolder F, Singer P, Roggeveen C. Diagnostic value of an amplification method (Gen-Probe) compared with that of culture for the diagnosis of tuberculosis. *J Clin Microbiol.* 1995; 33: 2699-2703.
- Tewari M, Shukla HS. Breast tuberculosis: Diagnosis, clinical features and management. *Indian J Med Res.* 2005; 122: 103-110.
- Elsiddig KE, Khalil EA, Elhag IA, Elsafi ME, Suleiman GM, Elkhidir IM, et al. Granulomatous mammary disease: Ten years experience with fine needle aspiration cytology. *Int J Tuberc Lung Dis.* 2003; 7: 365-369.
- Akçay MN, Sağlam L, Polat P, Erdoğan F, Albayrak Y, Povoski SP. Mammary tuberculosis-importance of recognition and differentiation from that of a breast malignancy: Report of three cases and review of the literature. *World J Surg Oncol.* 2007; 5: 67.