



FDG Emboli on PET/CT Scan - A Case Report

Kush Kumar*

Nuclear Medicine, Now Known as King George's Medical University, USA

Abstract

Uniform focal uptake of FDG avid abnormality in the lung without any corresponding structural lesion on CT is iatrogenic pulmonary embolism. Awareness of this very uncommon condition is essential. It is proposed to avoid direct stick and use preplaced IV cannula for injecting FDG.

Keywords: FDG; PET/CT; Pulmonary; Embolism

Case History

F-18 fluorodeoxy glucose (FDG) positron emission tomography/computed tomography (PET/CT) scan was performed in a 75 years old female to stage a squamous cell carcinoma (SCC) arising from the base of the tongue. FDG embolism was noted in the right lung with uniform distribution of FDG as determined by standardized uptake value (SUV) from edge to edge, without any corresponding CT changes. Follow-up repeat FDG PET/CT scan after a week was unremarkable.

Imaging Findings

FDG PET/CT revealed a small, rounded, well defined focal lesion with sharp borders in the right lung measuring 15.6 x 14.2 mm in maximum transverse diameter with SUV of 32.3 throughout the lesion from edge to edge, without any corresponding CT abnormality neither noted on pre PET dedicated CT evaluation of the chest nor on co-registered fused PET/CT images obtained during the PET study (Figure 1).

Discussion

FDG embolism is an uncommon but important condition as failure to diagnose may have unexpected catastrophic consequences. Sporadic cases have been described in the literature

OPEN ACCESS

*Correspondence:

Kush Kumar, MD, Nuclear Medicine,
Now Known as King George's Medical
University, 100 Parks Ridge Rd, Dublin,
GA-3102,1 USA, Tel: (478) 919 7813;
E-mail: kushkumar8@hotmail.com

Received Date: 08 May 2016

Accepted Date: 19 May 2016

Published Date: 25 May 2016

Citation:

Kush Kumar. FDG Emboli on PET/
CT Scan - A Case Report. Clin Oncol.
2016; 1: 1003.

Copyright © 2016 Kush Kumar. This is
an open access article distributed under
the Creative Commons Attribution
License, which permits unrestricted
use, distribution, and reproduction in
any medium, provided the original work
is properly cited.

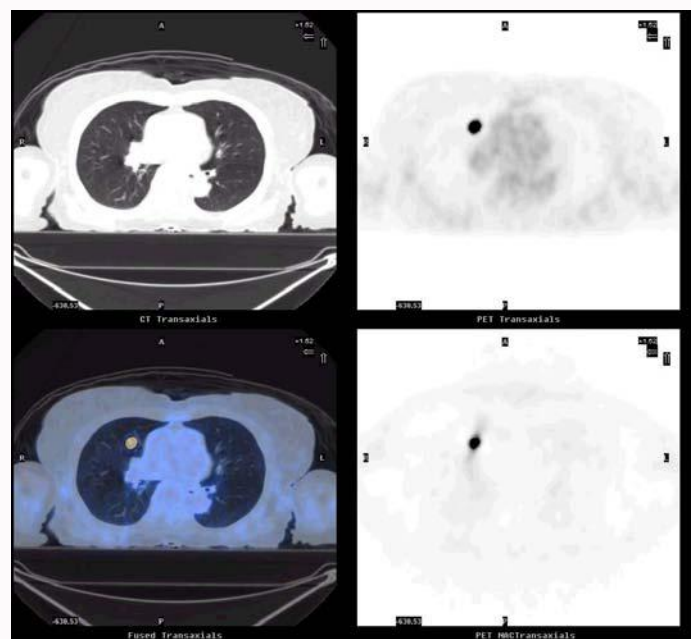


Figure 1: A 75 year-old-female with SCC from the base of the tongue. PET+CT evaluation showed focal FDG-18 uptake with intense activity without corresponding CT abnormality. (Upper right = attenuation corrected (AC), Lower right = non attenuation corrected, Upper left = CT scan of the corresponding site, lung window and Lower left = PET, AC +CT fused image).

sporadically from time to time [1-8] but it is difficult to mention exact incidence of this very unusual & uncommon condition. Focal intense activity with unusually high SUV distributed uniformly throughout the lesion from edge to edge, without corresponding CT abnormality should raise the suspicion. Exact anatomical localization of abnormal PET finding by analyzing PET+CT fused images is of tremendous help. Follow-up scan must not show the lesion. Follow-up FDG PET/CT scan must be unremarkable. Kavanagh et al. [5] felt that a part of the administered FDG likely got clumped with platelet aggregate during administration, forming an embolus which traveled to the lung. We agree with the possibility suggested by Hany et al [3] that probably it is due to the clotting of the blood in the FDG loaded syringe while blood was withdrawn to confirm the placement of the needle in to the lumen of the vein for direct stick. The clot got labeled by the FDG in the in the lumen of the needle or the barrel of the syringe and subsequently got pushed as an embolus. With this probable hypothesis, it is proposed that FDG should be injected with a steady pace, without any delay, once it is confirmed that the tip of the needle is in the vein. It is rather recommended to avoid direct stick and use preplaced intra venous (IV) cannula for injecting FDG.

Conclusion

FDG embolism is an uncommon but important iatrogenic condition as failure to diagnose may have unexpected catastrophic consequences. Awareness of this uncommon condition is essential. It is recommended to avoid direct stick and use preplaced IV cannula for injecting FDG.

References

1. Fathinul Fikri A, Lau W. An intense 18F-FDG pulmonary microfocus on PET without detectable abnormality on CT: A manifestation of an iatrogenic FDG pulmonary embolus. *Biomed Imaging Interv J*. 2010; 6: 37.
2. Ha JM, Jeong SY, Seo YS, Kwon SY, Chong A, Oh JR, et al. Incidental focal F-18 FDG accumulation in lung parenchyma without abnormal CT findings. *Ann Nucl Med*. 2009; 23: 599–603.
3. Hany TF, Heuberger J, von Schulthess GK : Iatrogenic FDG foci in the lungs : a pitfall of PET image interpretation. *Eur Radiol*. 2003; 13: 2122-2127.
4. Karantanis D, Subramaniam RM, Mullan BP, Peller PJ, Wiseman GA. Focal F-18 fluoro-deoxy-glucose accumulation in the lung parenchyma in the absence of CT abnormality in PET/CT. *J Comput Assist Tomogr*. 2007; 31: 800–805.
5. Kavanagh PV, Stevenson AW, Chen MY, Clark PB: Nonneoplastic diseases in the chest showing increased activity. *Am J Radiology*, 2004, 183: 1133- 1141.
6. Mester U, Even-Sapir E. Increased (18) F-fluorodeoxyglucose uptake in benign, nonphysiologic lesions found on whole-body positron emission tomography/computed tomography (PET/CT): Accumulated data from four years of experience with PET/CT. *Semin Nucl Med*. 2007; 37: 206–222.
7. Schreiter N, Nogami M, Buchert R. Pulmonary FDG uptake without a CT counterpart: A pitfall in interpreting PET/CT images. *Acta Radiol*. 2011; 52: 513–515.
8. Tokmak, H Focal FDG Uptake in Lung Parenchyma Without Structural Alterations on CT. *World J Nucl Med*. 2013 Jan-Mar; 12 : 38–40.