



Minimally Invasive Non-Endoscopic Thyroidectomy with a Low Anterior Cervical Incision

Nan Lin¹, Lihui Yu², Jun Ma³ and Yu Wang^{1*}

¹Department of General Surgery, Xiamen University, China

²Department of General Surgery, Fujian Medical University, China

³Department of Thoracic Surgery, Air Force Military Medical University Xi'an, China

Abstract

Background: To provide a preliminary comparison between Minimally Invasive Non-endoscopic Thyroidectomy with a low anterior cervical incision (L-MINT) and MIVAT.

Methods: We retrospectively examined the medical records of 89 patients receiving L-MINT and 102 patients receiving Minimally Invasive Video-Assisted Thyroidectomy (MIVAT). Parameters included: demographic and baseline information, incision length, operation time and bleeding, postoperative pain, drainage, cosmetic satisfaction and complications.

Results: Patients receiving L-MINT vs. MIVAT did not differ in age, gender, nodule diameter (2.35 ± 1.03 vs. 2.69 ± 1.11 cm), and pathological type (follicular tumors 14.6% vs. 17.6%, nodular goiter 81.9% vs. 75.5%). Patients receiving L-MINT had significantly shorter operation time (43.4 ± 14.1 vs. 67.5 ± 19.0 min; $p < 0.05$). L-MINT and MIVAT did not differ in incision length (2.20 ± 0.45 vs. 1.97 ± 0.32 cm), postoperative pain (VAS score of 3.68 ± 0.84 vs. 3.90 ± 1.00 at 12 h and 1.54 ± 0.64 vs. 1.59 ± 0.63 at 1w) and cosmetic satisfaction (8.08 ± 1.08 vs. 8.06 ± 0.98 at 24 h and 8.94 ± 0.79 vs. 9.03 ± 0.59 at 12w), and complications.

Conclusion: L-MINT is as safe as MIVAT, but requires shorter surgical time than MIVAT. Considering the requirement for less equipment, we recommend L-MINT as an alternative to MIVAT, particularly in less developed parts of the world.

Keywords: Low incision; Microsurgery; MINT; MIVAT; Thyroidectomy

OPEN ACCESS

*Correspondence:

Yu Wang, Department of General Surgery, 900 Hospital of the Joint Logistics Team, Dongfang Hospital, Xiamen University, Fuzhou, Fujian, 350025, China,
E-mail: flyfishwang@hotmail.com

Received Date: 27 Jan 2021

Accepted Date: 23 Feb 2021

Published Date: 26 Feb 2021

Citation:

Lin N, Yu L, Ma J, Wang Y. Minimally Invasive Non-Endoscopic Thyroidectomy with a Low Anterior Cervical Incision. *Clin Oncol.* 2021; 6: 1776.

Copyright © 2021 Yu Wang. This is an open access article distributed under the Creative Commons Attribution License, which permits unrestricted use, distribution, and reproduction in any medium, provided the original work is properly cited.

Introduction

Thyroidectomy through the Kocher's incision was once regarded as the standard surgical treatment for thyroid goiter and tumors [1]. A major disadvantage of this surgery is the prominent scar in the neck and associated psychological and social problems. In recent decades, Minimally Invasive Thyroidectomy (MIT) has emerged and evolved considerably. MIT mainly includes endoscopic thyroidectomy with or without CO₂ insufflation [2], endoscope-assisted thyroidectomy (via anterior cervical approach or less conspicuous breast areola, axillary approach or submaxillary approach) [3,4], Minimally Invasive Non-endoscopic Thyroidectomy (MINT), robot-assisted thyroidectomy [5,6] and the conventional thyroidectomy with a small incision [7,8]. To a certain extent, these new surgical approaches have improved the cosmetic outcome after surgery. Endoscopic thyroidectomy including robot-assisted surgery creates a hidden incision, but requires complicated procedure and sometimes large or even multiple subcutaneous tunnels [9]. Minimally Invasive Video-Assisted Thyroidectomy (MIVAT) was initially developed by Miccoli from the Pisa University and has promising cosmetic outcomes as well as relatively mild postoperative pain. It is now regarded as the standard MIT [10-13]. However, this surgery requires extensive training as well as relatively long operation time. Surgical equipment is also more expensive for MIVAT [9].

MINT using ultrasonic shears has been increasingly used in recent years, and could be carried out in several approaches. Under the anterior cervical approach [14,15], a 2.5 cm incision is usually placed in the closest skin crease above the isthmus, and near the cricoid cartilage. This approach is suitable to deal with the complex structure of the upper pole of thyroid. Under the lateral approach, a 2.5 cm incision is placed in the skin crease 2 cm above the sternum nodule in lateral neck. Such an approach is not suitable for bilateral thyroid nodules and nodules >3 cm in maximum diameter [16]. Under the higher approach, a 2.5 cm incision is placed directly over the thyroid nodule. Due to the relatively high position of the incision, all these approaches have less-than-desirable cosmetic

results [17]. In our clinical practice during the past few years, we adopted a low incision for MINT. This approach yielded satisfactory cosmetic results and enabled bilateral thyroidectomy. In the current retrospective study, we compared L-MINT with MIVAT.

Methods

This study was approved by the ethics committee of 900 Hospital of the joint logistics team Command (protocol #: 2007127). L-MINT and MIVAT were performed by the same team of surgeons during a period from January 2008 to January 2010.

Patient selection

All patients were suspected of having a benign thyroid disease, and received routine auxiliary examination, including color-Doppler ultrasound, cervical computerized tomography (CT; to eliminate sub-sternal thyroid goiter), fine-needle aspiration, and blood test for FT3, FT4, TSH, thyroglobulin antibodies and thyroid microglobulin antibodies. Vocal cord mobility was examined with laryngoscopy prior to the surgery. For inclusion in data analysis, all cases must met all following conditions: (1) benign lesion, as reflected by cytology and clinical evidence, for example, follicular tumors (except for malignant nodules), nodular goiter and thyroiditis; (2) maximum nodule diameter <3.5 cm; (3) no evidence for hyperthyroidism; (4) unilateral thyroid volume <15 ml. Patients with the following conditions were not included in data analysis: (1) past history of cervical surgery; (2) past history of head and neck irradiation. A total of 191 cases were included in this study (L-MINT: 89 cases; MIVAT: 102 cases). The choice of L-MINT vs. MIVAT was not primarily based on physician discretion and patient will, and not randomized. Surgery of the both types was conducted under general anesthesia. All patients provided informed consent for publication of this manuscript.

The extent of thyroid gland removal (e.g., bilateral near-total thyroidectomy, bilateral subtotal thyroidectomy, unilateral near-total thyroidectomy or unilateral subtotal thyroidectomy) was based on the American Thyroid Association guidelines for the management of adult patients [18,19] and is determined by the characteristics and location of intraoperative goiter. The pathology examination was performed independently by the two pathologists for all samples.

Instruments

L-MINT: ultrasonic shears produced by Ethicon Endo-Surgery (5-mm diameter, 55.5-kHz frequency, amplitude: 10 μ m to 50 μ m, output power setting for 3 or 5 shift) and two pairs of tissue forceps and one pair of dressing forceps (Figure 1). Key instruments were a set of retractors made from titanium brain spatulas that could be modified during the surgery to fit the operation field (Figure 2).

MIVAT: a 30-cm long, 5-mm thick 30° endoscope, a 21-cm aspirator with separate orifice and short blunt, a pair of toothed fine ear forceps with 12.5-cm effective operational length, a conventional goiter retractor, a 12-cm double small hook, and a pair of 12.5-cm straight operating scissors.

L-MINT

A cervical incision of 2.5 cm to 3.0 cm was made in the midline, approximately 1.5 cm to 2.0 cm above the sterna notch, and conforming to a preexisting skin crease. The incision was made with the neck mildly extended. Subcutaneous tissues and the platysma muscle were carefully separated starting from the upper edge of incision to the lower edge of thyroid cartilage. The plane between the strap muscle and the thyroid gland was established with a

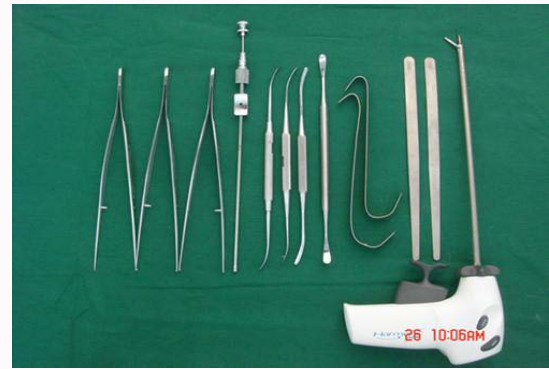

Figure 1: Major instruments for L-MINT.

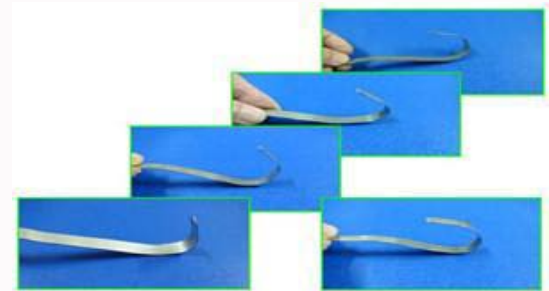


Figure 2: Improvised retractors (using a brain spatula) to fit the operation field.

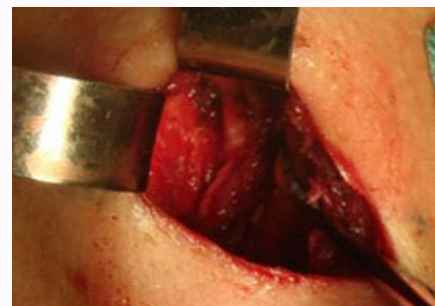

Figure 3: The recurrent laryngeal nerve is identified, typically in the tacheoesophageal groove.

combination of serial retraction and blunt dissection, and with the aid of a detacher. For bilateral subtotal thyroidectomy, the recurrent laryngeal nerve was first identified before dissecting the backside of thyroid gland (Figure 3). All removed tissues were immediately sent for pathological examination (Figure 4). When came across thyroid carcinoma had invade the capsule, we would perform a pretracheal lymph node dissection. The anterior cervical muscle was closed with a simple continuous suture using a 5-0 vicryl suture. The skin was closed with an intradermic suture. A drainage tube with negative pressure suction was placed (Figure 5).

MIVAT is conducted in accordance with Miccoli surgical procedures.

Data extraction

The following data were extracted: incision length, operation time, operation blood loss, and 12-h postoperative drainage. Postoperative complications included wound hematoma, temporary and permanent injury to the laryngeal recurrent nerve (as reflected by laryngoscopy

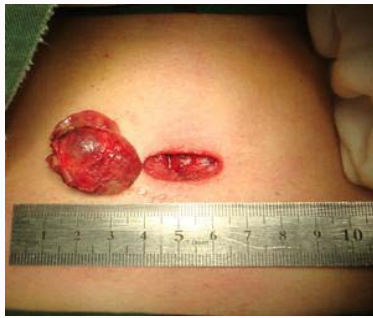

Figure 4: Thyroid lamina delivered through an incision of about 2.5 cm.

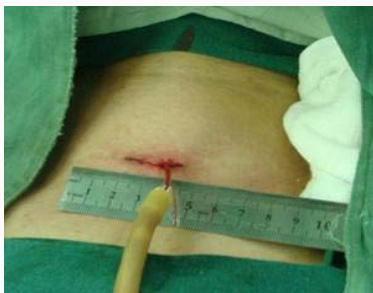

Figure 5: A drainage tube with negative pressure suction after the surgery.

at 4 weeks after operation), and parathyroid function (as reflected by serum calcium at 12-h and 1-w after operation). Postoperative pain was routinely assessed in our clinical practice using a 10-point Visual Analogue Scale (VAS) at 12-h [20] and 1-w. Cosmetic satisfaction was examined and recorded using a 10-point analogue scale at 24-h 12-w by the patients. Hospital stay was also extracted.

Statistical analysis

All continuous variables are expressed as mean ± standard deviation and analyzed with Student’s t-test. Categorical variables were analyzed using the chi-square test. All statistical analyses were carried out using SPSS, release 13.0. The level of significance was set at $p < 0.05$.

Results

Demographics, nodule size and position were comparable between the patients receiving L-MINT vs. MIVAT (Table 1). The incision length did not differ between L-MINT and MIVAT (2.20 ± 0.45 vs. 1.97 ± 0.32 cm). The lesion types included thyroid follicular tumors, nodular goiter and hyperthyroidism, and did not differ between L-MINT and MIVAT. The thyroid volume and maximal nodule diameter, as reflected by ultrasonography, also did not differ between the two groups (Table 2). Incision length and blood loss during the surgery and postoperative drainage volume, as well as postoperative pain and cosmetic satisfaction also did not differ between the two groups (Table 3).

After operation, one patient in MINT group and two patients in MIVAT group occurred wound hydrops. No secondary bleeding occurred in either group. Temporary hoarseness was noticed in four patients in the L-MINT group and three patients in the MIVAT group, but mitigated without specific treatment, Vocal cord of these patients were normal by laryngoscopy. Temporary hypocalcemia was noticed in three cases after L-MINT and one case after MIVAT, but all recovered upon symptomatic treatment. The operative time was

Table 1: Patient demographics, nodule size and lesion location.

	MIVAT (102)	L-MINT (89)	p
Age (y)	46.23 ± 11.65	45.85 ± 11.53	>0.05
Gender			>0.05
Male	17	11	
Female	85	78	
Nodule size (cm)	2.69 ± 1.11	2.35 ± 1.03	>0.05
Position			>0.05
Unilateral	68	61	
Bilateral	34	28	

Table 2: Operation mode and pathological type in patients treated with L-MINT vs. MIVAT.

	MIVAT	L-MINT	p
Type of surgery			>0.05
unilateral subtotal thyroidectomy	49	43	
unilateral near-total thyroidectomy	19	18	
bilateral subtotal thyroidectomy	25	22	
bilateral near-total thyroidectomy	9	6	
Histologic diagnosis			>0.05
follicular tumors	19	13	
toxic nodular goiter	77	73	
thyroiditis	6	3	

Table 3: Incision length, operation time, bleeding, postoperative pain, and cosmetic satisfaction in patients treated with MIVAT and MINT.

	MIVAT	L-MINT	p
Incision length (cm)	1.97 ± 0.32	2.20 ± 0.45	>0.05
Operative time (min)	67.5 ± 19.0	43.4 ± 14.1	<0.05
Operation blood loss (ml)	11.96 ± 6.21	10.61 ± 4.28	>0.05
Postoperative drainage volume (ml)			>0.05
0~12 h	9.01 ± 2.60	10.47 ± 3.39	
Pain scores			>0.05
12 h	3.90 ± 1.00	3.68 ± 0.84	
1 w	1.59 ± 0.63	1.54 ± 0.64	
Patient Scar Assessment Scale (PSAS)			>0.05
24 h	8.06 ± 0.98	8.08 ± 1.08	
12 w	9.03 ± 0.59	8.94 ± 0.79	

significantly shorter with L-MINT (43.4 ± 14.1 min) vs. MIVAT (67.5 ± 19.0 min).

Discussion

The results from the current study showed that L-MINT is comparable to MIVAT in postoperative complications and cosmetic satisfaction. However, L-MINT requires shorter operation time, and thus may have some advantage due to shorter duration of anesthesia [21,22]. The incision length was not statistically different between L-MINT and MIVAT, and conformed to the criteria of MIT (<3 cm) [23]. O’Connell et al. [24] reported no difference in cosmetic satisfaction between MIT and conventional thyroidectomy at 8 months after the surgery, but such an opinion is not consistent with our clinical experience. The results from the current study showed promising cosmetic satisfaction after both L-MINT and MIVAT.

One of the possible contributing factors for such results is the use ultrasonic shears, and thus less foreign objects (e.g., suture and titanium clamp), which in turn could affect cosmetic appearances [25-27]. With the magnification and lighting of an endoscopic, MIVAT provides a clear view of the surgical field. However, maneuvering the endoscope together with other surgical instruments in a confined space is highly demanding, and requires extensive training. Last because of perfecting the preoperative color Doppler ultrasound, fine needle aspiration and other relevant examinations, the patients in both groups were all diagnosed with benign thyroid nodules, and no thyroid cancer was found by postoperative pathology.

In order to expose thyroid gland sufficiently, a lateral or high incision is often needed, but with less than optimal cosmetic satisfaction [9]. In addition, lateral incision is evidently not appropriate for bilateral thyroidectomy. Our impression of using MINT with a low incision (L-MINT) for several years is also confirmed by this retrospective study: L-MINT could decrease operation time without affecting postoperative complications.

Major challenges of MINT included sufficient exposure of the surgical field and protection of important tissues. In our practice, we “manufactured” retractors by folding titanium alloy brain spatulas based on the depth of the neck space to expose the entire thyroid gland. All small blood vessels and tissues are separated by the detacher, and clipped with ultrasonic shears. In our experience, surgeons could master the techniques with reasonable training.

All together, this surgery team conducted 437 cases of thyroidectomy during the 2-year study period. Ninety-three cases of malignant tumors were not included in this report. One hundred forty three cases were not included for other reasons (e.g., incomplete data). Also, the assignment of the patients was not random (but mostly based on patient choice). These represent issues that must be considered when interpreting the results. Nevertheless, this study was conducted in the “real world”, and thus may have unique value.

Conclusion

L-MINT is a promising alternative to MIVAT, particularly in the parts of the world where financial issue is a major concern.

Acknowledgement

The study was supported by a key project of the Social Development of Fujian Province, China (No.: 2012D020).

References

- Felix C, Russell JO, Juman S, Medford S. Cervical scar satisfaction post conventional thyroidectomy. *Gland Surg.* 2019;8(6):723-8.
- Gagner M, Inabnet WR. Endoscopic thyroidectomy for solitary thyroid nodules. *Thyroid.* 2001;11(2):161-3.
- Sasaki A, Nakajima J, Ikeda K, Otsuka K, Koeda K, Wakabayashi G. Endoscopic thyroidectomy by the breast approach: A single institution's 9-year experience. *World J Surg.* 2008;32(3):381-5.
- Choe J, Kim SW, Chung K, Park KS, Han W, Noh DY, et al. Endoscopic thyroidectomy using a new bilateral axillo-breast approach. *World J Surg.* 2007;31(3):601-6.
- Kang S, Jeong JJ, Yun J, Sung TY, Lee SC, Lee YS, et al. Robot-assisted endoscopic surgery for thyroid cancer: experience with the first 100 patients. *Surg Endosc.* 2009;23(11):2399-406.
- Lee KE, Kim E, Koo DH, Choi JY, Kim KH, Youn YK. Robotic thyroidectomy by bilateral axillo-breast approach: Review of 1,026 cases and surgical completeness. *Surg Endosc.* 2013;27(8):2955-62.
- Dieter RA. Minimally invasive nonendoscopic thyroid surgery. *J Am Colleg Surg.* 2001;193(5):585.
- Palazzo FF, Sywak MS, Sidhu SB, Delbridge LW. Safety and feasibility of thyroid lobectomy *via* a lateral 2.5-cm incision with a cohort comparison of the first 50 cases: Evolution of a surgical approach. *Langenbecks Arch Surg.* 2005;390(3):230-5.
- Linos D. Minimally invasive thyroidectomy: A comprehensive appraisal of existing techniques. *Surgery.* 2011;150(1):17-24.
- Wu C, Yang L, Kuo S. Comparison of video-assisted thyroidectomy and traditional thyroidectomy for the treatment of papillary thyroid carcinoma. *Surg Endosc.* 2010;24(7):1658-62.
- Miccoli P, Fregoli L, Rossi L, Papini P, Ambrosini CE, Bakkar S, et al. Minimally Invasive Video-Assisted Thyroidectomy (MIVAT). *Gland Surg.* 2020;9(S1):S1-5.
- Scerrino G, Melfa G, Raspanti C, Rotolo G, Salamone G, Licari L, et al. Minimally invasive video-assisted thyroidectomy: Analysis of complications from a systematic review. *Surg Innov.* 2019;26(3):381-7.
- Miccoli P, Biricotti M, Matteucci V, Ambrosini CE, Wu J, Materazzi G. Minimally invasive video-assisted thyroidectomy: Reflections after more than 2400 cases performed. *Surg Endosc.* 2016;30(6):2489-95.
- Sywak MS, Yeh MW, McMullen T, Stalberg P, Low H, Alvarado R, et al. A randomized controlled trial of minimally invasive thyroidectomy using the lateral direct approach versus conventional hemithyroidectomy. *Surgery.* 2008;144(6):1016-21; discussion 1021-2.
- Cavicchi O, Piccin O, Ceroni AR, Caliceti U. Minimally invasive nonendoscopic thyroidectomy. *Otolaryngol Head Neck Surg.* 2006;135(5):744-7.
- Sackett WR, Barraclough BH, Sidhu S, Reeve TS, Delbridge LW. Minimal access thyroid surgery: Is it feasible, is it appropriate? *ANZ J Surg.* 2002;72(11):777-80.
- Sackett WR, Barraclough B, Reeve TS, Delbridge LW. Worldwide trends in the surgical treatment of primary hyperparathyroidism in the era of minimally invasive parathyroidectomy. *Arch Surg.* 2002;137(9):1055-9.
- Bodian CA, Freedman G, Hossain S, Eisenkraft JB, Beilin Y. The visual analog scale for pain: Clinical significance in postoperative patients. *Anesthesiology.* 2001;95(6):1356-61.
- Haugen BR, Alexander EK, Bible KC, Doherty GM, Mandel SJ, Nikiforov YE, et al. 2015 American Thyroid Association management guidelines for adult patients with thyroid nodules and differentiated thyroid cancer: The American Thyroid Association guidelines task force on thyroid nodules and differentiated thyroid cancer. *Thyroid.* 2016;26(1):1-133.
- Patel KN, Yip L, Lubitz CC, Grubbs EG, Miller BS, Shen W, et al. Executive summary of the American Association of Endocrine Surgeons guidelines for the definitive surgical management of thyroid disease in adults. *Annals of Surgery.* 2020;271(3):399-410.
- Boruk M, Chernobilsky B, Rosenfeld RM, Har-El G. Age as a prognostic factor for complications of major head and neck surgery. *Arch Otolaryngol Head Neck Surg.* 2005;131(7):605-9.
- Timon CI, Hirani SP, Epstein R, Rafferty MA. Investigation of the impact of thyroid surgery on vocal tract steadiness. *J Voice.* 2010;24(5):610-3.
- Brunaud L, Zarnegar R, Wada N, Ituarte P, Clark OH, Duh QY. Incision length for standard thyroidectomy and parathyroidectomy: When is it minimally invasive? *Arch Surg.* 2003;138(10):1140-3.
- O'Connell DA, Diamond C, Seikaly H, Harris JR. Objective and subjective scar aesthetics in minimal access vs conventional access parathyroidectomy and thyroidectomy surgical procedures: A paired cohort study. *Arch Otolaryngol Head Neck Surg.* 2008;134(1):85-93.

25. Miccoli P, Materazzi G, Miccoli M, Frustaci G, Fosso A, Berti P. Evaluation of a new ultrasonic device in thyroid surgery: Comparative randomized study. *Am J Surg.* 2010;199(6):736-40.
26. Cirocchi R, D'Ajello F, Trastulli S, Santoro A, Rocco GD, Vendettuoli D, et al. Meta-analysis of thyroidectomy with ultrasonic dissector versus conventional clamp and tie. *World J Surg Oncol.* 2010;8(1):112.
27. D'Ajello F, Cirocchi R, Docimo G, Catania A, Ardito G, Rosato L, et al. Thyroidectomy with ultrasonic dissector: A multicentric experience. *G Chir.* 2010;31(6-7):289-92.