



## Long Term Outcomes of Stereotactic Body Radiotherapy as a Bridge to Liver Transplant for Hepatocellular Carcinoma Patients

Jay C Shiao<sup>1</sup>, Richard L Crownover<sup>2</sup>, Alonso N Gutierrez<sup>3</sup>, Nikos Papanikolaou<sup>2</sup>, Jorge Lopera<sup>4</sup>, Glenn A Half<sup>5</sup>, William K Washburn<sup>6</sup>, Abhilasha Patel<sup>7</sup>, Alan Zhu<sup>8</sup>, Anna Harris<sup>9</sup>, Mark Bonner<sup>2</sup> and Zheng Shi<sup>2\*</sup>

<sup>1</sup>Department of Radiation Oncology, University of Colorado Anschutz Medical Campus, USA

<sup>2</sup>Department of Radiation Oncology, Mays Cancer Center, UT Health San Antonio MD Anderson Cancer, USA

<sup>3</sup>Department of Radiation Oncology, Miami Cancer Institute, Baptist Hospital, USA

<sup>4</sup>Department of Radiology, UT Health San Antonio, USA

<sup>5</sup>UT Transplant Center, Mays Cancer Center, UT Health San Antonio MD Anderson Cancer Center, USA

<sup>6</sup>Transplant Center, Ohio State University, USA

<sup>7</sup>Department of Radiation Oncology, Texas Oncology-Houston Willowbrook, USA

<sup>8</sup>Premed Program, Washington University in St. Louis, USA

<sup>9</sup>Department of Radiation Oncology, Tanner Medical Center, USA

### Abstract

**Purpose:** To determine the radiographic and pathologic response of Hepatocellular Carcinoma (HCC) lesions treated with Stereotactic Body Radiotherapy (SBRT) in a series of liver transplant candidates.

**Methods:** We retrospectively reviewed 17 liver transplant candidates from December 2008 to December 2013 with discrete HCC lesions treated with SBRT. Lesions were reviewed for Maximum Tumor Dimension (MTD) at time of simulation, at last imaging before transplant, and in the explanted liver. Radiographic LC of the treated lesion was defined as stable or decreasing MTD on imaging as evaluated by RECIST 1.1. Pathologic Control (PC) was defined as stable to decreased size in MTD and/or no viable tumor present.

**Results:** All patients were male; median age of 57 years. Among the 12 patients transplanted, there were 17 lesions treated. Median MTD was 3.6 cm (1.1 cm to 6.1 cm). Median time to transplant from radiation treatment was 9 months (2-18 months). Eight lesions (47%) had no evidence of viable tumor on pathology. Radiographic LC and PC were achieved in all 17 lesions. The median follow-up was 75.6 months and the 5-year overall survival was 58.3%. All patients had no evidence of disease. Of the 5 candidates that received SBRT and did not make it to transplant, all lesions had LC. No patient experienced radiation-induced liver disease.

**Conclusion:** SBRT for HCC lesions in transplant candidates is an effective means of LC with successful bridging to transplant. Radiologic assessment subsequent to SBRT correlated with pathologic findings after transplant.

**Keywords:** Stereotactic radiotherapy; Hepatocellular carcinoma; Liver transplant; Bridging therapy

### Introduction

Primary liver cancer is the third most common cause of cancer death in the world [1]. Hepatocellular carcinoma (HCC) accounts for 85% to 90% of primary liver cancers. Diagnostically, HCC is determined with classic imaging characteristics of arterial-phase enhancement and venous-phase “washout” [2]. Patients with HCC lesions traditionally are considered for local treatment including Transarterial Chemoembolization (TACE), surgical resection, Yttrium-90 beads, and/or Radiofrequency Ablation (RFA). The ultimate goal in those patients who are suitable surgical candidates is Orthotopic Liver Transplant (OLT) to provide a chance of cure. In an effort to prevent

### OPEN ACCESS

#### \*Correspondence:

Zheng Shi, Department of Radiation Oncology, Mays Cancer Center, UT Health San Antonio MD Anderson Cancer Center, 7979 Wurzbach Rd, MC 7889, San Antonio, Texas, USA, Tel: +1-78229-4427; +1-210-450-1727; +1-210-237-2402; Fax: +1-210-450-5085; E-mail: shiz@uthscsa.edu

**Received Date:** 23 Nov 2019

**Accepted Date:** 06 Feb 2020

**Published Date:** 12 Feb 2020

#### Citation:

Shiao JC, Crownover RL, Gutierrez AN, Papanikolaou N, Lopera J, Half GA, et al. Long Term Outcomes of Stereotactic Body Radiotherapy as a Bridge to Liver Transplant for Hepatocellular Carcinoma Patients. Clin Oncol. 2020; 5: 1683.

**Copyright** © 2020 Zheng Shi. This is an open access article distributed under the Creative Commons Attribution License, which permits unrestricted use, distribution, and reproduction in any medium, provided the original work is properly cited.

unnecessary OLT to those at high risk of distant recurrence or surgical complications, criteria have been established for guiding candidacy for OLT [3]. This includes the size of a single liver HCC lesion as being less than 5 cm or up to three lesions with none being more than 3 cm and no evidence of extra-hepatic disease, although some United Network for Organ Sharing (UNOS) regions have expanded size criteria. Once these radiographic criteria have been met along with a multitude of additional tests to ensure surgical candidacy, the patient is placed on a list for OLT with priority based upon a Model for End-stage Liver Disease (MELD) score [4].

However, the use of hepatic transplantation for HCC is hampered by a shortage of donor organs which results in long waits on a transplant list [5]. Patients may be delisted as a result of new illnesses or co-morbidities, or asymptomatic increase in size or number of HCC lesions that develop while waiting. In an effort to prevent this, bridging local therapy is administered to keep the existing HCC lesion(s) from growing in size. Different modalities can be utilized as discussed above, each with its own caveats for patient selection and anticipated effectiveness [6]; for example, OLT candidates with elevated bilirubin may not be eligible for TACE, and those with lesions that are exophytic or adjacent to high flow vessels may not be appropriate for RFA.

Historically, radiotherapy was not an attractive option for local therapy of liver lesions, due to poor patient tolerance and concern for Radiation-Induced Liver Disease (RILD). With improved motion management, conformal radiation delivery techniques, and better verification imaging, the efficacy and toxicity profile of radiation for liver tumors has become much more favorable. Stereotactic Body Radiotherapy (SBRT) has been demonstrated to be safely effective in liver metastases in RTOG 0438 study [7]. SBRT provides a noninvasive treatment alternative for malignant liver lesions when more common treatment modalities cannot be applied [8].

In this retrospective analysis, it is of interest if OLT candidates sustain Local Control (LC) of HCC lesions treated by SBRT. This was assessed by serial imaging at 1 and 3 months subsequent to SBRT and in 3 month intervals, thereafter, until the date of OLT. Following OLT, pathology reports were reviewed to determine if there were any viable tumor cells in the liver lesions targeted by SBRT; also, dimensions of the liver lesion by pathology report was compared to that of the liver lesion prior to SBRT to determine if there was agreement with the radiographic response seen prior to OLT.

## Methods and Materials

### Patients, tumors and outcome measures

From December 2008 to December 2013, SBRT was delivered to 17 OLT candidates with 1 to 3 liver lesions less than 6 cm in largest dimension. All patients were evaluated by a multidisciplinary tumor board and treated per the consensus recommendation. Patients were listed for liver transplantation at the University Hospital. In general, patients with HCC were eligible for transplant with up to 3 lesions where the sum of the largest dimensions was  $\leq 9$  cm and no single lesion was  $>6$  cm in greatest dimension (UNOS Region 4 HCC size criteria for transplant).

Radiographic LC of the treated lesion was defined as stable or decreasing unidirectional tumor length on imaging with either CT or MRI of the liver, as compared to CT imaging performed at the time of simulation, defined by the RECIST 1.1 criteria. Pathologic Control (PC) was defined as stable to decreased size in MTD and/or

any size with no viable tumor present in the specimen as indicated in the pathology report. Acute and long-term toxicities were graded according to the Common Terminology Criteria for Adverse Events v4.0.

### SBRT planning and treatment

To ensure reproducible treatment, patients were placed supine with arms above the head in a custom immobilization device. Abdominal compression (ProLok System, CIVCO Medical) was used to limit respiratory excursion and subsequent target volume motion and achieve high-fidelity intra-fraction and inter-fraction reproducibility [9]. All patients underwent a contrast-enhanced, triple-phased CT with a 2.50-mm slice thickness as the basis for target and normal structure delineation. Treatment was delivered using either the Tomotherapy Hi-Art or Novalis Tx delivery system to provide volumetric image guidance for each fraction. The liver, small bowel, kidneys, lung bases, stomach, heart, and spinal canal were contoured. The small bowels were contoured as a “bowel bag” that encompassed the volume accessible to this mobile organ but the duodenum was contoured as a distinct structure owing to its more limited mobility and particular sensitivity to radiation. The Gross Tumor Volume (GTV) was defined as the lesion which enhanced on the arterial phase and washed out on the venous phase. The Clinical Target Volume (CTV) was typically generated by expanding the GTV by 0.5 cm without extension outside the liver. In cases where the lesion to be treated was a recurrence that had been treated previously with TACE or RFA, we included the RFA cavity or residual radiographic abnormality as part of the CTV. The Planning Target Volume (PTV) was created by expanding the CTV by an additional 3 mm to 5 mm.

Normal-tissue dose constraints were followed according to AAPM TG-101 [10]. The earliest patients in our series were treated prior to that publication and the values we had been using in-house were slightly more conservative. Prior to the publication, we had required that at least 700 cc of the liver receive less than 10 Gy and that continued for all patients.

Maximum Tumor Dimension (MTD) was defined for each liver lesion as the largest measurement in axial or craniocaudal dimension *via* CT simulation imaging for OLT patients. A radiologist proficient in CT-body imaging determined the MTD. Tumor volume from pathology reports was calculated by using the formula  $0.5 \times L \times W \times H$ , where L is the greatest length, W is the greatest width, and H is the greatest depth or height of the tumor [11]. Peripheral SBRT dose was administered either 1) in a bi-weekly manner to 50 Gy in 5 fractions or 2) to 45 Gy in 3 fractions given every other day. Peaking doses within the tumors were intended to be 25% to 30% higher than the prescribed dose. We preferentially utilized the 45 Gy schedule unless normal tissue tolerances could not be met necessitating additional fractionation provided by the 50 Gy schedule.

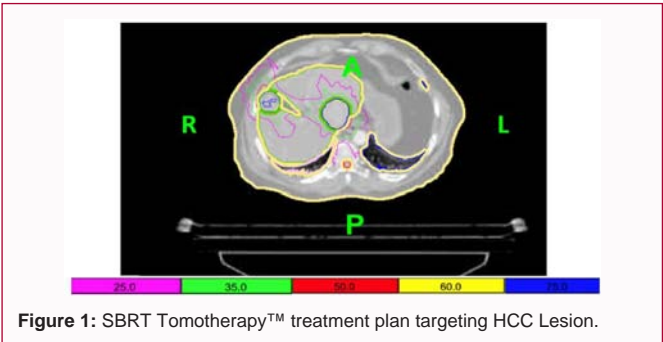
This could occur with lesions abutting sensitive structures such as the duodenum or kidney, or in patients with small cirrhotic livers where the volume of liver to be spared was problematic. The majority of our patients (75%) were treated with the 50 Gy in 5 fraction regimen.

### Evaluation

The patients were assessed during SBRT on the first and last days of treatment. After the completion of treatment, the patients followed up at regular intervals with imaging of the livers and blood work one month after completion of treatment and then every 3 months until

**Table 1:** Transplant Patients' clinical and treatment characteristics.

Characteristic	
Sex [n (%)]	
Male	12 (100)
Female	0
Age (years)	57 ( 52-66)
Tumor Size (cm)	3.6 (1.1-6.1)
Tumor Location [n (%)]	
Right Lobe	10 (59)
Left Lobe	7 (41)
Cirrhosis [n (%)]	
Yes	12 (100)
No	0
Hepatitis [n (%)]	
C	9 (75)
B	1 (8)
Autoimmune	1 (8)
None	1 (8)
Model for End-Stage Liver Disease score [n (%)]	
<9	6 (50)
19-Oct	5 (42)
20-29	1 (8)
Child-Pugh classification [n (%)]	
A	10 (83)
B	2 (17)
C	0
Previous treatment [n (%)]	
No previous therapy	5 (42)
TACE	3 (25)
TACE and RFA	4 (33)



OLT.

Results

Patients

The median age of all patients was 57 years (range 52 to 66) at treatment. The severity of liver disease before liver transplantation measured by the MELD score was <9 for 6 patients, 10 to 19 for 5 patients and 20 to 29 for 1 patient. The Child-Pugh classification was A for 10 patients and B for 2 patients. No patient had a Child-Pugh score of C. The majority of patients (75%) had Hepatitis C.

One patient had Hepatitis B and one patient had autoimmune liver disease. There were 10 tumors in the right lobe and 7 tumors in the left lobe. All patients had evidence of cirrhosis.

Patients selected for SBRT were no longer eligible for more conventional therapies. Three patients had undergone previous TACE treatment. Of these three patients, one patient underwent TACE twice. Four patients underwent both TACE and RFA. One patient underwent TACE three times and RFA once. Five patients received no other prior treatment because of ineligibility. All patient demographics are presented in (Table 1).

SBRT as a bridge to hepatic transplantation

Twelve patients with 17 HCC lesions underwent SBRT as a bridge to OLT. The median tumor size was 3.6 cm (range 1.1 cm to 6.1 cm (Table 1)). The median dose was 48 Gy (range 45 Gy to 50 Gy) in 3 or 5 fractions given in two or three fractions per week (radiation dosage shown on Table 2).

Twelve patients underwent OLT. Five patients who were treated with SBRT with the intent of undergoing transplantation dropped of the transplant wait list. The mean time from SBRT to liver transplant on wait list was 278 days (range 86 to 554 days). None of the patients had evidence of progressive tumors on day of OLT (Figure 1).

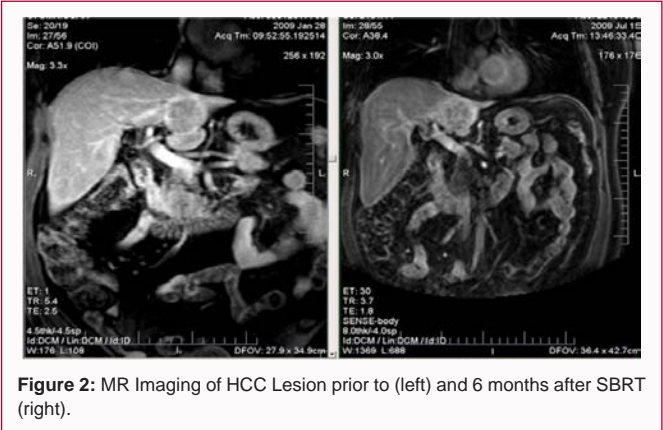
Radiographic local control

The last imaging scan was compared to the scan prior to SBRT treatment. Of the patients that made it to transplant with 17 lesions, 13 lesions (76.5%) had stable disease and 4 lesions (23.5%) had partial response according to RECIST 1.1. All lesions were under radiographic LC. The five patients who did not make it to transplant day all had radiographic LC at the last follow-up visit. Figure 2 demonstrates a lesion treated with SBRT with partial response.

Explant pathology and clinicopathological correlations

After SBRT and liver transplantation, explant pathology revealed that in 8 of the 17 tumors, there was no evidence of a viable tumor for a complete pathological response rate of 47.1%. Figure 3 demonstrates a tumor with complete necrosis after treatment with SBRT. Residual HCC was seen in the other 9 tumors (Table 2). For the 9 tumors with viable HCC according to explant pathology, the maximum tumor diameter was compared to maximum tumor diameter according to gross pathology examination. Six of the 9 tumors (66%) decreased in size after SBRT, and 3 tumors (33%) were stable in size.

In addition, 13 of the 17 lesions had GTV measured at CT simulation and also at explant pathology. Of these 13 lesions, 11 showed a decrease in volume size. One of the 13 lesions did not have



**Table 2:** Twelve Transplant Patients treated with SBRT.

Patient	Pre-SBRT Treatment	Tumor Diameter (cm)	Tumor Volume (cm <sup>3</sup> )	SBRT Dose (Gy)/ fractions	Time from SBRT to Liver Transplantation (Days)	Explant Pathology/ Tumor Size (cm)/ Tumor volume (cm <sup>3</sup> )	Follow- up After SBRT (Months)	Disease Status
1a	None	3.8	n/a	50/5	286	No viable tumor	51	NED
1b	None	4.1	n/a	50/5	286	Residual HCC/4.3/ 54.2	51	NED
2	TACE × 1	6.1	11.7	50/5	73	Residual HCC/5	45	NED
3a	TACE × 2	4.6	60.9	50/5	541	No viable tumor	15	NED
3b	RFA × 1	1.9	n/a	50/5	541	No viable tumor	15	NED
4a	None	3.5	13.4	50/5	115	Degenerative HCC/3.5/ 21	54	NED
4b	None	2.2	1.9	50/5	115	Residual HCC/1.8/ 0.8	54	NED
4c	None	1.1	8.0	50/5	115	Residual HCC/ 1.3 / 2.9	54	NED
5	None	4	46.8	50/5	352	Residual HCC/2.2/ 6.7	41	NED
6	None	2.9	7.1	50/5	137	Residual HCC/1.8/ 5.8	33	NED
7a	RFA × 2	3.2	4.8	45/3	130	No viable tumor	3	NED
7b	RFA × 2	2.4	n/a	45/3	130	No viable tumor	3	NED
8	TACE × 1	2.7	8	45/3	374	No viable tumor	17	NED
9	TACE × 1	4.3	43.1	45/3	376	Residual HCC/1.5/ 16.3	41	NED
10	None	4	29.5	50/5	381	Residual HCC/3/33.6	47	NED
11	TACE × 3 RFA × 1	5.5	2.1	50/5	223	No viable tumor	223	NED
12	TACE × 1	5.6	8.4	50/5	321	No viable tumor	15	NED

**Table 3:** Radiographic and Pathologic Response.

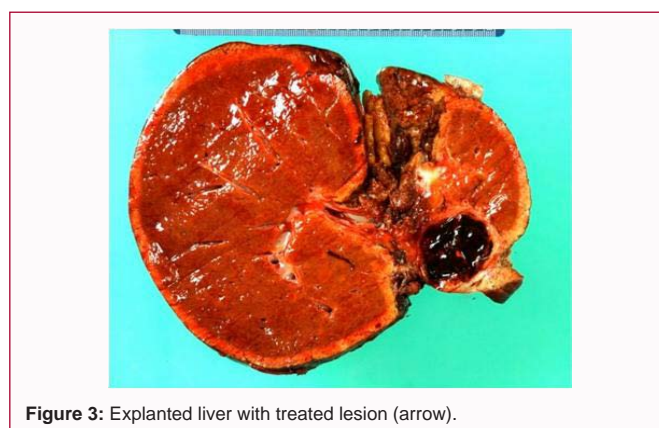	Radiologic Response (n=22)	Pathologic Response (n=17)
CR/ NVT	0	8
PR	5	5
SD	17	4
PD	0	0
CONTROL	22/22 (100%)	17/17 (100%)

a reported volume at explant pathology, and only one tumor had an increase in volume (Table 2). Three of 4 lesions that did not have a reported GTV had no viable tumor on pathology. A summary of the LC and PC is demonstrated in Table 3. Of the 22 lesions treated with SBRT, all had LC. Five lesions had Partial Response (PR) and 17 lesions had Stable Disease (SD). The 17 lesions that were analyzed on transplant demonstrated 8 with no viable tumor, 5 with PR, and 4 with SD.

### Toxicities

There was grade 1 fatigue in one patient; grade 1 abdominal pain in one patient; grade 1 nausea in three patients. Prophylactic antiemetics were prescribed to be taken one hour before each treatment. No patients experienced grade 2 toxicities or greater. All on-treatment toxicities were resolved by first follow-up visit at one month. There were no episodes of biliary obstruction, pulmonary toxicity or other significant late toxicities. One patient had telangiectasia and fibrosis of the skin in the right upper back that developed after SBRT completion. We observed no differences in operative morbidities or hospitalization when transplantation was preceded by SBRT. There was no evidence of damage to hepatic vessels and no evidence of issues with postoperative healing.

No patient experienced significant decrement in liver function as noted through time of analysis or up through transplant date. There was no indication of RILD in any OLT candidate through most recent

**Figure 3:** Explanted liver with treated lesion (arrow).

follow up appointment.

### Survival

The 5-year Overall Survival (OS) for our patient cohort was 58.3%. The disease-free survival for our patients was 100%. The five transplanted patients (41.7%) who passed away were all from causes unrelated to the cancer. The median survival was not reached. The median follow-up for alive patients was 75.6 months with a minimum follow-up of 31 months. All living patients were free of disease at last follow-up.

### Patients taken off transplant list

Of the remaining five patients awaiting transplant each had one lesion treated *via* SBRT, and all have had radiographic LC with a median follow up of 10 months (8 to 21 months). Since SBRT, 2 patients have been removed from the transplant list, one with involvement of malignant thrombus in the right portal vein and died from the cancer, and the other patient was removed due to pulmonary hypertension. Three other OLT candidates died prior to receiving transplant; one patient died on liver transplant day, one



patient had multisystem organ failure, and one patient died from an unknown cause. The patient who died on transplant day was found to have dense adhesions surrounding the bowel and liver and was therefore removed.

## Discussion

In this study, SBRT for HCC lesions in transplant candidates is an effective means of LC with successful bridging to transplant. In addition, radiographic interpretation of lesions treated with SBRT was consistent with pathologic findings. These promising results suggest that both CT and MR imaging of the liver are appropriate means of determining response to local therapy *via* SBRT to HCC lesions.

Radiotherapy has been used sparingly to treat liver tumors because of concerns of RILD [12]. Better radiographic imaging, dose escalation through hypofractionation, and techniques accounting for tumor motion due to respiration have contributed to increased utilization of SBRT for treatment of primary and secondary liver malignancies while minimizing the exposure to surrounding critical structures [13]. SBRT has been shown to have the potential for high LC rate with low morbidity rates when used to treat primary and metastatic liver malignancies [14].

Other liver directed therapies have been used as a bridge to transplant but each therapy has its limitations including the number of lesions, size of lesions, tumor location, patient's general health, and patient's liver function. These techniques have been shown to decrease the dropout rate [15], but there is limited data on OS [16].

TACE is currently one of the more common bridge therapies for HCC and results in extensive tumor necrosis (50% to 77%) [17]. However, tumor cells surviving TACE also show increased growth and angiogenic factors [18]. SBRT may be beneficial for patients that failed TACE as SBRT allows for a larger margin around the tumor. Kelsey et al. [19] demonstrated that radiation therapy with a 0.5 cm or 1.0 cm margin around the tumor encompassed the pathological tumor in 93% or 100% of cases. TACE is also a more expensive procedure incurring a median cost of \$13,400 where SBRT has a Medicare cost of \$11,000 [20]. RFA is frequently used as a bridge therapy for HCC. SBRT can be employed for lesions that are not safely accessible with RFA probes or to lesions adjacent to major vessels including the portal vein and vena cava where blood flow prevents adequate heat deposition by RFA.

There are limited studies that report the use of SBRT for liver transplant candidates. O' Connor et al. [21] reported a study of 10 patients with 11 lesions with median tumor size 3.4 cm treated to a median dose of 51 Gy in 3 fractions with complete pathologic response in 27% of lesions. Sandroussi et al. [22] conducted a study of 10 patients that failed prior local therapies that received radiation dose of 33 Gy in one to six fractions. LC was 100% at 14 months and five patients went on to transplantation. Andolino et al. [23] used SBRT at median dose 48 Gy in 3 fractions to 21 patients who subsequently underwent OLT. Median PFS and OS were 37 and 44 months respectively, and patients who did not undergo OLT were 11.4 times more likely to die ( $p=0.003$ ).

For treatments in five fractions or less, our patient cohort is the largest in size compared to previous dedicated studies and the first to have over 5 years of follow-up. The study by Katz et al. [24] with 18 patients was treated to 50 Gy over 10 fractions and the other two studies by O' Connor et al. [21] and Sandroussi et al. [22] had 10

patients. After transplant, all seven living patients have no disease recurrence. Our drop-out rate of 5/17 patients (29.4%) in our study is consistent with literature. However, only one of the patients who dropped out was due to progression of disease.

According to our pathology reports, 47% of the patients had complete tumor necrosis with 100% LC. Six of the remaining 9 tumors that did not demonstrate complete necrosis on pathology reduced in unidirectional tumor size and tumor volume. The remaining three lesions showed stable size. Our study showed a decrease in volume on 11 of 13 lesions (84.6%) with available data.

Only one tumor showed increased volume, but did not increase in volume over 30%. Our rate of complete tumor necrosis was higher than that reported by O' Connor (27%) [21].

The treatment was well tolerated with minor symptoms and no increased risk of post-operative complications for our patient cohort and compares favorably to TACE and RFA, which are frequently complicated by moderate-to-severe abdominal pain [25]. The average MELD score of patients before SBRT was 10.8 and the average MELD score at transplant was 12. Three patients had an increased MELD score to a higher category, 1 patient had a decrease in MELD score, and 8 patients maintained their score within the same category. The clinical progression of these patients was insignificant.

SBRT for HCC lesions in transplant candidates is an effective means of LC with successful bridging to transplant. Radiologic assessment subsequent to SBRT correlated with pathologic findings after transplant. These promising results suggest a broader role for SBRT in management of limited volume HCC. Although the numbers of patients were small in our study, clinicians may want to consider SBRT as a bridge to transplant for patients with HCC. Prospective studies are needed to determine the role of SBRT in liver transplant candidates.

## References

1. Jemal A, Bray F, Center MM, Ferlay J, Ward E, Forman D. Global cancer statistics. *CA Cancer J Clin*. 2011;61(2):69-90.
2. Befeler AS, Di Bisceglie AM. Hepatocellular carcinoma: diagnosis and treatment. *Gastroenterology*. 2002;122(6):1609-19.
3. Murray KF, Carithers RL Jr, AASLD. AASLD practice guidelines: Evaluation of the patient for liver transplantation. *Hepatology*. 2005;41(6):1407-32.
4. Wiesner R, Edwards E, Freeman R, Harper A, Kim R, Kamath P, et al. Model for end-stage liver disease (MELD) and allocation of donor livers. *Gastroenterology*. 2003;124(1):91-6.
5. Yao FY, Bass NM, Ascher NL, Roberts JP. Liver transplantation for hepatocellular carcinoma: Lessons from the first year under the Model of End-Stage Liver Disease (MELD) organ allocation policy. *Liver Transpl*. 2004;10(5):621-30.
6. Schwartz M, Roayaie S, Uva P. Treatment of HCC in patients awaiting liver transplantation. *Am J Transplant*. 2007;7(8):1875-81.
7. Topkan E, Onal HC, Yavuz MN. Managing liver metastases with conformal radiation therapy. *J Support Oncol*. 2008;6(1):9-13,15.
8. Fuss M, Thomas CR Jr. Stereotactic body radiation therapy: an ablative treatment option for primary and secondary liver tumors. *Ann Surg Oncol*. 2004;11(2):130-8.
9. Gutiérrez AN, Stathakis S, Crownover R, Esquivel C, Shi C, Papanikolaou N. Clinical evaluation of an immobilization system for stereotactic body radiotherapy using helical tomotherapy. *Med Dosim*. 2011;36(2):126-9.

10. Benedict SH, Yenice KM, Followill D, Galvin JM, Hinson W, Kavanagh B, et al. Stereotactic body radiation therapy: The report of AAPM Task Group 101. *Med Phys*. 2010;37(8):4078-101.
11. Monga SP, Wadleigh R, Sharma A, Adib H, Strader D, Singh G, et al. Intratumoral therapy of cisplatin/epinephrine injectable gel for palliation in patients with obstructive esophageal cancer. *Am J Clin Oncol*. 2000;23(4):386-92.
12. Dawson LA, Normolle D, Balter JM, McGinn CJ, Lawrence TS, Ten Haken RK. Analysis of radiation-induced liver disease using the Lyman NTCP model. *Int J Radiat Oncol Biol Phys*. 2002;53(4):810-21.
13. Feng M, Ben-Josef E. Radiation therapy for hepatocellular carcinoma. *Semin Radiat Oncol*. 2011;21(4):271-7.
14. Herfarth KK, Debus J, Lohr F, Bahner ML, Rhein B, Fritz P, et al. Stereotactic single-dose radiation therapy of liver tumors: Results of a phase I/II trial. *J Clin Oncol*. 2001;19(1):164-70.
15. Fisher RA, Maluf D, Cotterell AH, Stravitz T, Wolfe L, Luketic V, et al. Non-resective ablation therapy for hepatocellular carcinoma: Effectiveness measured by intention-to-treat and dropout from liver transplant waiting list. *Clin Transplant*. 2004;18(5):502-12.
16. Millonig G, Graziadei IW, Freund MC, Jaschke W, Stadlmann S, Ladurner R, et al. Response to preoperative chemoembolization correlates with outcome after liver transplantation in patients with hepatocellular carcinoma. *Liver Transpl*. 2007;13(2):272-9.
17. Stockland AH, Walser EM, Paz-Fumagalli R, McKinney JM, May GR. Preoperative chemoembolization in patients with hepatocellular carcinoma undergoing liver transplantation: influence of emergent versus elective procedures on patient survival and tumor recurrence rate. *Cardiovasc Intervent Radiol*. 2007;30(5):888-93.
18. Li X, Feng GS, Zheng CS, Zhuo CK, Liu X. Expression of plasma vascular endothelial growth factor in patients with hepatocellular carcinoma and effect of transcatheter arterial chemoembolization therapy on plasma vascular endothelial growth factor level. *World J Gastroenterol*. 2004;10(19):2878-82.
19. Kelsey CR, Scheffter T, Nash SR, Russ P, Barón AE, Zeng C, et al. Retrospective clinicopathologic correlation of gross tumor size of hepatocellular carcinoma: Implications for stereotactic body radiotherapy. *Am J Clin Oncol*. 2005;28(6):576-80.
20. Whitney R, Válek V, Fages JF, Garcia A, Narayanan G, Tatum C, et al. Transarterial chemoembolization and selective internal radiation for the treatment of patients with metastatic neuroendocrine tumors: A comparison of efficacy and cost. *Oncologist*. 2011;16(5):594-601.
21. O'Connor JK, Trotter J, Davis GL, Dempster J, Klintmalm GB, Goldstein RM. Long-term outcomes of stereotactic body radiation therapy in the treatment of hepatocellular cancer as a bridge to transplantation. *Liver Transpl*. 2012;18(8):949-54.
22. Sandroussi C, Dawson LA, Lee M, Guindi M, Fischer S, Ghanekar A, et al. Radiotherapy as a bridge to liver transplantation for hepatocellular carcinoma. *Transpl Int*. 2010;23(3):299-306.
23. Andolino DL, Johnson CS, Maluccio M, Kwo P, Tector AJ, Zook J, et al. Stereotactic body radiotherapy for primary hepatocellular carcinoma. *Int J Radiat Oncol Biol Phys*. 2011;81(4):e447-53.
24. Katz AW, Chawla S, Qu Z, Kashyap R, Milano MT, Hezel AF. Stereotactic hypofractionated radiation therapy as a bridge to transplantation for hepatocellular carcinoma: Clinical outcome and pathologic correlation. *Int J Radiat Oncol Biol Phys*. 2012;83(3):895-900.
25. Zeeneldin AA, Salem SE, Tabashy RH, Ibrahim AA, Alieldin NH. Transarterial chemoembolization for the treatment of hepatocellular carcinoma: a single center experience including 221 patients. *J Egypt Natl Canc Inst*. 2013;25(3):143-50.