



Hepatic Arterial Infusion Chemotherapy vs. Transcatheter Arterial Embolization for Patients with Huge Unresectable Hepatocellular Carcinoma

Wei-Lun Tsai^{1,2}, Wei-Chi Sun^{1,2}, Chia-Ling Chiang^{2,3}, Huey-Shyan Lin⁴, Huei-Lung Liang^{2,3,5} and Jin-Shiung Cheng^{1,2*}

¹Department of Internal Medicine, Kaohsiung Veterans General Hospital, Taiwan

²Department of Medicine, National Yang-Ming University, Taiwan

³Department of Radiology, Kaohsiung Veterans General Hospital, Taiwan

⁴Department of Nursing, Fooyin University, Taiwan

⁵Department of Medicine, National Defense Medical Center, Taiwan

Abstract

Objectives: For the treatment of huge unresectable Hepato Cellular Carcinoma (HCC), Transcatheter Arterial Chemo Embolization (TACE) or Transcatheter Arterial Embolization (TAE) generally had poor effects and high complication rates. Our previous study found that Hepatic Arterial Infusion Chemotherapy (HAIC) is a safe procedure and provides better survival than symptomatic treatment for the patients with huge unresectable HCC. The aim of the study is to compare the effect of HAIC versus TAE in patients with huge unresectable HCC.

Patients and Materials: Since 2000 to 2005, patients with huge (size ≥ 8 cm) unresectable HCC were enrolled. Twenty-six patients received HAIC and 25 patients received TAE. Each patient in the HAIC group received 2.5 ± 1.4 (range: 1-6) courses of HAIC and in the TAE group received 1.8 ± 1.2 (range: 1-5) courses of TAE. Baseline characteristics and survival were compared between the HAIC and TAE group.

Results: The HAIC group and the TAE group were similar in baseline characteristics and tumor stages. The overall survival rates at one and two years were 42% and 31% in the HAIC group and 28% and 24% in the TAE group. The patients in the HAIC group had higher overall survival than the TAE group ($P=0.077$). Cox-regression multivariate analysis revealed that HAIC is the significant factor associated with overall survival (relative risk: 0.461, 95% confidence interval: 0.218-0.852, $P=0.027$). No patients died of the complications of HAIC but three patients (12%) died of the complications of TAE.

Conclusion: HAIC is a safe procedure and provides better survival than TAE for patients with huge unresectable HCCs.

Keywords: Hepatocellular carcinoma; Chemotherapy; Huge; Unresectable

Introduction

Hepato Cellular Carcinoma (HCC) is the fifth most common cancer in the world and ranked the 2nd cause of cancer death in Taiwan [1,2]. Although routine screening for high risk patients, huge HCCs with size of more than 8cm are occasionally seen [3]. Surgical resection is considered to be the standard curative therapy for huge HCC in patients with good liver reserve [2,4-8]. According to the study from Kaohsiung Veterans General Hospital, Mok et al. [9] found that the advantage of hepatic resection in patients with huge HCC is marginal as compared with multimodality treatment including Transcatheter Arterial Embolization (TAE) or Hepatic Arterial Infusion Chemotherapy (HAIC) [9]. However huge HCC often presented with poor liver reserve, with increased frequency of intrahepatic metastasis and vascular invasion, which made surgical resection not suitable. So Transcatheter Arterial Embolization/Chemo Embolization (TAE/TACE) has been considered as the choice for the palliative treatment of huge unresectable HCC. However previous studies found that TACE for huge HCC had poor effect, and TACE related mortality rate of 6.5% to 20% has been reported [10,11]. HAIC is another option for the palliative treatment for inoperable advanced

OPEN ACCESS

*Correspondence:

Jin-Shiung Cheng, Department of Internal Medicine, Division of Gastroenterology and Hepatology, Kaohsiung Veterans General Hospital, 386 Ta-Chung 1st Road, Kaohsiung 813, Taiwan, Tel: +886-7-3468366; Fax: +886-7-3468237; E-mail: rcheng@ms2.hinet.net

Received Date: 06 Mar 2019

Accepted Date: 02 Apr 2019

Published Date: 08 Apr 2019

Citation:

Tsai W-L, Sun W-C, Chiang C-L, Lin H-S, Liang H-L, Cheng J-S. Hepatic Arterial Infusion Chemotherapy vs. Transcatheter Arterial Embolization for Patients with Huge Unresectable Hepatocellular Carcinoma. Clin Oncol. 2019; 4: 1600.

Copyright © 2019 Jin-Shiung

Cheng. This is an open access article distributed under the Creative Commons Attribution License, which permits unrestricted use, distribution, and reproduction in any medium, provided the original work is properly cited.

HCC [12-15]. In our previous study, HAIC with cisplatin, mitomycin C, leucovorin and 5-FU for advanced unresectable HCC had tumor response rate of 28.3% and only one patient died due to the complication of HAIC during 211 courses of treatments [16]. From another recent study from our hospital, HAIC for advanced HCC had overall response rate of 20% [17]. Our recent study also found that HAIC provided survival benefit over symptomatic treatment in patients with huge unresectable HCC and no patients died of the immediate complications of HAIC [18]. So HAIC seemed to be an effective and safe method for the treatment of huge unresectable HCC. But the effect of HAIC versus TAE for the treatment of huge unresectable HCC remained unclear. The aim of the study is to investigate the effect of HAIC versus TAE for the treatment of huge unresectable HCC.

Materials and Methods

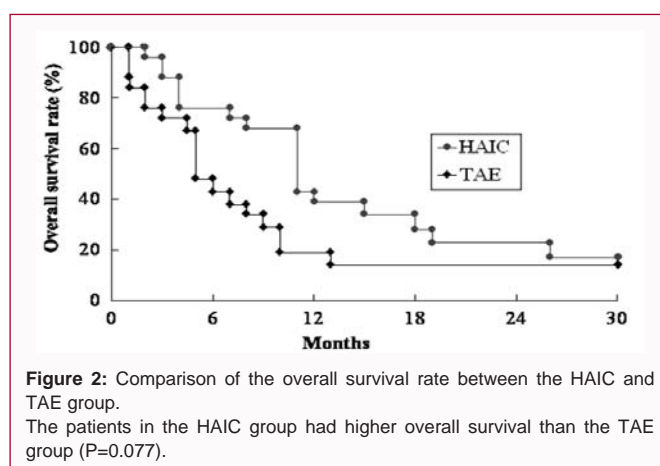
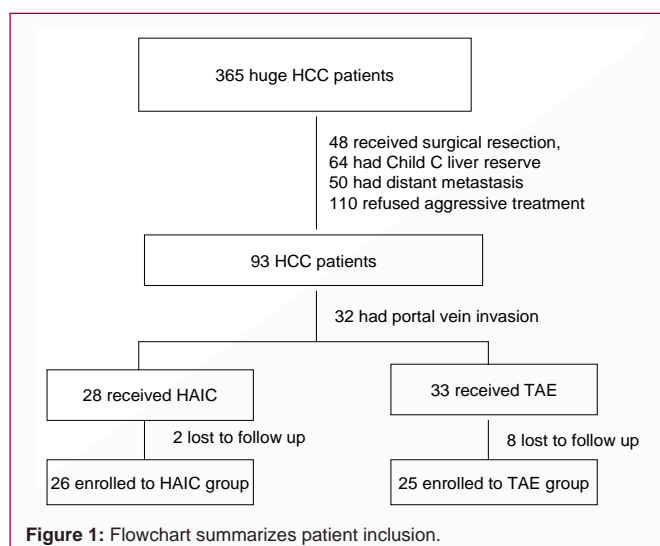
Patients

From January 2000 to December 2005, consecutive eligible patients with Hepato Cellular Carcinoma (HCC) were enrolled in this study. HCC was diagnosed by pathology or elevation of Alpha-Feto Protein (AFP) level above 400 ng/ml along with at least two different imaging techniques including Computed Tomography (CT) or Magnetic Resonance Imaging (MRI). All patients met the following criteria: (a) tumor of 8 cm or more in diameter, (b) patients who were not suitable for operation, (c) portal vein is patent (d), platelet counts >50000/cumm, (e) prothrombin time INR <1.5. (f) white cell counts >2500/cumm, and (g) Child A or B liver reserve. Patients with a previous history of treatment for HCC, or distant metastasis were excluded.

From 2000 to 2005, 365 consecutive patients first diagnosed with huge HCC defined as tumor size greater than or equal to 8 cm were admitted to Kaohsiung Veterans General Hospital. Among the 365 patients, 272 were excluded (48 received surgical resection, 64 had Child C liver reserve and 50 had distant metastasis, and 110 refused aggressive treatment). Thirty-two patients who had portal vein invasion were excluded. Among the 28 patients who received HAIC, 2 were lost to follow up and 26 patients were enrolled in the HAIC group. Among the 33 patients who received TAE, 8 patients were lost to follow up, so 25 patients were enrolled in the TAE group (Figure 1).

Hepatic arterial infusion chemotherapy (HAIC)

The left subclavian artery was cannulated with a catheter and the tip of the catheter was placed in the proper hepatic artery under fluoroscopic guidance before each course of chemotherapy [13]. The main trunk of the gastro duodenal artery was occluded by metallic coil routinely. Continuous infusion of 5000 units (5 cc) heparin solution daily was filled in the catheter for prevention of occlusion by thrombosis. Each course of treatment was 5 days. Cisplatin (10 mg/m²) and mitomycin-C (2 mg/m²) were dissolved in 50 ml isotonic sodium chloride solution which was infused for 20 min to 30 min each time and continued for 5 days. In addition, 100 mg/m² of 5-fluorouracil (5-FU), dissolved in 250 ml of isotonic sodium chloride solution was administered for 24 hr by infusion pump for 5 days. Leucovorin (15 mg/m²) was given daily to improve the efficacy of 5-FU during HAIC. The interval between 2 courses of treatment was 3 to 4 weeks. Each patient received at least one session of treatment. Three-phase Computed Tomography (CT) scan of liver was done after every 2 courses of treatment. Termination of treatment when patients received 6 courses of treatment or until clinical conditions of



the patients was not suitable for another course of HAIC.

Transcatheter arterial embolization (TAE)

TAE was performed through selective hepatic arterial catheterization. Whenever possible, the arteries that supply the tumor were catheterized super selectively and 5 ml to 15 ml of lipiodol was injected, followed by embolization with small gel foam pellets of 1 mm × 1 mm in size. CT scan of liver was performed 2-3 months after TAE and further TAE was performed every 2-3 months if viable or recurrent tumors were found and patient had suitable liver reserve and no contraindication for TAE. All patients were followed by CT or MRI of liver and AFP every 3 months.

Follow-up

All patients in the HAIC group who completed total 6 courses of chemotherapy or not suitable for further chemotherapy or patients in the TAE group who were not suitable for further TAE received follow-up with liver function test, AFP, sonography, CT scan or MRI of liver every 3 months.

Statistical analysis

The data were expressed as mean ± standard deviation. Categorical variables were compared with the X² test or Fisher's exact test when appropriate and continuous variables were compared with the Mann-Whitney test. Overall survival was estimated using the Kaplan-Meier method and the difference was determined by the log-

Table 1: Baseline characteristics of the patients in the HAIC or TAE group.

Characteristics	HAIC N=26	TAE N=25	P-value
Age (years)	63 ± 13	64 ± 12	.771
Sex (M/F)	21/5	22/3	.703
HBV/non-HBV	16/10	16/9	.987
Tumor size (cm)	12 ± 3	11 ± 3	.290
Tumor No (1/>1)	11/15	14/11	.467
Albumin (g/dl)	3.4 ± 0.7	3.5 ± 0.7	.412
Bilirubin (mg/dl)	1.3 ± 0.7	1.1 ± 0.7	.601
AFP (ng/ml)	31848 ± 8790	7526 ± 1674	.180
Child class (A/B)	16/10	18/7	.428

HAIC: Hepatic Arterial Infusion Chemotherapy; TAE: Transcatheter Arterial Embolization; AFP: Alpha-Feto Protein

rank test. Univariate and multivariate analysis were performed using Cox's regression model with proportional hazards. A P-value of less than 0.05 was considered as statistically significant.

The study was approved by the Kaohsiung Veterans General Hospital Institutional Review Board. This was a retrospective study without intervention or obtaining clinical specimens and all the data were analyzed anonymously, so informed consent was waived. The waiving of informed consent was approved by the Institutional Review Board of Kaohsiung Veterans General Hospital.

Results

The baseline characteristics of patients in the HAIC group and the symptomatic treatment group were similar in age, sex, tumor size, tumor number, ALT level, albumin level, bilirubin level, presence of ascites, Child's classification, Okuda stage, CLIP stage, BCLC sub stage and AJCC stage (Table 1) [19,20].

Total 64 courses of HAIC were performed for the 26 patients in the HAIC group. Each patient received 2.5 ± 1.4 (range: 1-6) courses of HAIC. No patients died of the immediate complications of HAIC. One patients developed bacteremia during HAIC and were treated successfully by antibiotics. Total 45 courses of TAE were performed for the 25 patients in the TAE group. Each patient received 1.8 ± 1.2 (range: 1-5) courses of TAE. Three patients (12%) died of the immediate complications of TAE (one died of tumor rupture and two died of liver failure). One patient developed liver abscess after TAE and resolved after pig-tail drainage and antibiotics treatment.

Mean follow-up time was 8.3 ± 11 months (range: 1-45 months).

Table 2: Factors associated with overall mortality in the HAIC or TAE group.

	Univariate analysis			Multivariate analysis		
	Hazard ratio	95% CI	P	Hazard ratio	95% CI	P
Age (years)	0.967	0.943-0.993	0.011	0.986	0.955-1.018	0.382
Sex (male vs. female)	0.747	0.309-1.807	0.517			
Tumor No (1 vs. >1)	0.632	0.332-1.204	0.163			
Tumor size (cm)	1.1	0.999-1.211	0.052	1.089	0.962-1.234	0.179
Child's classification (A vs. B)	0.575	0.293-1.128	0.107			
AFP level (ng/ml)	1	1.000-1.000	0.005	1	1.000-1.000	0.005
Bilirubin (mg/dl)	1.281	0.886-1.852	0.187			
Albumin (gm/dl)	0.82	0.524-1.282	0.384			
HAIC vs. TAE	0.572	0.300-1.091	0.09	0.461	0.218-0.852	0.027

HAIC: Hepatic Arterial Infusion Chemotherapy; TAE: Transcatheter Arterial Embolization

The overall survival rates at one and two years were 42% and 31% in the HAIC group and 28% and 24% in the TAE group. The patients in the HAIC group had higher overall survival than the TAE group with borderline statistical significance ($P=0.077$) (Figure 2). Cox-regression multivariate analysis revealed the significant factor associated with overall survival were HAIC (relative risk: 0.461, 95% confidence interval: 0.218-0.852, $P=0.027$) and AFP level (relative risk: 1.000, 95% confidence interval: 1.000-1.000, $P=0.005$) (Table 2).

Discussion

Surgical resection is the treatment of choice for patients with huge HCC and well-preserved liver function [5-8]. However, only a small proportion of patients with huge HCC can fit the criteria for surgical resection. But patients with huge HCC often had a higher prevalence of extra capsular tumor invasion into liver parenchyma, more frequent intrahepatic metastasis and worse survival than those with smaller tumors [21-23]. Our recent study also found that HAIC provided survival benefit over symptomatic treatment in patients with huge unresectable HCC and no patients died of the immediate complications of HAIC [18]. There remained many controversies regarding the treatment for huge unresectable HCC.

Although TAE/TACE has been considered as the choice for the palliative treatment of huge unresectable HCC, severe liver injury after TAE/TACE was anticipated in patients with huge HCC and treatment related mortality rate as high as 20% has been reported [11]. Large tumor size was also found to be a poor prognostic factor in patients undergoing TACE [11,24]. In our hospital, HAIC has been found to be effective and safe for the treatment of advanced or huge unresectable HCC [16-18]. Besides, according to the study by Yamasaki et al. [12] tumor size was not a prognostic factor that influenced the outcome of HAIC for patients with advanced HCC [12]. Studies to compare the treatment outcome of HAIC versus TAE for huge unresectable HCC have never been reported before. This is the first study that compared the treatment outcome of HAIC and TAE in patients with huge unresectable HCC and we found that HAIC is the independent factor associated with overall survival.

HAIC was performed every 3 to 4 weeks and treatment was terminated when patients received 6 courses of treatment or until clinical conditions of the patients were not suitable for another course of HAIC, but TAE was performed every 2-3 months if viable or recurrent tumors were found and patient had suitable liver reserve and no contraindication for TAE; Longer interval between each TAE and poor tumor response and deterioration of liver reserve may

explain only 1.8 courses of TAE was performed.

During the 64 courses of HAIC, most patients tolerated the procedure well and no patients died of the immediate complications of HAIC. However, the mortality rate related to TAE in this study was 12%. So HAIC may be a more safe treatment procedure for the treatment of huge unresectable HCC.

From a previous randomized controlled study in our hospital, TAE compared with TACE had similar effect for the treatment of HCC [25]. Several other studies that directly compared TAE and TACE did not provide evidence of survival advantages favoring TACE [26-29]. From the results of these studies, TACE did not have significant survival benefit over TAE for the treatment of HCC. So TAE instead of TACE was performed in this study.

Sorafenib has been developed and is recommended for the treatment of advanced HCC [30,31]. But the effect of sorafenib for HCC is not satisfactory and actually the response rate of sorafenib is low [32]. An effect of sorafenib in patients with huge unresectable HCC is unclear. Besides, sorafenib is limited by a high cost and many patients cannot afford to receive the treatment, so HAIC provided a good treatment option for patients with huge unresectable HCC.

This study has several limitations. This is not a randomized controlled study, and selection bias may be possible in this study. But the baseline characteristics including age, sex, liver reserve, tumor stages are similar between the two groups of patients. Although the case numbers in this study are small, using Cox regression multivariate analysis, we found that the HAIC group has survival benefit over patients who received TAE. Further randomized controlled studies that enrolled more patients are required to compare the outcome of HAIC versus TAE/TACE for huge unresectable HCC.

In conclusion, HAIC is a safe procedure and provided better survival than TAE for patients with huge unresectable HCCs.

Grant Support

This study was supported by Kaohsiung Veterans General Hospital (VGHKS-104-059 and VGHKS-105-073).

References

- Kao JH, Chen DS. Changing disease burden of hepatocellular carcinoma in the Far East and Southeast Asia. *Liver Int.* 2005;25(4):696-703.
- European Association for the Study of the Liver, European Organisation for Research and Treatment of Cancer. EASL-EORTC clinical practice guidelines: management of hepatocellular carcinoma. *J Hepatol.* 2012;56(4):908-43.
- Sheu JC, Sung JL, Chen DS, Lai MY, Wang TH, Yu JY, et al. Early detection of hepatocellular carcinoma by real-time ultrasonography. A prospective study. *Cancer.* 1985;56(3):660-6.
- Hsu CY, Hsia CY, Huang YH, Su CW, Lin HC, Pai JT, et al. Comparison of surgical resection and transarterial chemoembolization for hepatocellular carcinoma beyond the Milan criteria: a propensity score analysis. *Ann Surg Oncol.* 2012;19(3):842-9.
- Zhong JH, Wu FX, Li H. Hepatic resection associated with good survival for selected patients with multinodular hepatocellular carcinoma. *Tumour Biol.* 2014;35(9):8355-8.
- Noguchi T, Kawarada Y, Kitagawa M, Ito F, Sakurai H, Machishi H, et al. Clinicopathologic factors influencing the long-term prognosis following hepatic resection for large hepatocellular carcinoma more than 10 cm in diameter. *Semin Oncol.* 1997;24(Suppl 6):7-13.
- Lee NH, Chau GY, Lui WY, King KL, Tsay SH, Wu CW. Surgical treatment and outcome in patients with a hepatocellular carcinoma greater than 10 cm in diameter. *Br J Surg.* 1998;85(12):1654-7.
- Furuta T, Sonoda T, Matsumata T, Kanematsu T, Sugimachi K. Hepatic resection for a hepatocellular carcinoma larger than 10 cm. *J Surg Oncol.* 1992;51(2):114-7.
- Mok KT, Wang BW, Lo GH, Liang HL, Liu SI, Chou NH, et al. Multimodality management of hepatocellular carcinoma larger than 10 cm. *J Am Coll Surg.* 2003;197(5):730-8.
- Huang YH, Wu JC, Chen SC, Chen CH, Chiang JH, Huo TI, et al. Survival benefit of transcatheter arterial chemoembolization in patients with Hepatocellular carcinoma larger than 10 cm in diameter. *Alim Pharm Therp.* 2006;23(1):129-35.
- Poon RTP, Ngan H, Lo CM, Liu CL, Fan ST, Wong J. Transarterial chemoembolization for inoperable Hepatocellular carcinoma and postresection intrahepatic recurrence. *J Surg Oncol.* 2000;73(2):109-14.
- Yamasaki T, Kimura T, Kurokawa F, Aoyama K, Icheikawa T, Tajima K, et al. Prognostic factors in patients with advanced Hepatocellular carcinoma receiving hepatic arterial infusion chemotherapy. *J Gastroenterol.* 2005;40(1):70-8.
- Ando E, Tanaka M, Yamashita F, Kuromatsu R, Yutani S, Fukumori K, et al. Hepatic arterial infusion chemotherapy for advanced hepatocellular carcinoma with portal vein tumor thrombosis: analysis of 48 cases. *Cancer.* 2002;95(3):588-95.
- Song MJ. Hepatic artery infusion chemotherapy for advanced hepatocellular carcinoma. *World J Gastroenterol.* 2015;21(13):3843-9.
- Nouso K, Miyahara K, Uchida D, Kuwaki K, Izumi N, Omata M, et al. Effect of hepatic arterial infusion chemotherapy of 5-fluorouracil and cisplatin for advanced hepatocellular carcinoma in the Nationwide Survey of Primary Liver Cancer in Japan. *Br J Cancer.* 2013;109(7):1904-7.
- Lin CP, Yu HC, Cheng JS, Lai KH, Lo GH, Hsu PI, et al. Clinical effects of intra-arterial infusion chemotherapy with cisplatin, mitomycin C, leucovorin and 5-fluorouracil for unresectable advanced Hepatocellular carcinoma. *J Chin Med Assoc.* 2004;67(12):602-10.
- Liang HL, Huang JS, Lin YH, Lai KH, Yang CF, Pan HB. Hepatic arterial infusion chemotherapy for advanced hepatocellular carcinoma by placing a temporary catheter via the subclavian route. *Acta Radiol.* 2007;48(7):734-40.
- Tsai WL, Lai KH, Liang HL, Hsu PI, Chan HH, Lin HS, et al. Hepatic arterial infusion chemotherapy for huge unresectable hepatocellular carcinoma. *Plos One.* 2014;9(5):e92784.
- Maida M, Orlando E, Cammà C, Cabibbo G. Staging systems of hepatocellular carcinoma: a review of literature. *World J Gastroenterol.* 2014;20(15):4141-50.
- Weinmann A, Koch S, Sprinzl M, Kloeckner R, Schulze-Bergkamen H, Düber C, et al. Survival analysis of proposed BCLC-B subgroups in hepatocellular carcinoma patients. *Liver Int.* 2015;35(2):591-600.
- Hsu HC, Sheu JC, Lin YH, Chen DS, Lee CS, Hwang LY, et al. Prognostic histologic features of resected small hepatocellular carcinoma (HCC) in Taiwan- a comparison with resected large HCC. *Cancer.* 1985;56(3):672-80.
- Jwo SC, Chiu JH, Chau GY, Loong CC, Lui WY. Risk factors linked to tumor recurrence of human hepatocellular carcinoma after hepatic resection. *Hepatology.* 1992;16(6):1367-71.
- Adachi E, Maeda T, Kajiyama K, Kinukawa N, Matsumata T, Sugimachi K, et al. Factors correlated with portal venous invasion by hepatocellular carcinoma: univariate and multivariate analyses of 232 resected cases without preoperative treatment. *Cancer.* 1996;77(10):2022-31.
- Takayasu K, Arai S, Ikai I, Omata M, Okita K, Ichida T, et al. Prospective

- cohort study of transarterial chemoembolization for unresectable hepatocellular carcinoma in 8510 patients. *Gastroenterol.* 2006;131(2):461-9.
25. Chang JM, Tzeng WS, Pan HB, Yang CF, Lai KH. Transcatheter arterial embolization with or without cisplatin treatment of hepatocellular carcinoma. A randomized controlled study. *Cancer.* 1994;74(9):2449-53.
26. Kawai S, Okamura J, Ogawa M, Ohashi Y, Tani M, Inoue J, et al. Prospective and randomized trial for the treatment of hepatocellular carcinoma -- a comparison of lipiodol-transcatheter arterial embolization with and without adriamycin (first cooperative study). *Cancer Chemother Pharmacol.* 1992;31(Suppl):S1-6.
27. Ikeda K, Saitoh S, Suzuki Y, Koida I, Tsubota A, Kobayashi M, et al. A prospective randomized administration of 5'-deoxy-5-fluorouridine as adjuvant chemotherapy for hepatocellular carcinoma treated with transcatheter arterial chemoembolization. *Am J Clin Oncol.* 1997;20(2):202-8.
28. Oliveri RS, Wetterslev J, Gluud C. Transarterial (chemo) embolisation for unresectable hepatocellular carcinoma. *Cochrane Database Syst Rev.* 2011;(3):CD004787.
29. Lanza E, Donadon M, Poretti D, Pedicini V, Tramarin M, Roncalli M, et al. Transarterial Therapies for Hepatocellular Carcinoma. *Liver Cancer.* 2016;6(1):27-33.
30. Bruix J, Sherman M; American Association for the Study of Liver Diseases. Management of hepatocellular carcinoma: an update. *Hepatology.* 2011;53(3):1020-22.
31. El-Serag HB. Hepatocellular carcinoma. *N Engl J Med.* 2011;365(12):1118-27.
32. Cheng AL, Kang YK, Chen Z, Tsao CJ, Qin S, Kim JS, et al. Efficacy and safety of sorafenib in patients in the Asia-Pacific region with advanced hepatocellular carcinoma: a phase III randomised, double-blind, placebo-controlled trial. *Lancet Oncol.* 2009;10(1):25-34.