



Hematological Toxicities during Treatment with Immune Checkpoint Inhibitors: Presentation of Two Cases

Xenophontos Eleni^{1*}, Agathocleous Agathoclis¹, Houtri Katerina² and Charalambous Haris¹

¹Department of Medical Oncology, Bank of Cyprus Oncology Center, Cyprus

²Department of Histopathology, General Hospital of Nicosia, Cyprus

Abstract

Immune Checkpoint Inhibitors (ICIs) have revolutionized the treatment of several cancers. Toxicity from immunotherapy has been described commonly and in some cases can be severe and life-threatening. Hematological immune-related events (h-irAEs) are rarely observed and have not been studied extensively. In this report we present two patients with metastatic cancer developing h-irAEs after palliative treatment with immunotherapy. The first case was a woman with metastatic kidney cancer who developed autoimmune thrombocytopenia and hemolytic anemia while on nivolumab treatment. The second case describes a male with squamous cell lung cancer who experienced autoimmune thrombocytopenia during maintenance treatment with pembrolizumab. This report underlines the importance of early diagnosis and adequate management when facing the uncommon event of immune-related hematologic toxicity and emphasizes the need to develop and incorporate algorithms of prompt identification and treatment.

Introduction

Immunologic invisibility has been described as an emerging hallmark of cancer since 2011 [1]. Tumor cells express neoantigens recognized by the immune system, but they avoid immune destruction by overexpressing immunosuppressive molecules such as the cytotoxic T-Lymphocyte Associated Antigen-4 (CTLA-4), the Programmed Death-1 receptor (PD-1) and its Ligand (PDL-1 and PDL-1) [2]. Immune Checkpoint Inhibitors (ICIs) block these intrinsic immune down-regulators and therefore immune destruction is reversed. Treatment with a single ICI, combination of two ICIs or combination with chemotherapy have shown a significant increase in overall survival of patients with a variety of tumors including melanoma, non-small cell lung cancer, kidney and head and neck cancers [3-5,12-14].

Immune Related Adverse Events (irAEs) arise from the uncontrolled activation of immune cells which invade normal organs and dysregulate their function by inflammation [6,7]. Any organ system can be affected but skin, endocrine, respiratory and gastrointestinal system are mostly affected [8,9]. Hematological autoimmune phenomena have not been described commonly [10,11]. Withdrawal of the ICI and immunosuppression with steroids leads to regression of the autoimmune symptoms in the majority of patients. In some severe cases when steroids have failed, more potent immunosuppressive agents (i.e. infliximab, mycophenolate mofetil) are used [8,9].

Case Series

Case 1

This is the case of a 76-year old lady who was diagnosed with de novo metastatic kidney cancer. Her past medical history included hypothyroidism and hypertension treated by lisinopril and amlodipine. A renal mass was accidentally found during a work-up for a lower gastrointestinal bleeding. She had an intermediate risk score by the International Metastatic RCC Database Consortium (IMDC): 1 point for she had less than a year from diagnosis to systemic therapy. Colonoscopy did not show any signs of active bleeding. Staging Computed Tomography (CT) of the chest, abdomen and pelvis revealed bilateral lung metastases and bone scan showed suspicious secondary lesions on the thoracic spine. Subsequent MRI spine did not confirm any bone metastases. Open left nephrectomy was undertaken and the histopathology showed a clear cell carcinoma (CD10(+), Vim(+), PAX8(+), RCC -), Melan A(-), Inhibin(-) extending to the adrenal gland, with perivascular invasion (pT4NxMx, Nuclear grade based on ISUP: 70% Grade 3, 30% Grade 4).

The pattern of her lung metastases did not allow for lung mastectomy and pazopanib was started

OPEN ACCESS

*Correspondence:

Eleni Xenophontos, Department of Medical Oncology, Bank of Cyprus Oncology Center, Acropoleos 32, 2006, Nicosia, Cyprus, Tel: +357-22847300; Fax: +357-22841388; E-mail: eleni.xenophontos87@gmail.com

Received Date: 13 May 2021

Accepted Date: 11 Jun 2021

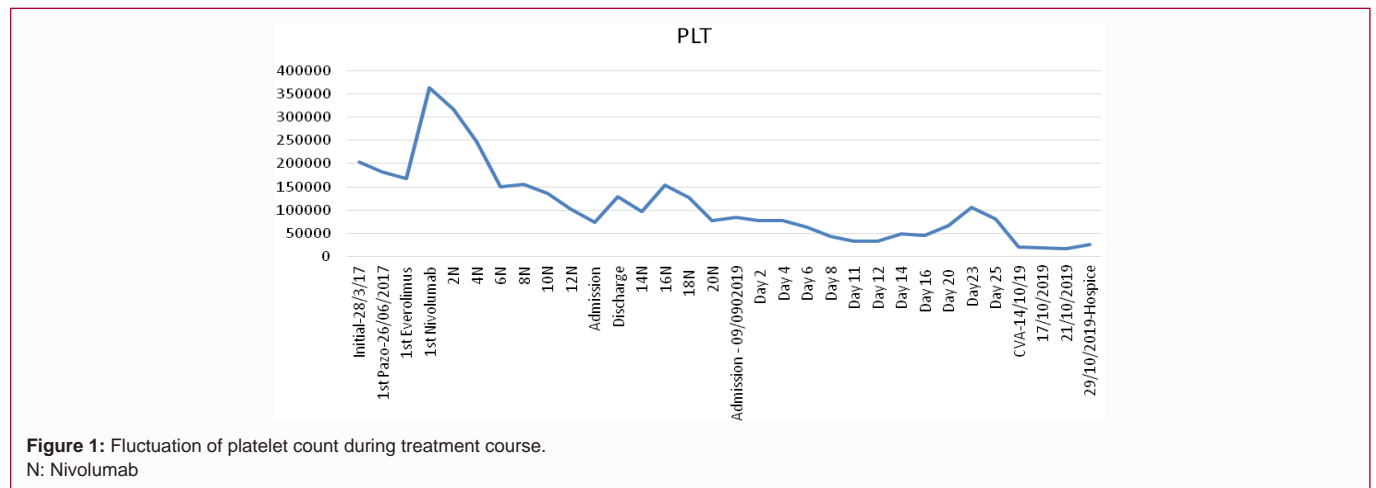
Published Date: 15 Jun 2021

Citation:

Eleni X, Agathoclis A, Katerina H, Haris C. Hematological Toxicities during Treatment with Immune Checkpoint Inhibitors: Presentation of Two Cases. *Clin Oncol.* 2021; 6: 1825.

ISSN: 2474-1663

Copyright © 2021 Xenophontos Eleni. This is an open access article distributed under the Creative Commons Attribution License, which permits unrestricted use, distribution, and reproduction in any medium, provided the original work is properly cited.



on 06/2017. While asymptomatic, she was subsequently changed to sorafenib due to persistent grade 3 elevated Liver Function Tests (LFTs). Unfortunately during the fourth cycle of sunitinib, she experienced breathlessness. Chest X-Ray (CXR) and a chest CT confirmed a moderate pleural effusion. Imaging of the abdomen and the pelvis showed bilateral liver metastases and a soft mass on the site of the surgical wound. Everolimus 10 mg daily was started and the patient soon became asymptomatic. Ten months later she progressed again with lung, liver and adrenal metastases.

Nivolumab was started on 10/2018 as a third-line treatment post VEGFR and mTOR inhibitors. Four months after immunotherapy's initiation she had a partial response on CT scan. During cycle 12 she had an emergency admission due to fever and breathlessness (WBC: 3440; Neut: 2132; Hb: 12.2; PLT: 102,000). The chest X-ray showed bilateral small pleural effusions and signs of pneumonitis, but the subsequent chest CT and the bronchoscopy were negative for pneumonitis. Patient improved after a course of antibiotics and methylprednisolone 1mg/kg. Nivolumab was restarted after a 4-week wean of steroids. Subsequent cycles were well tolerated until cycle 15 (08/2019- 10 months of treatment) when thrombocytopenia grade 1 was observed (PLT: 97,000). On cycle 20, normochromic, normocytic anemia of grade 2 was apparent (Hb=8.1, MCV=91, MCH=29, MCHC=32) and platelets fall to 77,000. Nivolumab was continued and the patient was transfused with one unit of red blood cells.

Eight days after the 20th cycle of Nivolumab she was admitted due to fever and asthenia. Objective examination did not reveal any signs of disease (WBC=1630, Neut=1290, Hb=9.3, PLT=84000). Piperacillin-tazobactam was initiated empirically, but she switched to meropenem and vancomycin as there was no improvement. On day 11 of her hospitalization, an elevating LDH prompted a high suspicion of hemolysis: WBC=3230, Neut=2810, Hb=7.9, MCV=79.5, MCH=27.4, PLT=33,000, Bil=1.17, LDH=3580, Haptoglobulins =8 mg/dL (low). Schistocytes were observed on the peripheral blood film. Anemia work-up did not reveal iron, B12 or folic acid deficiency, and thyroid dysfunction or parvovirus infection. Disseminated Intravascular Coagulation (DIC) profile was also negative. Bone marrow biopsy showed a hypocellular bone marrow (5% cellular) with marked erythroid hypoplasia and no evidence of erythroid precursors. Bone marrow cultures were negative. Autoimmune hemolytic anemia and thrombocytopenia due to immune checkpoint inhibitors was suspected and prednisone 2 mg/kg daily was introduced. Her daily needs for blood and platelet transfusion decreased and jaundice

improved, nonetheless hemoglobin and platelets drop again during steroids tapering (Figure 1). Whilst we considered escalating her immunosuppression, she suffered a right hemiparesis. CT brain showed ischemic Cerebrovascular Accident (CVA) on the left parietal lobe. Treatment with aspirin was not initiated as the risk of bleeding was high due to low platelets counts. As she rapidly deteriorated clinically, she was transferred to a hospice care where she soon died.

Case 2

This is the case of a 74 years old patient presenting with persistent non-productive cough during the COVID pandemic. He had previously been diagnosed with hypothyroidism, had aortic valve replacement and a pacemaker implantation. For that reason he had been on clopidogrel, furosemide, ramipril, carvedilol, spironolactone and omeprazole. Due to restriction measurements he stayed at home and had a course of antibiotics and nebulizers with no improvement. When he finally had a chest X-ray there were two pathologic nodules on the right lung. Chest CT confirmed a 6 cm right upper lobe lesion and a smaller lower lobe lesion with enlarged mediastinal lymph-nodes. Tissue was obtained by a CT-guided biopsy and was consistent with non-small lung cancer favoring squamous histology (p63(+), CK5/6(+), TTF-1(-)). CT staging of the brain was clear of metastases, however abdominal CT showed equivocal liver lesions. PET/CT confirmed liver metastases. Molecular tests and Next-Generation Sequencing (NGS) were negative for driver mutations, though he had a high expression of PDL-1 (~50%). Based on his PDL-1 status and his moderate symptoms he started chemo-immunotherapy with Paclitaxel/Carboplatin/Pembrolizumab (KEYNOTE-407 protocol). CT brain, chest and abdomen showed stable disease after 4 cycles. He proceeded to another 2 cycles and then had maintenance treatment with Pembrolizumab monotherapy every 6 weeks. During treatment he experienced peripheral neuropathy grade 1 and transaminitis grade 1.

Platelet count fluctuated during the course of treatment, but when at cycle 8 of pembrolizumab maintenance treatment he experienced a grade 2 thrombocytopenia (Platelets <75,000) leading to treatment interruption (Figure 2). He remained off treatment for two months with no improvement. He then undergone a bone marrow biopsy; however histopathology did not show any infiltration from cancerous cells and all blood lineages were present and maturing. In the meantime CT brain, chest and abdomen showed partial response to immunotherapy maintenance treatment. Prednisolone 1 mg/kg was initiated as there has not been any progress. Although platelets had

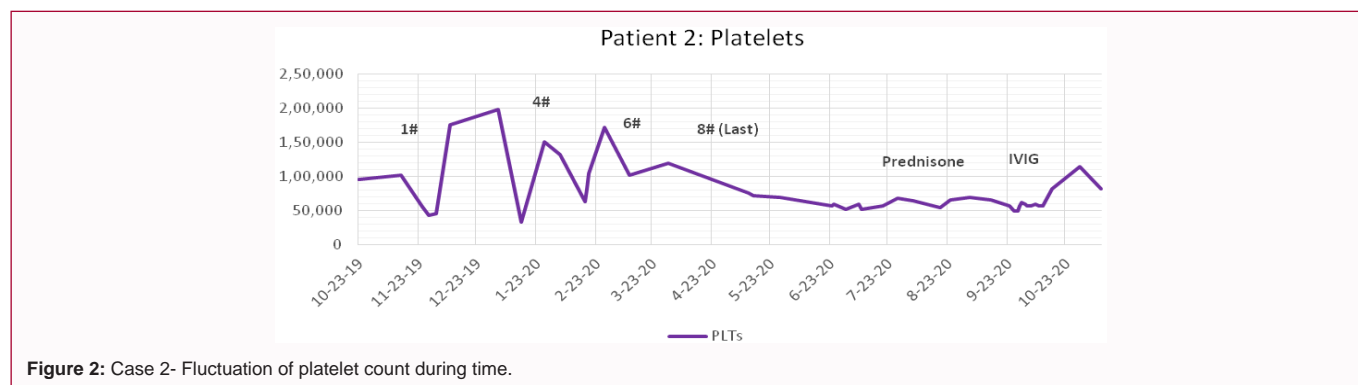


Figure 2: Case 2- Fluctuation of platelet count during time.

an initial increase, they fell again and remained lower than 75,000. As steroids proved unsuccessful, IVIG 1 mg/kg was administered after admitting the patient into the hospital. One month after IVIG administration PLTs surged to around 100,000. During the time of this publication platelets are 81,000 and the patient is off treatment as his latest CT showed stable disease.

Discussion

In this report we describe an interesting and unusual case of a patient developing two immune-related hematological adverse events after the use of nivolumab for metastatic kidney cancer. To our knowledge this case of Immune Thrombocytopenia (IT) and autoimmune hemolytic anemia (Evans syndrome) is one of the few autoimmune bicytopenias published during the immunotherapy era [15]. We also added a second case of autoimmune thrombocytopenia in a patient with metastatic squamous lung cancer while on pembrolizumab treatment. Studies focusing on immune related adverse events indicate that more than 75% of patients treated with ICIs will experience any form of irAEs [10]. Severe AEs (Grade 3-4) occur in about 35% to 40% with a combination immunotherapy and 15% to 20% with a single ICI and require hospitalization and treatment with systemic corticosteroids [10]. While any organ system can be affected, hematological events are seen much less. Recent case-reports indicate that h-irAEs have not been well-recognized, are under-reported and there is a suggestion that they have been gone undiagnosed [16-20].

There is a great amount of published reviews assessing ir-AEs, but as far as we know there are only two reviews focusing on h-irAEs [2,3]. Delaney et al. [16] used data from 3 national wide registries in France and identified 35 patients (18 certain and 17 probable cases) experiencing h-irAEs with anti-PD1 and anti-PDL-1 administration. The median age during symptoms onset was 65 years and there were more men developing h-irAEs than women (ratio 21/14). The most common tumor types associated with hematological toxicity was melanoma (43%), Non-Small Cell Lung Cancer (NSCLC) (34%) and lymphoma (11%). The types of hematological adverse events identified were: Neutropenia (9/35), Autoimmune Hemolytic Anemia (AHA) (9/35), IT (9/35=26%) followed by pancytopenia and aplastic anemia (5/35). The majority of patients experienced grade 3 and 4 toxicity (14% and 71% respectively) and 2 patients died due to febrile neutropenia. Most of the patients were treated successfully with only oral corticosteroids (63%) but a third of them needed an escalation of the treatment with intravenous corticosteroids, IVIG and rituximab. Upon resolution of the symptoms 20% of them were rechallenged with immunotherapy and 43% had a recurrence of their previous h-irAE.

The second review on hematological complications after ICIs was published by Davis et al. [17] the same year. Data from World Health Organization's pharmacovigilance database of Individual-Case-Safety-Reports (ICSRs) of adverse drug reactions were used and 168 cases were identified in 164 ICSR. The search included only severe side effects after the use of anti-CTLA-4, anti-PD-1 and anti-PDL-1 inhibitors. The age range of patients was between 59 to 66 years and more men than women suffered from h-irAEs (91/64). The most common tumor types associated with hematological toxicity were melanoma (74/168), NSCLC (40/168) and renal cell carcinoma (6/168). The types of hematological adverse events identified were: AHA (68 cases), IT (57) and both of them occurred concurrently in 4 cases. Also Hemophagocytic Histiocytosis (HPH) was developed in 26 cases. The severity of the AEs, the treatment administered and its result were not defined. A comparison of the two reviews can be found on Table 1.

While both studies have inherent limitations due to the retrospective nature of the data collection and due to a selection bias, there is no dispute that the true incidence of hematological is low. Delaney et al. [16] identified 35 patients from a pool of 948 patients (3.69%) and Davis et al. [17] 168 cases from a WHO database that contains more 15,000,000 reports regarding side effects of many drugs. Still there is uncertainty regarding the true incidence and the severity of hematological toxicity.

In case A, our patient received nivolumab as a third line treatment for metastatic clear cell kidney cancer (pazopanib-sunitinib at diagnosis and everolimus at her first progression). In the CheckMate 025 trial, patients with advanced clear cell carcinoma, who had previously received one or two lines-except from mTOR inhibitors, were randomized with a 1:1 ratio between nivolumab (3 mg/kg) every 2 weeks and everolimus 10 mg daily [21]. Overall survival, and response rate were significantly better in the interventional arm (HR=0.72, p=0.002 and OR=5.98, 95% CI: 3.68-9.72, p<0.01 respectively). Toxicity profile favored nivolumab compared to everolimus (79% vs. 88%), with the most common side-effect being fatigue for nivolumab and anemia with everolimus [22]. No hematological irAEs were described. In advanced melanoma, a safety profile analysis of Nivolumab identified 39 patients out of 596 (7%) who experienced any type of hematologic toxicity and 7 of them (1%) had a side effect of grade 3 and 4 [23]. In another study of the use of PD-1 inhibitors in advanced melanoma, Zimmer et al. [24] described 3 cases of hematological toxicity out of 496. It is evident from the above that immune related hematological complications are amongst the rarest form of ICIs' toxicity. However the exact incidence may be higher, therefore early recognition and appropriate

Table 1: Comparison table of the two major reviews describing hematological immune related adverse events.

Hematological Immune Related Adverse Events		
	Delanoy et al.	Davis et al.
Database used	3 national-wide registries from France	WHO pharmacovigilance database
Number of h-irAEs	35 cases	168 cases
Male/Female ratio	21/14	91/64
Age range	51-75	59-66
Tumor types	Melanoma: 43% NSCLC: 34% Lymphoma: 11% Other: 12%	Melanoma: 44% NSCLC: 24% Renal cell carcinoma: 3% Other or unknown: 29%
Immunotherapy agents used	Only PD-1 and PDL-1 inhibitors used Nivolumab: 57% Pembrolizumab: 40% Atezolizumab: 1%	anti-CTLA-4: 22% anti CTLA-4+anti-PD-1: 16% anti-PD-1: 58% anti-PDL-1: 4%
hiAEs identified	Neutropenia: 26% AHA: 26% IT: 26% Pancytopenia &AA: 14% Other: 8%	AHA: 40% IT: 34% AHA+IT: 2% HPH: 18% Other: 6%
Median time of onset	10 weeks (1-198 weeks)	6 weeks (1-58 weeks)
Fatal outcome	6%	14%

AHA: Autoimmune Hemolytic Anemia; IT: Immune Thrombocytopenia; HPH: Hemophagocytic Histiocytosis

management with steroids with or without the addition of more potent immunosuppressors is important.

In the second case, an elderly gentleman experienced a persistent grade 2 thrombocytopenia after six cycles of combination Paclitaxel/Carboplatin/Pembrolizumab and two cycles of Pembrolizumab maintenance treatment. He received a course of steroids with no improvement, but had a response to IVIG. In KEYNOTE-024, patients with advanced non-small lung cancer and a PDL-1 expression $\geq 50\%$ were randomized between pembrolizumab and physician's choice platinum-based chemotherapy [25]. None patient in the intervention group had immune thrombocytopenia, while 18 (12%) patients on the chemotherapy arm had thrombocytopenia of any grade. IMPOWER-110 trial investigated atezolizumab monotherapy in the first-line palliative setting of patients with squamous and non-squamous lung cancer with PDL-1 expression $>1\%$ [26]. Only one patient (0.3%) in the atezolizumab group had autoimmune thrombocytopenia of less than grade 2, in comparison with 22 patients (8%) with all grades in the chemotherapy arm. Patients with untreated metastatic squamous lung cancer, like our patient, were randomized between Carboplatin/Paclitaxel or Nab-Paclitaxel/Pembrolizumab and Carboplatin/Paclitaxel or Nab-Paclitaxel/Placebo in the KEYNOTE-407 [27]. Immune mediated hematologic toxicity was not discussed in the paper, however 31% patients in the pembrolizumab-arm had thrombocytopenia of any grade and 7% of more than grade 3 and 23% and 6% in the placebo arm respectively. It is unknown if the cause of thrombocytopenia was immune-mediated or chemotherapy-induced. It is evident that IT's incidence is a rare phenomenon while on immune-monotherapy or in chemo-immunotherapy in lung cancer.

The European and American Society of Clinical Oncology (ESMO/ASCO) published guidelines regarding the management of toxicity after immunotherapy, however only ASCO included a section with a diagnostic and therapeutic management of any h-irAEs [27,28]. For the treatment of grade 1, 2 and 3 autoimmune thrombocytopenia (PLTs $<100/\mu\text{L}$, $<75/\mu\text{L}$, $50/\mu\text{L}$ respectively), ICIs should be withheld until improvement [28]. If no improvement is observed, prednisone 0.5 mg/kg to 2 mg/kg should be administered and tapered in a 2 to 4

week period upon regression. For grade 4 immune thrombocytopenia (PLT $<25/\mu\text{L}$), immunotherapy is permanently stopped and a hematological consultation should be asked. Intravenous Immunoglobulins (IVIG) are administered in conjunction with steroids for a more rapid effect and they may be repeated if symptoms do not resolve. More potent immunosuppression should be used if thrombocytopenia persists.

Guidelines for autoimmune hemolytic anemia management are more stringent and advise an early discontinuation of ICIs during a grade 2 AIA (Hb <10 to 8 mg/dL) [28]. For grade 3 (Hb <8 mg/dl) and 4 AIA (life-threatening situation which needs hospitalization), management includes administration of higher dose of prednisone (1 mg/kg/day to 2 mg/kg/day) with blood transfusions in order to maintain hemoglobin between 7 mg/dL to 8 mg/dL. More potent immunosuppressive agents (i.e. rituximab, IVIG, infliximab) should be initiated if there is no improvement. In our case prednisone was initiated early and red blood cells and platelets were transfused in order to maintain hemoglobin and platelets count to the lower limit of normal. Unfortunately the patient subsequently had a CVA and was not fit enough to be treated with more potent immunosuppressive therapy. Future studies should focus on finding predictive biomarkers for hematological immune related AEs and define the optimal management algorithm.

Conclusion

Hematological toxicity after immunotherapy is a rare phenomenon but not as uncommon as commonly thought. Case reports describing h-irAEs after ICIs are scarce and therefore definitive conclusions cannot be drawn. Our first patient received nivolumab for metastatic renal cell carcinoma and developed autoimmune thrombocytopenia after 15 cycles of treatment and autoimmune hemolytic anemia after the 20th cycle. The second patient developed immune thrombocytopenia after two cycles of pembrolizumab maintenance due to metastatic squamous lung cancer. These cases provide additional information on the true incidence and spectrum of hematological manifestations during the use of immunotherapy. It is important that clinicians should remain alert for hematological

immune related AEs whilst treating patients with ICIs and treatment incorporated early and according to the existing guidelines.

References

- Hanahan D, Weinberg RA. Hallmarks of cancer: The next generation. *Cell*. 2011;144(5):646-74.
- Ira M, Coukos G, Dranoff G. Cancer immunotherapy comes of age. *Nature*. 2011;480(7378):480-9.
- Cohen EE, Soulières D, Le Tourneau C, Dinis J, Licitra L, Ahn MJ, et al. Pembrolizumab versus methotrexate, docetaxel, or cetuximab for recurrent or metastatic head-and-neck squamous cell carcinoma (KEYNOTE-040): A randomised, open-label, phase 3 study. *Lancet*. 2019;93(10167):156-67.
- Postow MA, Chesney J, Pavlick AC, Robert C, Grossmann K, McDermott D, et al. Nivolumab and ipilimumab versus ipilimumab in untreated melanoma. *N Engl J Med*. 2015;372(21):2006-17.
- Hall RD, Gadgeel SM, Garon EB, Bria E, Reck M, Vida J, et al. Phase 3 study of platinum-based chemotherapy with or without pembrolizumab for first-line metastatic, nonsquamous Non-Small Cell Lung Carcinoma (NSCLC): KEYNOTE-189. *J Clin Oncol*. 2016;34(15_Suppl):TPS9104.
- Boussiotis VA. Molecular and biochemical aspects of the PD-1 checkpoint pathway. *N Engl J Med*. 2016;375(18):1767-78.
- Krummel MF, James PA. CTLA-4 engagement inhibits IL-2 accumulation and cell cycle progression upon activation of resting T cells. *J Exp Med*. 1996;183(6):2533-40.
- Haanen JBAG, Carbone F, Robert C, Kerr KM, Peters S, Larkin J, et al. Management of toxicities from immunotherapy. ESMO clinical practice guidelines for diagnosis, treatment and follow-up. *Ann Oncol*. 2017;28(suppl_4):iv119-iv142.
- Brahmer JR, Lacchetti C, Schneider BJ, Atkins MB, Brassil KJ, Caterino JM, et al. Management of immune-related adverse events in patients treated with immune checkpoint inhibitor therapy: American Society of Clinical Oncology Clinical Practice Guideline. *J Clin Oncol*. 2018;36(17):1714.
- Michot JM, Bigenwald C, Champiat S, Collins M, Carbone F, Postel-Vinay S, et al. Immune-related adverse events with immune checkpoint blockade: a comprehensive review. *Eur J Cancer*. 2016;54:139-48.
- Postow MA, Sidlow R, Hellmann MD. Immune-related adverse events associated with immune checkpoint blockade. *N Engl J Med*. 2018;378(2):158-68.
- Reck M, Rodríguez-Abreu D, Robinson AG, Hui R, Csőszi T, Fülöp A, et al. Pembrolizumab versus chemotherapy for PD-L1-positive non-small-cell lung cancer. *N Engl J Med*. 2016;375(19):1823-33.
- Paz-Ares L, Luft A, Vicente D, Tafreshi A, Gümüş M, Mazières J, et al. Pembrolizumab plus chemotherapy for squamous non-small-cell lung cancer. *N Engl J Med*. 2018;379(21):2040-51.
- Motzer RJ, Rini B, McDermott DF, Redman BG, Kuzel TM, Harrison MR, et al. Nivolumab for metastatic renal cell carcinoma: Results of a randomized phase II trial. *J Clin Oncol*. 2015;33(1):1430.
- Jaime-Pérez JC, Aguilar-Calderon PE, Salazar-Cavazos L, Gómez-Almaguer D. Evans syndrome: Clinical perspectives, biological insights and treatment modalities. *J Blood Med*. 2018;9:171-84.
- Delaney N, Michot JM, Comont T, Kramkimel N, Lazarovici J, Dupont R, et al. Haematological immune-related adverse events induced by anti-PD-1 or anti-PD-L1 immunotherapy: A descriptive observational study. *Lancet Haematol*. 2019;6(1):e48-57.
- Davis EJ, Salem JE, Young A, Green JR, Ferrell PB, Ancell KK, et al. Hematologic complications of immune checkpoint inhibitors. *Oncologist*. 2019;24(5):584.
- Khan U, Ali F, Khurram MS, Zaka A, Hadid T. Immunotherapy-associated autoimmune hemolytic anemia. *JITC*. 2017;5(1):15.
- Tanios GE, Doley PB, Munker R. Autoimmune hemolytic anemia associated with the use of immune checkpoint inhibitors for cancer: 68 cases from the food and drug administration database and review. *Eur J Haematol*. 2019;102(2):157-62.
- Pföhler C, Eichler H, Burgard B, Krecké N, Müller CSL, et al. A case of immune thrombocytopenia as a rare side effect of an immunotherapy with PD1-blocking agents for metastatic melanoma. *Transfus Med Hemother*. 2017;44(6):426-8.
- Escudier B, Motzer R, Sharma P, Wagstaff J, Plimack ER, Hammers HJ, et al. Treatment beyond progression in patients with advanced renal cell carcinoma treated with nivolumab in CheckMate 025. *Eur Urol*. 2017;72(3):368-76.
- Cella D, Grünwald NP, Doan J, Dastani H, Taylor F, Bennett B, et al. Quality of life in patients with advanced renal cell carcinoma given nivolumab versus everolimus in CheckMate 025: A randomised, open-label, phase 3 trial. *Lancet Oncol*. 2016;17(7):994-1003.
- Weber JS, Hodi FS, Wolchok JD, Topalian SL, Schadendorf D, Larkin J, et al. Safety profile of nivolumab monotherapy: A pooled analysis of patients with advanced melanoma. *J Clin Oncol*. 2017;35(7):785-92.
- Zimmer L, Goldinger SM, Hofmann L, Loquai C, Ugurel S, Thomas I, et al. Neurological, respiratory, musculoskeletal, cardiac and ocular side-effects of anti-PD-1 therapy. *Eur J Cancer*. 2016;60:210-25.
- Reck M, Rodríguez-Abreu D, Robinson A, Hui R, Csőszi T, Fülöp A, et al. Updated analysis of KEYNOTE-024: Pembrolizumab versus platinum-based chemotherapy for advanced non-small-cell lung cancer with PD-L1 tumor proportion score of 50% or greater. *J Clin Oncol*. 2019;37(7):537-546.
- Herbst RS, Giaccone G, de Marinis F, Reinmuth N, Vergnenegre A, Barrios CH, et al. Atezolizumab for first-line treatment of PD-L1-selected patients with NSCLC. *N Engl J Med*. 2020;383(14):1328-39.
- Paz-Ares L, Luft A, Tafreshi A, Gumus M, Mazières J, Hermes B, et al. Phase 3 study of carboplatin-paclitaxel/nab-paclitaxel (Chemo) with or without pembrolizumab (Pembro) for patients (Pts) with metastatic squamous (Sq) non-small cell lung cancer (NSCLC). *J Clin Oncol*. 2018;36(Suppl 15):105.
- Haanen JBAG, Carbone F, Robert C, Kerr KM, Peters S, Larkin J, et al. Management of toxicities from immunotherapy. *Ann Oncol*. 2017;28(suppl_4):iv119-iv142.