



A Rare Warthin Tumor Occurring in Lacrimal Caruncle: A Case Report

Rui Liu, Liying Wang, Bentao Yang, Xin Ge and Jianmin Ma*

Department of Ophthalmology, Beijing Tongren Hospital, China

Abstract

We report a rare case of warthin tumor occurring in lacrimal caruncle. Upon review of the literature, we find only four cases of warthin tumor in eye, two cases in the caruncle, one case in lacrimal gland, and one in eyelid margin. We treated a 71-year-old woman who had a fish-like mass in the caruncle of the left eye for half a year. The pathological diagnosis of warthin tumor was made after surgical resection of the tumor. After local surgical resection, the patient was in complete remission.

Keywords: Warthin tumor; Lacrimal caruncle; Histopathological examination

Introduction

Warthin tumor, also known as papillary cystadenoma lymphomatosis, is a slow-growing benign epithelial tumor which has a strong association with smoking [1]. The disease is more common in middle-aged and elderly men than women; but as the number of female smokers' increases, the gap between men and women has also narrowed [2]. The tumor frequently occurs in the parotid gland and the extra parotid localization of Warthin tumor is very rare [3,4]. Upon review of the literature, we find only four cases of warthin tumor in the eye [5-8]. In addition, there are few reports on other rare sites, like throat, mouth and lip [9-11]. Here, we report a patient who had a warthin tumor in lacrimal caruncle.

Case Presentation

A 71 years old female patient presented a conjunctival mass in left inner can thus with some discomfort for half a year. The tumor was 0.4 cm pedunculated, vascular, and red-colored. Clinical examination of the right orbit was normal. Visual acuity of the right eye was 0.5 and the left eye was 0.1. The rest of the ocular examination showed no notable abnormality. She denied a history of smoking and other diseases. The Magnetic Resonance Imaging (MRI) examination of orbit showed an abnormal signal shadow in the epicanthus area of the left orbit and the lesion did not present with contrast enhancement (Figure 1a,1b). The preoperative diagnosis was conjunctival mass and the mass was completely removed after local surgical resection. The patient remained free of any local recurrence 24 months after surgery. Postoperative pathology reported a cystic cavity was composed of columnar epithelial cells and pleomorphic cells. There were some amorphous red staining components in the cavity. Immunohistochemical examination of tumor cells: cytokeratin 7(+), cytokeratin 8/18(+), Ki-67 index (1-2%), P16 (partially weak +), P63 (+). Therefore, the final pathological diagnosis was warthin tumor.

Discussion

Warthin's tumor is the most common bilateral and multifocal parotid gland tumor. However, the tumor reported in eye is mostly unilateral and isolated. Tumor with a history of growth and decline is feature of this disease [12]. As mentioned above, smoking is a risk factor in the neoplastic development of warthin tumor [2]. At the same time, this tumor is characterized by recurrence and malignant transformation, and the malignant rate is only 1% [13]. Malignant transformation can occur in lymphoid or epithelial component; the latter is more common. Sato et al. [14] reported that Warthin tumor can turn into Squamous cell carcinoma; other types include mucoepidermoid carcinoma, acidophilic cell carcinoma, adenocarcinoma, acinar cell carcinoma, Merkel cell carcinoma, and undifferentiated carcinoma. Lymphoid component can transform into diffuse large B-cell lymphoma or mucosa-associated lymphoma [13].

At present, the pathogenesis of warthin tumor is not clear, but there are two main theories. One is the theory of ectopic proliferation of salivary gland tissue, and the other is the theory of

OPEN ACCESS

*Correspondence:

Jianmin Ma, Department of Ophthalmology, Beijing Tongren Eye Center, Beijing Tongren Hospital, Capital Medical University, Beijing Ophthalmology and Visual Sciences Key Laboratory, Beijing 100730, China, E-mail: jmama@sina.com

Received Date: 29 Aug 2019

Accepted Date: 17 Sep 2019

Published Date: 23 Sep 2019

Citation:

Liu R, Wang L, Yang B, Ge X, Ma J. A Rare Warthin Tumor Occurring in Lacrimal Caruncle: A Case Report. *Clin Oncol.* 2019; 4: 1659.

Copyright © 2019 Jianmin Ma. This is an open access article distributed under the Creative Commons Attribution License, which permits unrestricted use, distribution, and reproduction in any medium, provided the original work is properly cited.

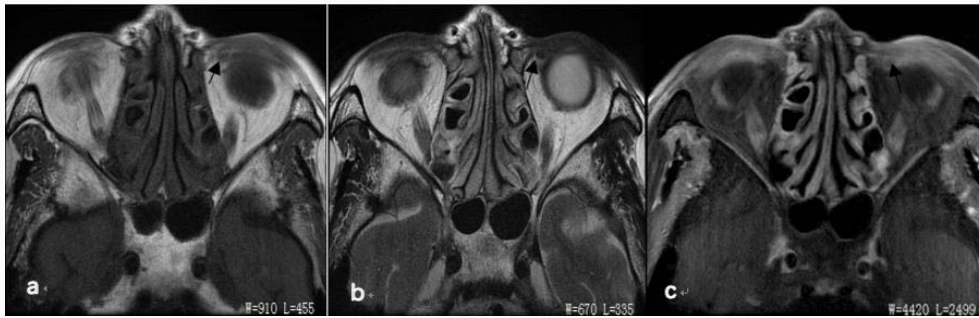

Figure 1a: MRI image of orbit (Transverse section).

(a) (indicated by the arrow) T1 weighted image showed a soybean mass in the left eye area, showing an equal and uniform signal; (b) (indicated by the arrow) T2 weighted image showed an abnormal signal shadow mass in the epicanthus area of the left eye, showing an equal and uniform signal; (c) (arrow) showed no obvious enhancement of the tumor.

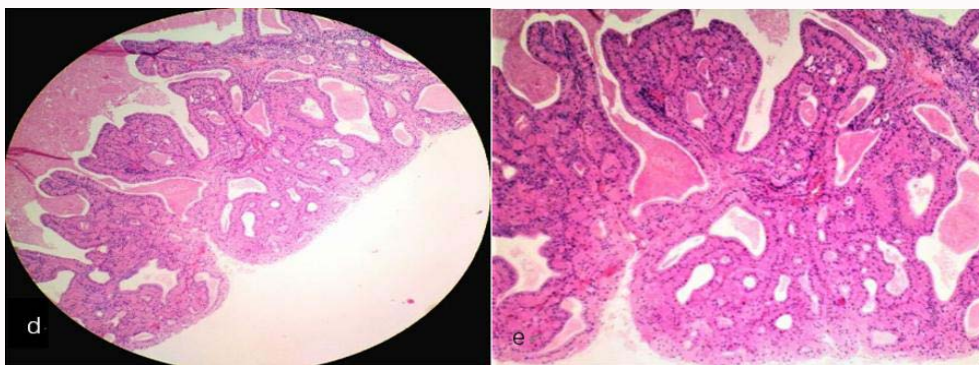


Figure 1b: The result of histopathological examination.

The figure d-e showed a cystic cavity composed of columnar epithelial cells and pleomorphic cells. There were amorphous red staining components in the cavity, and there were few interstitial lymphocytes, and the morphology conformed to Warthin tumor (d:HE, ×100; e:HE ×400).

Table 1: Summary of five cases of warthin tumor occurred in eyes.

Age	Gender	Eye	Position	Smoking	Treatment
65	Female	Right	Caruncle [5]	Unknown	Surgery
60	Male	Left	Eye lid [6]	Unknown	Surgery
90	Male	Right	Caruncle [7]	Non-smoking	Surgery
62	Female	Right	Lacrimal gland [8]	Unknown	Surgery
71	Female	Left	Caruncle	Non-smoking	Surgery

autoimmune disorder [15,16]. Most scholars agreed with theory of ectopic proliferation of salivary gland tissue in lymph nodes or lymphatic tissue. So far it has been believed that the onset of warthin tumors is the result of multiple factors.

Upon review of the literature, we obtain 4 cases of warthin tumor of eyes, and combine with the data of this case (Table 1). We find that there are two cases without a history of smoking, and three of the cases are unknown. These may indicate that there is no notable link between the history of smoking and warthin tumor occurring in eyes. The ages of three cases occurring in lacrimal caruncles are 65, 71 and 90 years old. We think that the age may be one of the possible reasons of the disease that occurs in lacrimal caruncles. With the increase of age, lacrimal caruncle becomes hypertrophy and the function declines, which increases the risk of developing tumors to some extent.

From a histological perspective, lacrimal caruncle is mainly composed of non-keratinized stratified squamous epithelium. However, the lining epithelial cells of warthin tumor are mainly tall,

columnar cells and cubic or polygonal epithelial cells. What causes the transformation of squamous epithelial cells in the lacrimal caruncle tissue? We guess this may be due to the loss of salivary gland tissue in lymph nodes or lymphatic tissue of caruncle.

At present, local excision completely is used for the treatment of Warthin tumors. Most patients have a good prognosis after surgical resection.

References

- Lamelas J, Terry JH, Alfonso AE. Warthin’s tumor: multicentricity and increasing incidence in women. *Am J Surg.* 1987;154(4):347-51.
- Park CK, Manning JT, Battifora H, Medeiros LJ. Follinle center lymphoma and Warthin tumor involving the same anatomic site. Report of two cases and review of the literature. *Am J Clin Pathol.* 2000;113(1):113-9.
- Yejun C, Nanyan L, Weihong Z, Cong L, Yiyang Z. The clinicopathological analysis of Warthin tumor of parotid gland (report of 56 cases). *Chinese Medical J.* 2004;39(8):33-4.
- Van der Wal JE, Devids JJ, van der Waal I. Extraparotid Warthin’s tumors: report of 10 cases. *Br J Oral Maxillofac Surg.* 1993;31(1):43-4.
- Oaks LW, Jenson BM. Warthin’s Tumor: Papillary cystadenomalympomatousum occurring in a human caruncle. *Am J Ophthalmol.* 1963;56(3):459-61.
- Mathur A, Mehrotra ML, Dhaliwal U. Warthin’s tumor of the eye lid. *Indian J Ophthalmol.* 1989;37(4):193.
- Zepeda, Moises R, Edward ML. Warthin’s tumor of the lacrimal caruncle. *Taiwan J Ophthalmol.* 2013;3(2):82-4.
- Bonavolontà G, Tranfa F, Staibano S, Di Matteo G, Orabona P, De Rosa G.

- Warthin tumor of the lacrimal gland. *Am J ophthalmol.* 1997;124(6):857-8.
9. Duek I, Paker M, Gil Z, Cohen JT. Warthin tumor of the larynx: A case report and review of the literature. *Ear Nose Throat J.* 2018;97(7):E8-E11.
 10. Saunders S, Igbokwe U, Harmse D. Warthin tumor of the buccal mucosa. *Br J Oral Maxill Surg.* 2008;46(4):332-3.
 11. Petrocelli M, Sbordone C, Salzano G, Orabona GD, Cassandro FM, Fusetti S, et al. Incidental finding of upper lip Warthin tumor. *Ann Ital Chir.* 2017;14(6):1-4.
 12. Guangyan Y. Clinical analysis of 100 cases of adenolymphoma. *J Modern Oral Med.* 1992;6:86-7.
 13. Yinuo J, Hongyan W, Yuan D, Zhe Y. Clinical and pathological observation of Warthin tumor epithelium into mucoepidermal carcinoma in 2 cases. *J Diagnostic Pathol.* 2016;23(3):186-9.
 14. Sato T, Ishibashi K. Multicentric Warthin tumor of the paraparotid region mimicking lymph node metastases of homolateral oral and oropharyngeal squamous cell carcinoma: reports of two cases. *J Oral Maxillofac Surg.* 1998;56(1):75-80.
 15. Yu G, Zou Z, Ma D. Comprehensive study on Warthin tumor of parotid gland. *Chinese J Oral Med.* 1995;34(5):187-9.
 16. Gallo O, Bociolini C. Warthin's tumor associated with autoimmune diseases and tobacco use. *Acta Otolaryngol.* 1997;117(4):623-7.