



A Giant Tumor that Grew for 17 Years in the Lower Back

Romain Salle^{1*}, Lydia Deschamps², Vincent Descamps¹ and Diane Kottler¹

¹Department of Dermatology, Bichat-Claude Bernard Hospital, France

²Department of Pathology, Bichat-Claude Bernard Hospital, France

Clinical Image

A 50-year-old female presented at the dermatology department with a giant cutaneous mass of the lower back that had grown progressively over the past 17 years. On physical examination, the lesion was firm by palpation, polypoid, ulcerated by location, and had a diameter of 27 cm (Figure 1). PET/CT revealed a hypermetabolic tumor of the lower back, with no other locations. After several non-contributory biopsies, surgical excision was performed, which revealed an exophytic tumor comprising numerous well-circumscribed solid nodules (Figure 2). Microscopic examination diagnosed a Proliferating Trichilemmal Tumor (PTT), thus ruling out a malignant neoplasm such as squamous cell carcinoma or Dermatofibrosarcoma Protuberans. The control PET/CT after 5 months of follow-up showed no signs of relapse or metastasis. PTT probably originates in the outer root sheath of the hair follicle, usually within a pre-existing trichilemmal cyst [1], and it encompasses a morphological spectrum including benign, atypical (intermediate), yet rarely malignant transformation [2].

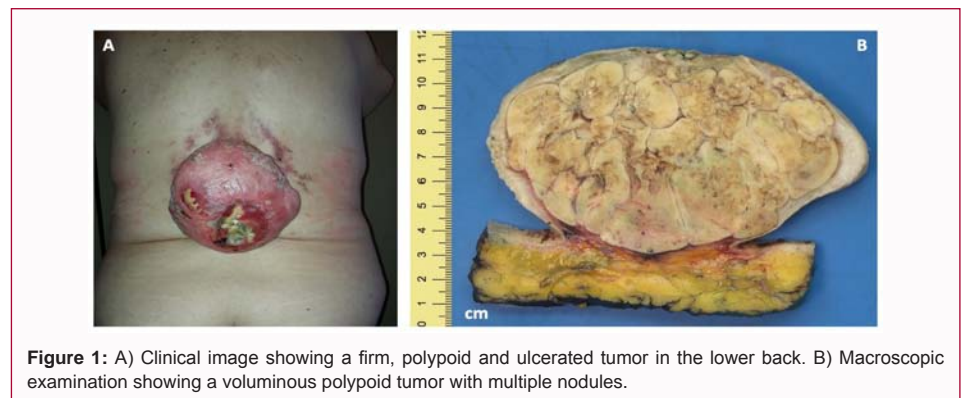


Figure 1: A) Clinical image showing a firm, polypoid and ulcerated tumor in the lower back. B) Macroscopic examination showing a voluminous polypoid tumor with multiple nodules.

OPEN ACCESS

*Correspondence:

Romain Salle, Department of Dermatology, Bichat-Claude Bernard Hospital, F-75018, Paris, France, Tel: 336-03-05-86-23;

E-mail: romain.salle@inserm.fr

Received Date: 21 Feb 2021

Accepted Date: 02 Mar 2021

Published Date: 05 Mar 2021

Citation:

Salle R, Deschamps L, Descamps V, Kottler D. A Giant Tumor that Grew for 17 Years in the Lower Back. *Clin Oncol.* 2021; 6: 1780.

Copyright © 2021 Romain Salle. This is an open access article distributed under the Creative Commons Attribution License, which permits unrestricted use, distribution, and reproduction in any medium, provided the original work is properly cited.

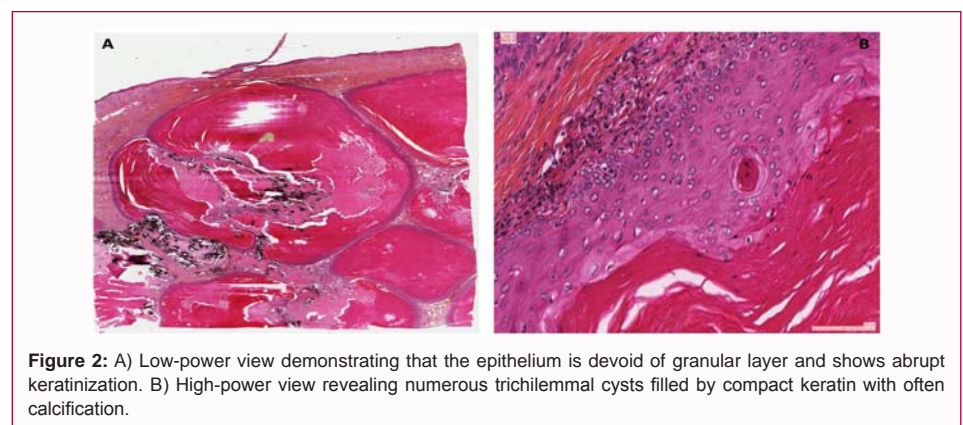


Figure 2: A) Low-power view demonstrating that the epithelium is devoid of granular layer and shows abrupt keratinization. B) High-power view revealing numerous trichilemmal cysts filled by compact keratin with often calcification.

References

1. Satyaprakash AK, Sheehan DJ, Sangüeza OP. Proliferating trichilemmal tumors: A review of the literature. *Dermatol Surg.* 2007;33(9):1102-8.
2. Ye J, Nappi O, Swanson PE, Patterson JW, Wick MR. Proliferating pilar tumors: A clinicopathologic study of 76 cases with a proposal for definition of benign and malignant variants. *Am J Clin Pathol.* 2004;122(4):566-74.