



^{99m}Tc-MDM SPECT Offers ‘Standard of Diagnostic Care’ in the Management of Glioma

Nisha Rani¹, Puja Hazari², Anil K Mishra² and Baljinder Singh^{1*}

¹Department of Nuclear Medicine, PGIMER, India

²Division of Radiopharmacy and Cyclotron, INMAS, India

Editorial

Glioblastoma Multiforme (GBM) is the most common primary brain tumor in adults. GBM is characterized by their appearance as solid tumours and mostly with the presence of a central necrosis. Although, GBM carries very poor prognosis but the management of the patients with the introduction of External Beam Radiation Therapy (EBRT) as adjunct to surgical resection and concomitant adjuvant chemotherapy has improved their prognosis significantly [1].

GBM tumours often recur despite using a multi-disciplinary approach for their treatment. These combinatory therapies undoubtedly deliver high amount of radiation dose that kill tumour cells within a target region but is often associated with undesirable side effects. Delayed radiation necrosis is one the most prominent side effects of this therapeutic modality that can manifest as a progressive contrast enhancement on follow-up Magnetic Resonance (MR) images. This does not allow a clear differentiation of necrosis from tumour recurrence which remains a clinical dilemma for the treating oncologists [1,2]. Moreover, due to the heterogeneous nature, there is a great interest in increasing the radiation dose to certain portion of the tumour while sparing normal tissue adjacent to tumor area [3].

Traditionally, the gold standard method to distinguish between radiation necrosis and recurrent tumour is a repeat (post-surgical) histological confirmation by biopsy or surgical resection which often is difficult especially in deep seated brain tumours. So, there is a need for a non-invasive imaging technique for accurate differentiation of tumour necrosis from recurrence as the conventional CT and MRI techniques may have conflicting results [4]. Advance MR techniques such as perfusion and diffusion MR Spectroscopy (MRS), Dynamic Susceptibility Contrast-Enhanced (DSCE) and SPECT/ PET imaging have been shown to be clinically useful in the detection of recurrent/residual tumour [5,6,7]. As malignant cells display an increased rate of amino acid uptake and metabolism, thus Positron Emission Tomography (PET) using radiolabeled amino acids holds great promise in detection of glioma recurrence/residual/necrosis. In particular, ¹¹C-L-methionine PET (MET PET), O-(2-¹⁸F-fluoroethyl)-L-tyrosine (¹⁸F-FET) PET provides useful information about glioma

OPEN ACCESS

*Correspondence:

Baljinder Singh, Department of Nuclear Medicine & PET, PGIMER, Chandigarh-160012, India, E-mail: drbsingh5144@yahoo.com

Received Date: 09 Mar 2017

Accepted Date: 20 Mar 2017

Published Date: 31 Mar 2017

Citation:

Rani N, Hazari P, Mishra AK, Singh B. ^{99m}Tc-MDM SPECT Offers ‘Standard of Diagnostic Care’ in the Management of Glioma. Clin Oncol. 2017; 2: 1252.

Copyright © 2017 Baljinder Singh. This is an open access article distributed under the Creative Commons Attribution License, which permits unrestricted use, distribution, and reproduction in any medium, provided the original work is properly cited.

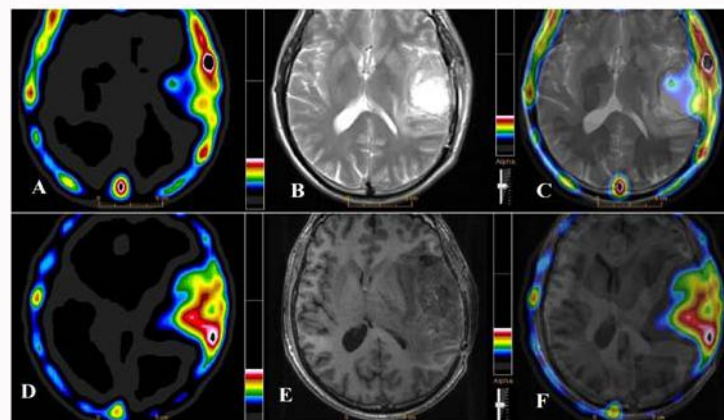


Figure 1: An increased uptake of ^{99m}Tc-MDM on SPECT image (A) in a 48 years old male GBM patient, contrast enhancement on CE-MR and fused SPECT/MR images (B & C) shown post surgical/chemo-radiotherapy (at 3-months) residual disease in the left temporal lobe. The subsequent SPECT (D), DSCE MR (E) and fused SPECT/MR images at 6-months follow-up indicated a significant disease progression in the corresponding region of the brain.

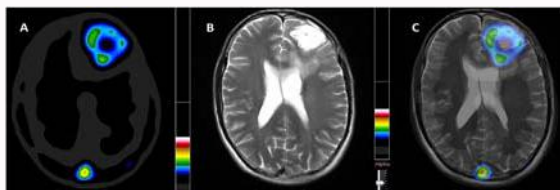


Figure 2: An increased ^{99m}Tc -MDM uptake SPECT (A), contrast enhancement on CE-MR and fused SPECT/MR images (B & C) indicating metabolically active GBM disease pre-operatively in a 39 years old male. ^{99m}Tc -methionine uptake (A) demonstrates metabolically active tumor in the rim with central necrotic mass. CE-MRI (B) indicates homogenous contrast enhancement in the entire tumor bed.

metabolism and has emerged as a promising tool in the management of glioma. Therefore, the amino acid based PET imaging combined with conventional imaging modalities can provide complementary diagnostic and therapeutic information and also can guide selective target tissue sampling or resection [6,8].

The widely used MET PET is limited by short half-life of 20-min of ^{11}C and requires in-house cyclotron facility. Furthermore, the radiolabeling of PET based tracers for glioma imaging is cumbersome and causes high radiation burden to the patients. Therefore, there is a clinical need for developing a more practical imaging method which can offer a cost effective substitute to glioma PET imaging. We have developed ^{99m}Tc -DTPA-bis methionine (^{99m}Tc -MDM) as single vial lyophilized kits ready to label 'with ^{99m}Tc ' and have standardized the clinical use of this imaging technique in glioma SPECT imaging [9,10]. Tumor uptake of ^{99m}Tc -MDM is similar (transport through LAT-1) to that of ^{11}C -MET. ^{99m}Tc -MDM concentrating preferentially in the metabolically active post surgical, post chemo-radiotherapy residual GBM disease and in the primary GBM tumor is presented in Figures 1 and 2.

Detection of metabolically active primary or residual/recurrent tumor and accurate delineation of tumor boundaries has clinical applications for targeted biopsies or radiation treatment planning. ^{99m}Tc -MDM SPECT may serve as a prognostic marker for glioma management including staging, restaging, defining Biological Tumor Volume (BTV) for high-dose radiotherapy boost and post treatment assessment and may provide a cost effective substitute for amino acid based PET imaging.

References

1. Stupp R, Mason WP, van den Bent MJ, Weller M, Fisher B, Taphoorn MJ, et al. Radiotherapy plus concomitant and adjuvant temozolomide for glioblastoma. *N Engl J Med.* 2005;352(10):987-96.
2. Shah AH, Snelling B, Bregy A, Patel PR, Tememe D, Bhatia R et al. "Discriminating radiation necrosis from tumor progression in gliomas: a systematic review what is the best imaging modality?" *J. Neurooncol.* 2013;112(2):141-152.
3. Iuchi T, Hatano K, Narita Y, Kodama T, Yamaki T, Osato K. Hypofractionated high-dose irradiation for the treatment of malignant astrocytomas using simultaneous integrated boost technique by IMRT. *Int J Radiat Oncol Biol Phys.* 2006;64(5):1317-1324.
4. Deng SM, Zhang B, Wu YW, Zhang W, Chen YY. Detection of glioma recurrence by ^{11}C -methionine positron emission tomography and dynamic susceptibility contrast-enhanced magnetic resonance imaging: a meta-analysis. *Nucl Med Commun.* 2013;34(8):758-66.
5. Jenkinson MD, Du Plessis DG, Walker C, Smith TS. Advanced MRI in the management of adult gliomas. *Br J Neurosurg.* 2007;21(6):550-61.
6. Chen W. Clinical applications of PET in brain tumors. *J Nucl Med.* 2007;48(9):1468-81.
7. Alexiou GA, Zikou A, Tsiouris S, Goussia A, Kosta P, Papadopoulos A et al. Comparison of diffusion tensor, dynamic susceptibility contrast MRI and ^{99m}Tc -Tetrofosmin brain SPECT for the detection of recurrent high-grade glioma. *J Magn Reson Imaging.* 2014;32:854-859.
8. Weber WA, Wester HJ, Grosu AL, Herz M, Dzewas B, Feldmann HJ, et al. O-(2-[18 F] fluoroethyl)-L-tyrosine and L-[methyl-11 C] methionine uptake in brain tumours: initial results of a comparative study. *Eur J Nucl Med Mol Imaging.* 2000;27(5):542-549.
9. Hazari PP, Shukla G, Goel V, Chuttani K, Kumar N, Sharma R, et al. Synthesis of specific SPECT-radiopharmaceutical for tumor imaging based on methionine: ^{99m}Tc -DTPA-bis (methionine). *Bioconjugate Chem.* 2010;21(2):229-39.
10. Singh B, Kumar N, Sharma S, Watts A, Hazari PP, Rani N, Vyas S, et al. ^{99m}Tc -MDM Brain SPECT for the Detection of Recurrent/Remnant Glioma—Comparison With ceMRI and ^{18}F -FLT PET Imaging: Initial Results. *Clin Nucl Med.* 2015;40(10):e475-e479.