



Two Patients with Advance-Stage Renal Cell Carcinoma Developed Sunitinib-Related Skin Toxicity

Mehmet Cetinkaya^{1*}, Ozgur Tanriverdi², Hasan Deliktas¹, Asude Kara³, Yelda Dere⁴ and Hayrettin Sahin¹

¹Department of Urology, Mugla Sitki Kocman University, Turkey

²Department of Medical Oncology, Mugla Sitki Kocman University, Turkey

³Department of Dermatology, Mugla Sitki Kocman University, Turkey

⁴Department of Pathology, Mugla Sitki Kocman University, Turkey

Abstract

With the current treatment modalities like molecular targeted therapy, general survival rates have increased in patients with advanced-stage renal cell carcinoma. Sunitinib maleat is one of these drugs and its most frequently side effects are fatigue, diarrhea, hypertension, stomatitis, and hair hypo-pigmentation. Additionally, various dermatological side-effects may also be seen such as hand-foot syndrome, a yellowish color change to the face, splinter hemorrhage, erythematous reactions on the trunk, facial edema, facial erythematous changes, alopecia, acneiform rash on the face and dysesthesia in the scalp. Although sunitinib maleat-related scrotal skin toxicity is extremely rarely seen, it should not be forgotten that this side-effect can be easily managed. Herein, we report two cases with sunitinib maleat-related scrotal skin toxicity, which were diagnosed with advanced-stage renal cell carcinoma in this case report.

Keywords: Sunitinib; Kidney cancer; Scrotal cutaneous toxicity; Molecular targeted therapy

Introduction

With molecular targeted treatment, overall survival rates have been recently increased in patients with advanced-stage Renal Cell Carcinoma (RCC) [1]. Sunitinib maleat, an orally tyrosine kinase inhibitor, is one of these targeted molecules which have small molecular weight [1]. It is widely used in the treatment of patients with advanced-stage RCC, metastatic neuroendocrine carcinoma, and gastrointestinal stromal tumors [1,2].

Most frequently side-effects in patients using sunitinib maleat are fatigue, diarrhea, hypertension, stomatitis, and hair hypo-pigmentation [1-3]. Additionally, various dermatological side-effects may also be seen such as hand-foot syndrome, a yellowish color change to the face, splinter hemorrhage, erythematous reactions on the trunk, facial edema, facial erythematous changes, alopecia, acneiform rash on the face and dysesthesia in the scalp [1-3]. However, sunitinib maleat-related scrotal skin toxicity is rarely seen [3,4].

Herein, we report two cases with sunitinib maleat-related scrotal skin toxicity, which were diagnosed with advanced-stage renal cell carcinoma in this paper.

Case Presentation

Case 1

A 72-year old male, who have not previous disease other than controlled hypertension, presented with complaints of increasingly worsening shortness of breath and cough. A solid mass in the left kidney with showing heterogeneous contrast, its size was approximately 7 x 8 cm, was determined in Computerized Tomography (CT) as well as multiple lymph nodes in mediastinum and bilateral multiple nodules in pulmonary parenchyma. Moreover, he has widespread bone metastases in thoracic as well as lumbar vertebrae. Then biopsy was performed from the mass in the left kidney and it was diagnosed as a clear cell renal carcinoma.

After consultation with the Medical Oncology Department, the patient was started on treatment of interferon 2α. In the evaluation made after 3 months of treatment, progression of the disease was determined. Treatment was then started of 50 mg sunitinib maleat for 4 weeks every 6 weeks. On

OPEN ACCESS

*Correspondence:

Mehmet Cetinkaya, Department of Urology, Mugla Sitki Kocman University, Turkey, Tel: +905053117005; Fax: +9 0 252 2111345;

E-mail: drmemoly@yahoo.com

Received Date: 01 Nov 2016

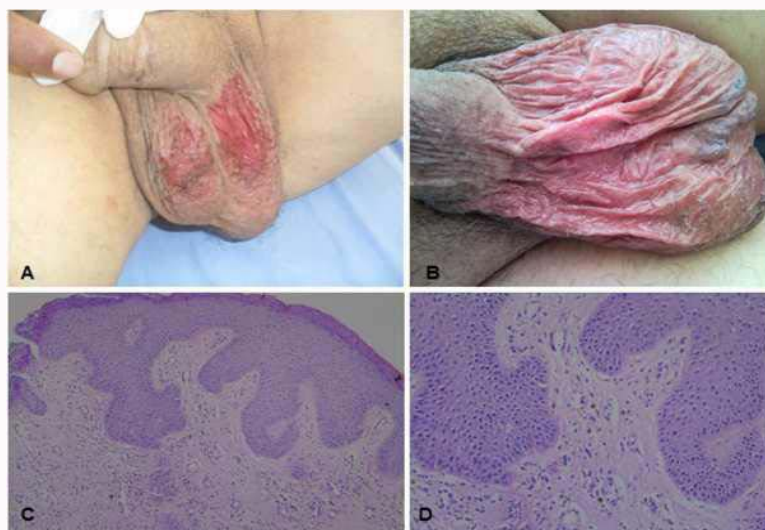
Accepted Date: 12 Dec 2016

Published Date: 31 Dec 2016

Citation:

Cetinkaya M, Tanriverdi O, Deliktas H, Kara A, Dere Y, Sahin H. Two Patients with Advance-Stage Renal Cell Carcinoma Developed Sunitinib-Related Skin Toxicity. *Clin Oncol*. 2016; 1: 1177.

Copyright © 2016 Cetinkaya M. This is an open access article distributed under the Creative Commons Attribution License, which permits unrestricted use, distribution, and reproduction in any medium, provided the original work is properly cited.



Figures: Macroscopic images and microscopic examination of sunitinib-related skin toxicity, **A-B:** Macroscopic image of Case 1 and Case 2, respectively showing live erythematous atrophic plaque with scattered desquamated areas clearly limited to the scrotum. **C-D:** Scrotum skin biopsy microscopic examination (HEX100, HEX200); interface dermatitis findings characterized by vacuolar degeneration in the basal layer and dyskeratotic cells with perivascular mononuclear inflammatory cells to the dermis, consistent with drug induced dermatitis.

the 24th day of treatment, the patient presented with a skin reaction on the scrotum, which was clearly defined with scattered desquamation areas in the form of erythematous atrophic plaque (Figure A). A biopsy was taken from the lesion. The sunitinib maleat treatment was halted and within 10 days the lesion completely recovered and the biopsy result was evaluated as drug reaction. The patient was re-started on the same treatment scheme and on the 16th day similar scrotal lesions developed and again when the sunitinib treatment was halted, the findings recovered. The patient was started on a treatment program of continuous sunitinib maleat at 25mg/day and apart from mild scrotal erythematous plaques which lasted approximately 1 week, no other skin reaction was observed. After approximately 7 treatment cycles, progression developed in pulmonary metastasis and with a worsening of general status the patient was lost 11 months after the diagnosis.

Case 2

A 77-year old male, who was previously healthy, presented with complaints of back and side pain which had been increasing for approximately 2 months. On the examination with CT, a lobular contoured solid mass in the right kidney with showing heterogeneous contrast, its size was 77 x 59 mm and bilateral multiple nodules in pulmonary parenchyma were determined as well as widespread bone metastases in scintigraphic examination. With right-side nephrectomy, a diagnosis was made of Grade T1 clear cell carcinoma limited to within the renal capsule, 6.5cm in size, of nuclear degree Fuhrman IV which had general necrosis and mitosis. Then interferon 2a treatment was initiated by the Oncology department. In the second month of treatment, intolerance and progression of pulmonary metastasis were observed and therefore the treatment was continued with 50mg/day sunitinib maleat for 4 weeks every 6 weeks. However, similar scrotal lesions, which were clearly defined with scattered desquamation areas in the form of erythematous atrophic plaque, developed on the 14th day of treatment (Figure B). The sunitinib maleat treatment was halted and within 10 days the lesion completely recovered and the biopsy result was evaluated as drug reaction. Treatment of 25mg/day continuous sunitinib maleat was started and no skin reaction was observed. The patient then

transferred to another centre for follow-up and as the patient could not be contacted; there is no further information available on the clinical course.

On dermatological examination, widespread erythematous atrophic plaques with scattered desquamation were observed on the scrotum (Figure A and B).

Histopathological examination showed interface dermatitis characterized by vacuolar degeneration in the basal layer and dyskeratotic cells with perivascular mononuclear inflammatory cells in the dermis and these findings were reported as consistent with drug induced dermatitis (Figure C and D).

Discussion

Although various dermatological side-effects have been seen in patients using sunitinib maleat, prevalence of its skin toxicity has been reported as nearly <15% in previous studies. Moreover, sunitinib maleat-related scrotal skin toxicity is extremely rare [1-4]. Sunitinib maleat-related scrotal skin toxicity was first described by Billemont et al. [3]. In a total of 40 RCC patients treated with sunitinib maleat, it was reported in only 5 (12%) patients that scrotal erythematous lesion developed accompanying desquamation. Subsequently, a case of sunitinib-related recurrent scrotal hemangiomas was reported by Tonini et al. [5].

Although the mechanism of scrotal cutaneous toxicity has not been clarified, Billemont et al. [3] hypothesized that the underlying mechanism of this toxicity could be the anti-angiogenic effect of sunitinib maleat. It is also thought that hypoxia-inducible factor -1α (HIF-1α) and Vascular Endothelial Growth Factor (VEGF) play an important role in sunitinib-related cutaneous toxicity. This view has been supported in studies showing an *in vitro* increase in plasma VEGF levels after treatment with sunitinib maleat in patients with RCC [3]. Moreover, in patients with psoriasis, it has been shown that HIF-1α was strongly unregulated and at the same time angiogenesis was induced by VEGF [6]. As a result, increased limited oxygen diffusion within the tissues in both normal and tumor, which could be explained by paradoxical hypoxia, could cause

an anti-angiogenic process.

In the most recent article on sunitinib maleat-related scrotal skin toxicity by Chou et al. [7] sunitinib maleat-related scrotal cutaneous toxicity was confirmed by biopsy as well as indicated that strongly stained with VEGF by immunohistochemically examination was determined in the endothelial cells of the dermal blood vessels in a 74-year old male patient with RCC. This was the first paper to show the relationship between VEGF and sunitinib maleat-related scrotal cutaneous side-effect. Chou et al. [7] showed that there was no staining with VEGF in normal scrotal tissue taken from a healthy male and thus concluded that VEGF played a significant role in sunitinib maleat-related scrotal skin toxicity.

Although cases presented in literature differ from each other in respect of sunitinib dose and application schedule, the scrotal cutaneous side-effect was observed to develop at 7-14 days after starting the medication [3,4,6]. This can suggest that there is no significant relationship between medication dosage and scrotal cutaneous toxicity. In our cases, the side-effects were observed after exposure to the drug, which is consistent with the data in literature. Similarly it has been reported that within a week of stopping the sunitinib treatment, cutaneous findings recovered. In the current cases, it was also seen that the cutaneous findings recovered one week after halting the sunitinib treatment.

The conclusion can be reached that the sunitinib-maleat related cutaneous side-effect recovers after stopping the medication and this side-effect can be easily managed with dose modification. Therefore, that scrotal cutaneous toxicity could develop but this is a manageable side-effect must be explained to patients receiving sunitinib-maleat treatment.

In conclusion, although rare in the follow-up of patients receiving sunitinib maleat treatment, scrotal cutaneous toxicity should not be forgotten as one of the dermatological side-effects which may be seen. When it is taken into account that a significant increase in survival rates is achieved, this side-effect can be considered not to play a significant role in discarding the medication.

References

1. Ara M, Pastushenko E. Antiangiogenic agents and the skin: cutaneous adverse effects of sorafenib, sunitinib, and bevacizumab. *Actas dermo-sifiliograficas*. 2014; 105: 900-912.
2. Rosenbaum SE, Wu S, Newman MA, West DP, Kuzel T, Lacouture ME. Dermatological reactions to the multitargeted tyrosine kinase inhibitor sunitinib. *Supportive care in cancer: Support Care Cancer*. 2008; 16: 557-566.
3. Billefont B, Barete S, Rixe O. Scrotal cutaneous side effects of sunitinib. *N Engl J Med*. 2008; 359: 975-976.
4. Iacovelli R, Mancini ML, Risi E, Palazzo A, Cortesi E. Genital and inguinal cutaneous toxicity in male and female patients treated with sunitinib. *International journal of dermatology*. 2012; 51: 221-222.
5. Tonini G, Intagliata S, Cagli B, Segreto F, Perrone G, Onetti Muda A, et al. Recurrent scrotal hemangiomas during treatment with sunitinib. *Journal of clinical oncology: J Clin Oncol*. 2010; 28: 737-738.
6. Simonetti O, Lucarini G, Goteri G, Zizzi A, Biagini G, Lo Muzio L, et al. VEGF is likely a key factor in the link between inflammation and angiogenesis in psoriasis: results of an immunohistochemical study. *Int J Immunopathol Pharmacol*. 2006; 19: 751-760.
7. Chou CY, Wang KH, Lin YH, Lin YT, Tsai HH. Sunitinib-induced scrotal cutaneous side-effect. *The Journal of dermatology*. 2013; 40: 67-68.