



Cystic Prostatic Carcinoma

Rajendra B. Nerli^{1*}, Ranjeet Patil¹, Vikas Sharma¹, Shridhar C. Ghagane² and Murigendra B. Hiremath²

¹Department of Urology, KLES Kidney Foundation, India

²Department of Biotechnology and Microbiology, Karnataka University, India

Abstract

We report a rare case of prostatic carcinoma associated with cystic degeneration. Cystic masses within the prostate are known. Benign cystic masses are more common and include congenital cysts of mullerian duct or mesonephric duct origin. Acquired cysts can be either retention cysts, parasitic or malignant in nature. Cysts accompanying prostatic carcinoma are moreover rare. The acute retention of urine in this patient brought to light this lesion.

Keywords: Cystic prostatic carcinoma; Histology; Prostatic cysts

Introduction

Cystic lesions of the prostate are well known, however most are benign in nature. Benign cystic lesions include Mullerian cysts, utricle, retention cysts in benign prostatic hyperplasia and even prostatic abscesses [1]. The presence of a cystic component in a solid tumor, usually represents degenerative process precipitated by ischemic necrosis with subsequent liquefaction [2]. Though cystic degeneration of cancers is a fairly common finding in cancers of other organs, very few cases of cystic prostatic cancer lesions have been described [2]. Belter and Dodson were the first to report in 1970 a papillary adenocarcinoma with ductal adenocarcinoma and endometrioid features that was presumed to arise from the prostatic utricle [3]. This was followed by a report by Llewellyn and Holthaus [3] about a moderately well differentiated adenocarcinoma with cyst formation. We report a case of cystic adenocarcinoma of the prostate identified on transrectal ultrasonography and confirmed on histopathological examination.

Case Report

A 72 years old male patient presented to the emergency services of the hospital with acute urinary retention. The patient was catheterized and evaluated. The patient had symptoms of lower urinary tract during the past one year. Digital rectal examination revealed a large cystic, non-tender swelling in the region of the prostate. Routine investigations were within normal limits. Serum PSA level was raised (100 ng/ml). Clinically a diagnosis of carcinoma prostate was made. Computed tomography of the kidney ureter bladder region revealed a well-defined pseudo-encapsulated rounded cystic lesion at posterior aspect of prostate in the midline measuring 6.5x5.4cm with multiple nodules in the wall (Figure 1).

The patient underwent transrectal sonography (Figure 2) and TRUS guided biopsy. Histopathologic examination of sections from the cyst roof showed a tumor composed of branching papillae with central fibrovascular cores lined by pseudostratified columnar cells showing anisonucleosis with basally located round enlarged nuclei, single prominent nucleolus and moderate amphophilic cytoplasm. Increased mitotic activity (~8-10/10hpf) was also noted. A diagnosis of prostatic adenocarcinoma was made. Metastatic workup (Bone scan) revealed evidence of multiple secondary's in the pelvic bones. In view of the stage IV disease, the patient was offered bilateral orchidectomy plus bicalutamide 50 mg/day orally. The patient is on close follow-up.

Discussion

Most of the cysts occurring in the prostate are benign and are clinically insignificant. Benign cysts are characterized by a smooth wall and regular outline. Prostatic abscesses are usually associated with clinical symptoms hence easy to diagnose. On ultrasonography prostatic abscesses appear periurethral in location and their non-homogenous echotexture corresponds to necrotic inflammatory debris. In contrast to this, the cysts associated with prostatic cancers have an irregular outline with projections of solid tissue invaginations.

OPEN ACCESS

*Correspondence:

Rajendra Nerli, Department of Urology, KLES Kidney Foundation, KLES Dr. Prabhakar Kore Hospital & M.R.C, Nehru Nagar, Belagavi, Karnataka 590010, India, Tel: 91-9886616317;

Fax: 91-0831-2470732;

E-mail: rbnerli@gmail.com

Received Date: 05 Oct 2016

Accepted Date: 07 Nov 2016

Published Date: 02 Dec 2016

Citation:

Nerli RB, Patil R, Sharma V, Ghagane SC, Hiremath MB. Cystic Prostatic Carcinoma. *Clin Oncol*. 2016; 1: 1154.

Copyright © 2016 Nerli RB. This is an open access article distributed under the Creative Commons Attribution License, which permits unrestricted use, distribution, and reproduction in any medium, provided the original work is properly cited.

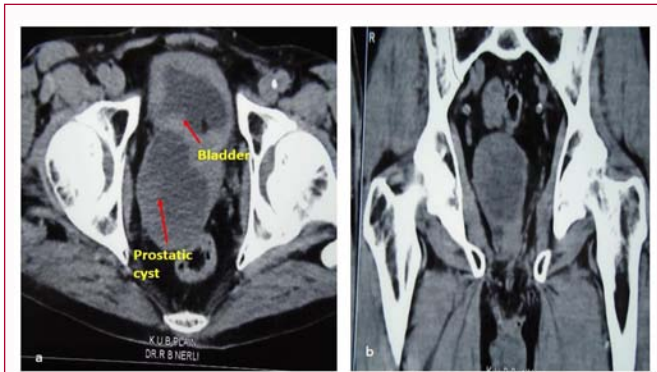


Figure 1: a) CT scan showing a cystic mass within the prostate of the size 6.5X5.4 cm. b) The content is not clear and the cyst wall shows areas of solid mass.

Malignancy associated with cystic lesions of the prostate are very rare. Both benign and malignant prostate neoplasm's may contain cystic components. Multilocular prostatic cystadenoma is a rare benign tumor that can grow to a large size causing significant lower urinary tract symptoms. However, prostatic adenocarcinoma may occasionally show cystic features. Other tumors of the prostate gland that exhibit cystic components include papillary cystadenocarcinoma and combined transitional cell/adenocarcinoma. Rarely, leiomyoma or liposarcoma in the prostate may have cystic elements. On the MRI, the heterogeneity of signal intensity of the cystic components and the presence of soft-tissue elements in the lesion indicate a neoplastic cause [4]. Aspirates from these cysts are usually haemorrhagic and contain malignant cells. The aspirate also shows a very high concentration of prostate specific antigen (PSA) and γ -seminoprotein [5].

The natural history of such cystic cancer of the prostate is not well studied/known. Therefore the management of these cases do not

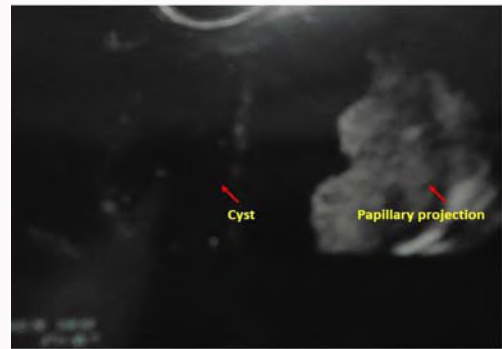


Figure 2: Trans-rectal ultrasonography reveals a cystic lesion in the prostate with left lateral wall of the cyst showing solid papillary projections.

differ from their solid counterparts as of now. The long term outcome and biologic course of these cystic carcinomas needs further study.

References

1. Ng KL, Sathiyathanan JR, Dublin N, Razack AH and Lee G. Cystic adenocarcinoma of prostate: a case report. JUMMEC 2011; 14: 21-22.
2. Walter JB, Israel MS. General pathology. 5thedn. New York. Churchill Livingstone. 1987; 386.
3. Christine H. Llewellyn, Lowrey H. Holthaus. Cystic carcinoma of the prostate: Findings on Transrectal Ultrasonography. AJR. 1991; 157: 785-786.
4. Curran S, Akin O, Agildere AM, Zhang J, Hricak H, Rademaker J. Endorectal MRI of Prostatic and Periprostatic Cystic Lesions and Their Mimics. AJR 2007; 188: 1373-1379.
5. Tsuji H, Hashimoto K, Katoh Y, Iguchi M. Prostatic cancer with huge cystic degeneration. Urologia Int. 1999; 62: 48-50.