



Mediastinal Cavernous Hemangioma in a Child with Pulmonary Hypertension

Rotaru N^{1*}, Maliga O¹, Crivcheanschii M¹, Codreanu I¹, Repin O² and Munteanu A³

¹Department of Radiology, State University of Medicine and Pharmacy Republic of Moldova, Moldova

²Department of Cardiac Surgery, Clinical Republican Hospital, State University of Medicine and Pharmacy Republic of Moldova, Moldova

³Department of Pathology, Clinical Republican Hospital, State University of Medicine and Pharmacy Republic of Moldova, Moldova

Abstract

We present a rare case of mediastinal cavernous hemangioma in a 9-year old girl with advanced pulmonary hypertension. Dynamic contrast enhanced computed tomography of the chest revealed a heterogeneous mass in the antero-superior mediastinum with multiple scattered calcifications, gradually increasing puddles of contrast enhancement and a dilated central vein draining into the superior vena cavae. Surgical resection was performed via median sternotomy. The central vein was ligated in close proximity to its draining point and the entire mass was carefully dissected and excised. The histopathological findings were consistent with cavernous hemangioma. Her postoperative course was uneventful and she was subsequently discharged. The cause of her pulmonary hypertension, however, remained uncertain and required further investigation.

Introduction

Cavernous hemangiomas (also known as cavernomas or cavernous angiomas) are developmental vascular malformations commonly considered as vascular hamartomas [1,2]. Usual locations are in the skin, subcutaneous tissue, brain, several viscerae and vertebral bodies [1,3]. Cavernomas within the lungs or mediastinum are very rare [1,4]. Hereby we present a rare case of mediastinal cavernous hemangioma in a child with advanced pulmonary hypertension.

Case Presentation

A 9-year old girl presented with exertional dyspnea that has been gradually increasing during the last year. On examination, her physical development and growth appeared normal for her age with no cyanosis, digital clubbing or peripheral edema. Chest auscultation revealed normal breath sounds and a louder S2 at the heart base.

Her chest X-ray revealed an abnormal mediastinal shadow, the findings being suspicious of a right upper mediastinal mass (Figure 1). Noncontrast enhanced computed tomography (CT) scan of the chest revealed a well-circumscribed ovoid mass in the antero-superior mediastinum, measuring 8.4 x 5.0 x 4.4cm (Figure 2). The content of the mass was heterogeneous with regions of nodular and tubular soft-tissue, liquid and fat attenuation as well as multiple scattered calcifications. Contrast-enhanced CT (following intravenous administration of 45 mL of Visipaque 320) demonstrated mild heterogeneous enhancement within the mass during the arterial phase (up to +80HU, Figure 3) with subsequent intensification during the venous phase (up to +130HU, Figure 4). A dilated central vein measuring 1.2cm in diameter was also seen draining directly into the superior vena cavae, the appearance being suggestive of a mediastinal hemangioma rather than teratoma. In addition, the pulmonary artery appeared prominently dilated (2.9cm in diameter versus 1.9cm for ascending aorta), the findings being highly suggestive of pulmonary hypertension (Figure 3 and 4). Catheterization of the right side of the heart revealed a systolic pressure in the right ventricle of 74 mmHg and resting systolic/diastolic/mean pulmonary arterial pressures of 60/34/46 mmHg, confirming the diagnosis of pulmonary hypertension. No intracardiac shunts were present.

Surgical resection was performed via median sternotomy. Intraoperatively the mass appeared well demarcated, located between the pericardium and right mediastinal pleura, encasing the right phrenic nerve and having a large central vein that was draining into the superior vena cavae. The central vein was ligated in close proximity to its draining point and the entire mass was carefully

OPEN ACCESS

*Correspondence:

Natalia Rotaru, Department of Radiology, State University of Medicine and Pharmacy "Nicolae Testemitanu" Chisinau, MD 2025, Moldova, E-mail: natalia.rotaru@usmf.md

Received Date: 01 Aug 2016

Accepted Date: 18 Aug 2016

Published Date: 09 Sep 2016

Citation:

Rotaru N, Maliga O, Crivcheanschii M, Codreanu I, Repin O, Munteanu A. Mediastinal Cavernous Hemangioma in a Child with Pulmonary Hypertension. *Clin Oncol.* 2016; 1: 1086.

Copyright © 2016 Rotaru N. This is an open access article distributed under the Creative Commons Attribution License, which permits unrestricted use, distribution, and reproduction in any medium, provided the original work is properly cited.

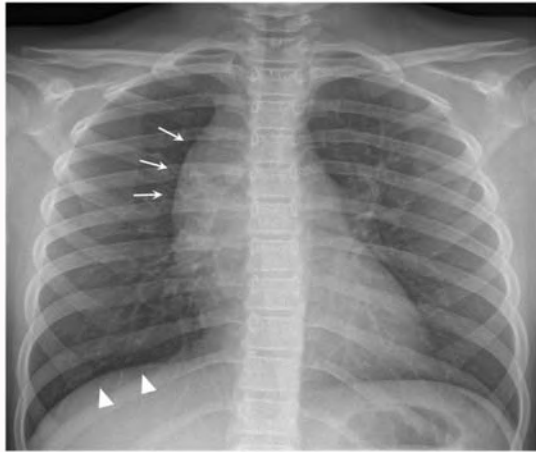

Figure 1: Chest X-ray in posteroanterior (PA) view showing a well-margined mass in the right upper mediastinum (arrows). Intraoperatively it has been found the mass was encasing the right phrenic nerve, which might be related to mildly elevated right hemidiaphragm (arrowheads).

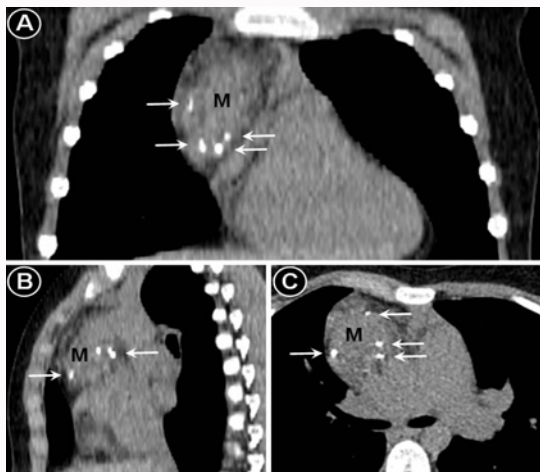


Figure 2: Noncontrast enhanced computed tomography of the chest showing a heterogeneous mass (M) in the antero-superior mediastinum with scattered calcifications pointed by arrows. Panel A – coronal view, panel B – sagittal view, panel C – axial view.

dissected and excised (Figure 5). The postoperative recovery was uneventful. A chest X-ray obtained in the early postoperative period is shown in Figure 6. The histological results of the excised mass revealed a cavernous hemangioma (Figure 7) and the patient was subsequently discharged.

Discussion

Mediastinal hemangiomas usually occur in children and young adults, up to 75% cases being registered before the age of 35 years [5-7]. Pre-operative diagnosis can be challenging, as the lesion usually manifests as a nonspecific mass [5,6,8,9]. Transthoracic core needle biopsy may be associated with significant bleeding complications [10,11], therefore medical imaging plays an important role in the management of these patients. When presenting as an anterior mediastinal mass, differential diagnosis is commonly made with other heterogeneous lesions such as teratoma, lymphoma or lymphangioma [5].

Even though many lesions can be appreciated at conventional radiography, computed tomography (CT) is the most important

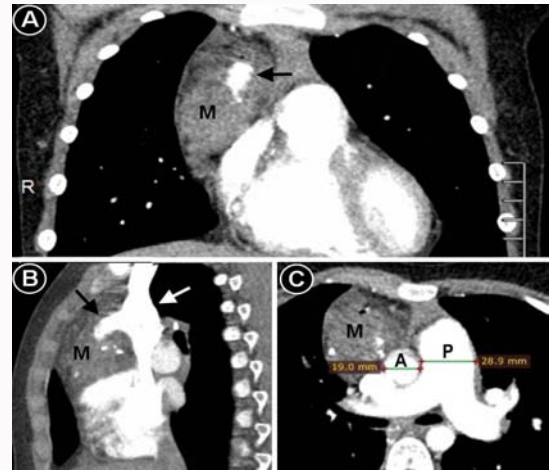


Figure 3: Arterial phase of contrast enhanced computed tomography showing only mild enhancement of the mediastinal mass (M). A large vein in the center of the mass (pointed by a black arrow) was filled with contrast retrogradely from superior vena cavae (pointed by a white arrow), the contrast being injected into a vein of the right arm. The pulmonary artery (P) appears prominently dilated compared to ascending aorta (A), the findings being consistent with pulmonary hypertension. Panel A – coronal view, panel B – sagittal view, panel C – axial view.

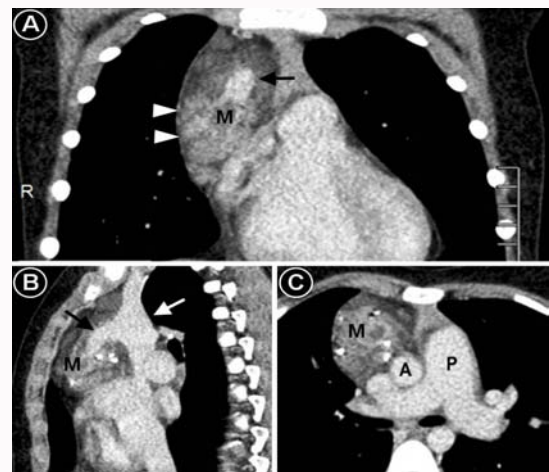


Figure 4: Venous phase of contrast enhanced computed tomography showing puddles of heterogeneous enhancement (arrowheads) within the mediastinal mass with a better visualization compared to arterial phase. A large vein in the center of the mass (pointed by a black arrow) is draining into superior vena cavae (pointed by a white arrow). The pulmonary artery (P) appears prominently dilated compared to ascending aorta (A). Panel A – coronal view, panel B – sagittal view, panel C – axial view.

tool in the evaluation of a mediastinal mass [12]. Several imaging features in our patient were highly suggestive of mediastinal hemangioma, avoiding the need for biopsy and potential bleeding complications. Scattered punctuate calcifications within the mass resembled the pattern seen in phleboliths. Although several patterns of calcification resembling that of teeth or bones can be seen in teratoma, phleboliths are virtually diagnostic of hemangioma [5,13]. A dilated central vein draining into the superior vena cava was also indicative of mediastinal hemangioma rather than teratoma. Slow, gradually increasing and prolonged contrast stains were similarly favoring a diagnosis of hemangioma, the characteristic “puddles” of enhancement after contrast administration being usually seen in the cavernous subgroup [5,8,10]. Mediastinal lymphoma can appear as a heterogenous mediastinal mass; however, calcifications in untreated

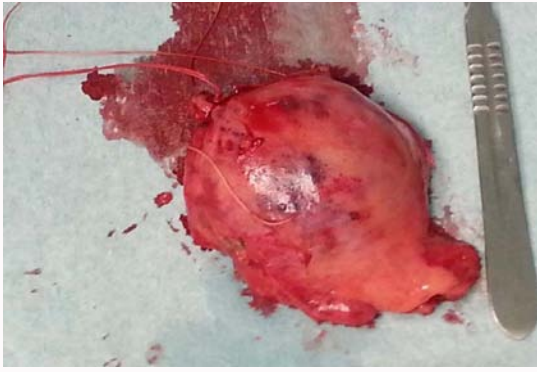


Figure 5: The excised mediastinal mass.

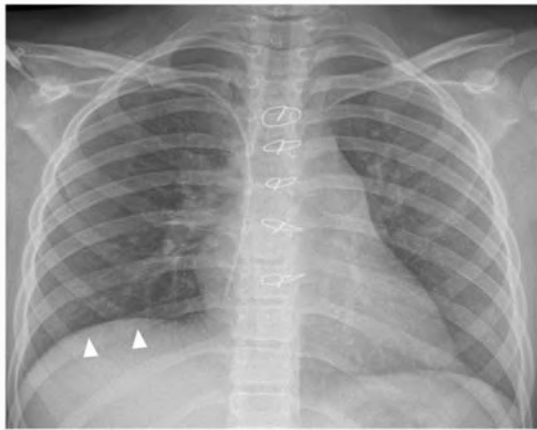


Figure 6: A chest X-ray obtained in the early postoperative period. The previously seen mediastinal mass (pointed by arrows in Figure 1) is no longer visualized. Elevation of right hemidiaphragm (arrowheads) is likely related to partial resection of the right phrenic nerve, which was encased by the mediastinal mass. Sternal wires after median sternotomy are also noted.

patients with lymphoma are exceedingly rare [5,14]. Lymphangiomas can also present as anterior or superior mediastinal masses; however they are commonly cystic lesions and calcifications are rather unusual [5,15]. Most lymphangiomas typically do not enhance after contrast administration, even though marked enhancement has been reported in certain lymphangiomas with associated hemangiomatous components or vascular aneurysms [5,15].

The choice of treatment is dependent on various factors such as related organ, clinical symptoms, depth of invasion and the vascular structure of the tumor, the size of hemangioma or interval progression and can include embolization, sclerotherapy, and surgical resection. Resection of mediastinal hemangiomas via video-assisted thoracoscopic surgery has also been reported [6,11,16]. In cases of resection, the lesion should be completely removed as relapses are directly related to incomplete resection [6,7,13]. Irradiation is not recommended as the needed radiation dose is very high and has severe potential complications especially in children [13]. Long-term clinical and radiological follow-up is recommended for early diagnosis of relapses [6,13].

Our patient was also referred for further evaluation and close monitoring of her pulmonary hypertension. Recent studies define pulmonary hypertension as an abnormal elevation of pressure in pulmonary circulation, with a resting mean pulmonary arterial pressure higher than 25 mmHg at catheterization of the right side

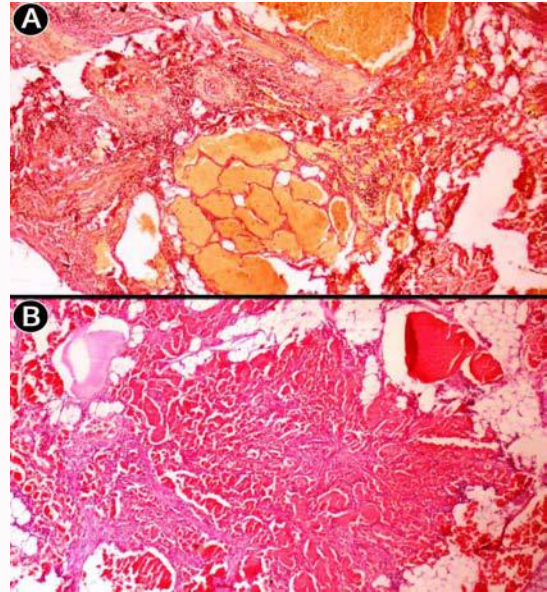


Figure 7: Histopathological findings of the excised mediastinal mass were consistent with cavernous hemangioma. A - Van Gieson's picrofuchsin staining (magnification $\times 10$) demonstrates large cavernous spaces and stromal vessels with an intervening fibrous interstitium. B - Hematoxylin and eosin (HE) staining (magnification $\times 20$) reveals multiple cavernous spaces separated by fibrous septa, smaller capillaries and congested vascular channels interconnected within a fibrous stroma.

of the heart, regardless of the underlying mechanism [17,18]. Pulmonary hypertension has been reported in patients with pulmonary hemangiomatosis [19]. Hemangiomas can also represent a potential source of recurrent pulmonary embolism [20,21]. In our patient the cause of her pulmonary hypertension remained uncertain and required further investigation.

References

- Saumench R, Barcia JA, Arnau A, Canto A. Combined thoracotomy and laminectomy for spinal cavernomas with intrathoracic growth. *Interact Cardiovasc Thorac Surg.* 2004; 3: 76-78.
- Saringer W, Nobauer I, Haberler C, Ungersbock K. Extraforaminal, thoracic, epidural cavernous haemangioma: case report with analysis of magnetic resonance imaging characteristics and review of the literature. *Acta Neurochir (Wien).* 2001; 143: 1293-1297.
- Badinand B, Morel C, Kopp N, Tran Min VA, Cotton F. Dumbbell-shaped epidural capillary hemangioma. *AJNR Am J Neuroradiol.* 2003; 24: 190-192.
- Kaya SO, Samancilar O, Usluer O, Acar T, Yener AG. Giant Cavernous Haemangioma of the Anterior Mediastinum. *Eurasian J Med.* 2015; 47: 216-217.
- Agarwal PP, Seely JM, Matzinger FR. Case 130: mediastinal hemangioma. *Radiology.* 2008; 246: 634-637.
- Roldan-Banos S, Garcia-Barajas S, Leon-Medina D. Cavernous hemangioma of the thymus. *Arch Bronconeumol.* 2012; 48: 303.
- Ose N, Kobori Y, Takeuchi Y, Susaki Y, Taniguchi S, Maeda H. Cavernous hemangioma in the thymus: a case report. *Surg Case Rep.* 2016; 2: 10.
- Nishikawa H, Osaki T, Tajima Y, Yoshimatsu T, Nagashima A, Yasumoto K. Hemangioma in the anterior mediastinum. *Jpn J Thorac Cardiovasc Surg.* 2003; 51: 442-444.
- Deepak J, Babu MN, Gowrishankar BC, Ramesh S. Mediastinal hemangioma: Masquerading as pleural effusion. *J Indian Assoc Pediatr Surg.* 2013; 18: 162-164.

10. Cheung YC, Ng SH, Wan YL, Tan CF, Wong HF, Ng KK. Dynamic CT features of mediastinal hemangioma: more information for evaluation. *Clin Imaging*. 2000; 24: 276-278.
11. Schreiner W, Sirbu H. Video-assisted technique for resection of a large mediastinal hemangioma. *Multimed Man Cardiothorac Surg*. 2010; 1: 2010(316): mmcts.2009.004135.
12. Juanpere S, Canete N, Ortuno P, Martinez S, Sanchez G, Bernado L. A diagnostic approach to the mediastinal masses. *Insights Imaging*. 2013; 4: 29-52.
13. Calisaneller T, Ozdemir O, Yildirim E, Kiyici H, Altinors N. Cavernous hemangioma of temporalis muscle: report of a case and review of the literature. *Turk Neurosurg*. 2007; 17: 33-36.
14. Alobeidy ST, Ilowite J, Donovan V, Selbs E, Badler R, Katz DS. Calcification in untreated mediastinal Hodgkin's lymphoma. *J Thorac Imaging*. 2001; 16: 304-306.
15. Shaffer K, Rosado-de-Christenson ML, Patz EF Jr, Young S, Farver CF. Thoracic lymphangioma in adults: CT and MR imaging features. *AJR Am J Roentgenol*. 1994; 162: 283-289.
16. Hirai K, Takeuchi S, Bessho R, Ohaki Y, Koizumi K, Shimizu K. Venous hemangioma of the anterior mediastinum. *J Nippon Med Sch*. 2010; 77: 115-118.
17. Pena E, Dennie C, Veinot J, Muniz SH. Pulmonary hypertension: how the radiologist can help. *Radiographics*. 2012; 32: 9-32.
18. Badesch DB, Champion HC, Sanchez MA, Hoeper MM, Loyd JE, Manes A, et al. Diagnosis and assessment of pulmonary arterial hypertension. *J Am Coll Cardiol*. 2009; 54: S55-66.
19. O'Keefe MC, Post MD. Pulmonary capillary hemangiomatosis: a rare cause of pulmonary hypertension. *Arch Pathol Lab Med*. 2015; 139: 274-277.
20. Yokosuka T, Yoshii S, Hosaka S, Suzuki S, Takahashi W, Osawa H, et al. Surgical treatment of chronic pulmonary thromboembolism caused by a cavernous hemangioma at the lower limb. *Kyobu Geka*. 2001; 54: 973-976.
21. Arkadopoulos N, Stafyla V, Karapanos K, Yiallourou AI, Koureas A, Kondi-Pafiti A, et al. Recurrent pulmonary embolism due to giant hepatic hamangioma treated with hepatectomy under vascular exclusion. *Ann Vasc Surg*. 2010; 24: 827.