Clinics in Oncology

Case Report
Published: 22 Jul, 2019

Utility of 11C-Methionine PET/CT in Preoperative Localization of a Parathyroid Adenoma in a Patient with Primary Hyperparathyroidism – Case Report and Literature Review

Violetta Rosiek[1]* and Beata Kos-Kudła[2]

[1]*Department of Endocrinology and Neuroendocrine Tumors, Medical University of Silesia, Poland*

[2]*Department of Pathophysiology and Endocrinology, Medical University of Silesia, Poland*

Abstract

Introduction: The most common cause of primary hyperparathyroidism is adenoma. In order to locate it, we perform a neck ultrasound followed by ^{99m}Tc-MIBI parathyroid scintigraphy. However, sometimes it is impossible to localize pathological parathyroid glands in these imaging examinations. Then, as a second-line imaging, PET/CT scan with 11C-Methionine or 18F-Fluorocholine should be considered.

Case Report: Fifty five-year-old patient with long-term history of recurrent nephrolithiasis, osteopenia, with primary hyperparathyroidism confirmed in biochemical and hormonal tests. ^{99m}Tc-MIBI parathyroid scintigraphy was performed twice (planar method+SPECT) and no parathyroid adenoma was found.

Subsequently, a PET/CT imaging with 11C-Methionine was performed in which an oval lesion measuring 7 mm × 9 mm was imaged behind the lower pole of the right thyroid lobe, suggesting a parathyroid adenoma.

Conclusion: We have shown that 11C-MET PET/CT is a reliable second-line imaging to locate the parathyroid adenoma when it cannot be located in the standard imaging (neck ultrasound, Tc-^{99m}-MIBI), before the planned minimally invasive parathyroidectomy.

Keywords: Primary hyperparathyroidism; 11C-methionine; PET/CT; ^{99m}Tc-MIBI parathyroid scintigraphy

OPEN ACCESS

****Correspondence:***
Violetta Rosiek, Department of Endocrinology and Neuroendocrine Tumors, Medical University of Silesia, 40-952 Katowice, ul. Ceglana 35, Poland, Tel: 032/3581366; E-mail: endoklin@sum.edu.pl

Received Date: *26 Jun 2019*
Accepted Date*: 17 Jul 2019*
Published Date*: 22 Jul 2019*

Citation:
Rosiek V, Kos-Kudła B. Utility of 11C-Methionine PET/CT in Preoperative Localization of a Parathyroid Adenoma in a Patient with Primary Hyperparathyroidism – Case Report and Literature Review. Clin Oncol. 2019; 4: 1641.

Introduction

Primary Hyperparathyroidism (PHPT) is the third most common endocrine disorder, with an incidence of approximately 4 (1-7) cases per 1000 people. The incidence increases with age (mostly after 50 years of age), and it is 2-3 times more frequent in women. The clinical picture may take various manifestations, from nausea, fatigue and mental disorders to severe osteoporosis, kidney stone disease or cardiovascular complications [1]. The diagnosis is confirmed by biochemical tests, with elevated calcium and Parathormone (PTH) levels, decreased serum phosphate levels associated with hypercalciuria. The most common cause of PHPT is abnormal, solitary adenoma (85%, multiple adenomas are less frequent) or parathyroid hyperplasia (15%) and, very seldom, parathyroid cancer (<1%) [2]. In patients with PHPT and significant symptoms of kidney damage (nephrolithiasis or nephrocalcinosis, creatinine clearance of <60 ml/min, hypercalciuria >400 mg/day with an increased risk of nephrolithiasis) or bone manifestations (spinal fracture, osteoporosis with T-score < -2.5), especially in younger patients (<50 years old), surgery should be the treatment of choice [3]. Over the last decade there has been a shift in the method of treating these patients, namely the currently preferred operative approach is minimally invasive parathyroidectomy, i.e. surgery directed to resect only one abnormal parathyroid gland, located previously with the use of available imaging techniques. This surgical method is associated not only with a shorter duration of surgery, but also with a lower rate of complications and a smaller incision size, and its effectiveness depends on–possibly the most accurate–location of pathological tissue in the parathyroid glands in imaging examinations [4,5]. Whenever it happens that, despite performed imaging examinations,

it is not possible to locate the parathyroid adenoma, conventional exploration of the neck is undertaken, with all four parathyroid glands being examined intraoperatively.

When it comes to the preoperative imaging examinations in the patients with primary hyperparathyroidism, neck ultrasound and parathyroid scintigraphy play a predominant role.

As for examinations in the field of nuclear medicine, there is an ongoing search for new radiotracers which are used mainly in Positron Emission Tomography (PET) [4].

The basic imaging examination in the preoperative assessment of patients with PHPT is neck ultrasound, where parathyroid adenomas are imaged as well-delineated, oval or oblong focal lesions, hypoechoic in comparison to the adjacent thyroid tissue. Occasionally, large focal lesions may have a polycyclic character or a heterogeneous structure; they may also contain fluid or calcifications. The sensitivity and the specificity of the neck ultrasound in the location of enlarged parathyroid glands amount to, subsequently, about 67% and 94% [6]. Diagnostic difficulties of this method may result from the small size adenomas, ectopic location, anatomical determinants of the patient and finally, intrathyroidal location [4,6].

Among the functional imaging techniques, parathyroid scintigraphy with the application of ^{99m}-Tc-sestaMIBI is the most commonly used in the imaging of parathyroid glands. Parathyroid scintigraphy can be performed using two techniques: a dual-phase method or a dual tracer (subtraction) method.

From the available literature data comparing the sensitivity of both scintigraphy techniques arises the necessity of their combined use in order to obtain the greatest accuracy of pre-surgical evaluation of the patients, since, despite the various modifications of imaging protocols in these methods; none of them has been proven superior. Increase in the sensitivity of parathyroid scintigraphy is connected with using pinhole collimators. The sensitivity and specificity of scintigraphy in detecting pathological parathyroid glands amount to, subsequently, 71% (63% to 84%) and 89% [7]. However, the combined use of ultrasound and scintigraphy allowed increasing the sensitivity and specificity of the method to 96% and 83%.

In some cases, the second-line imaging is Computed Tomography (CT), Magnetic Resonance Imaging (MRI) or Positron Emission Tomography/Computed Tomography (PET/CT).

A new 4D CT technique frequently helps the clinicians to distinguish adenomas from other structures of the neck. Its sensitivity is about 80%, depending on the study population [8-10]. The main flaw of this technique, which uses many phases, is the radiation exposure. MRI scan may also be used to localize parathyroid glands, with a sensitivity of approximately 82% [11].

Higher spatial and time resolution of PET in comparison to SPECT imaging allows for the detection of even the smallest pathological glands. In recent years, many researchers attempted to assess the effectiveness of new radiopharmaceuticals used in PET/CT imaging, including but not limited to 18F-fluorocholine and 11C-methionine. A meta-analysis by Kluijfhout et al. [6] appeared in 2016, which concerned the use of PET and–in particular - L-(11c) Methionine (11C-met) PET/CT in the diagnostics of pathological parathyroid glands [6]. An update of imaging techniques involving nuclear medicine, including the use of Methionine (11c-met) PET/CT was brought by the study by García-Talavera San Miguel P et al. [12], which appeared in March this year.

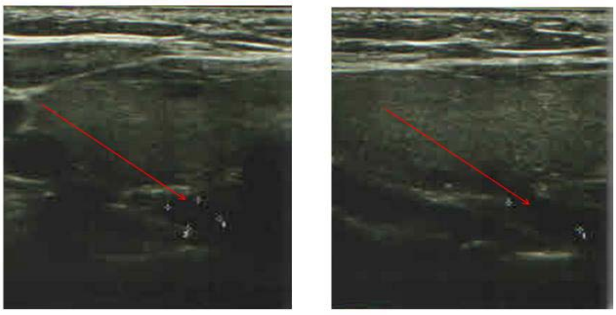

Figure 1: Thyroid gland ultrasound: a focal lesion measuring 7.9 mm × 5.6 mm × 7.8 mm below the lower pole of the right thyroid lobe.

Case Presentation

Fifty five-year-old female with long-term medical history of recurrent nephrolithiasis was twice surgically treated with the removal of left kidney stones (left-sided URSL and ESWT in 2013), which was followed by expanding the pelvicalyceal system of the left kidney due to urolithiasis of the upper left ureter (07.2014). The patient was referred to an endocrinologist for the first time in 12.2014, then, an elevated serum calcium level was measured. In further tests conducted by the endocrinologist, the biochemical disturbances typical for primary hyperparathyroidism were revealed (hypercalcemia: total serum calcium 2.7 mmol/l, ionized serum calcium 1.47 mmol/l, hypophosphatemia: serum phosphate 0.74 mmol/l and high parathyroid hormone level: 412.9 pg/ml). Furthermore, vitamin D3 deficiency was found and despite its successful pharmacological treatment, the levels of parathyroid hormone and calcium were still increased. In the bone densitometry scan from 06.2015 - osteopenia (T-score -2.1). The patient did not report any gastrointestinal ailments.

In order to localize the parathyroid adenoma (as the main cause of primary hyperparathyroidism), the patient had a neck ultrasound in which a focal lesion measuring 7.9 mm × 5.6 mm × 7.8 mm was discovered below the lower pole of the right thyroid lobe (Figure 1). A lesion was subjected to fine-needle aspiration biopsy that was not possible due to its inaccessibility for the needle. In the course of further imaging diagnostics, the patient was referred for ^{99m}Tc-MIBI/planar method+SPECT/parathyroid scintigraphy (02.2015), in which 20 mCi of radiotracer was administered. In the static imaging performed 10 h and 2 h after administering ^{99m}Tc-MIBI and in SPECT imaging, no focal concentrations of the radiotracer in the neck area

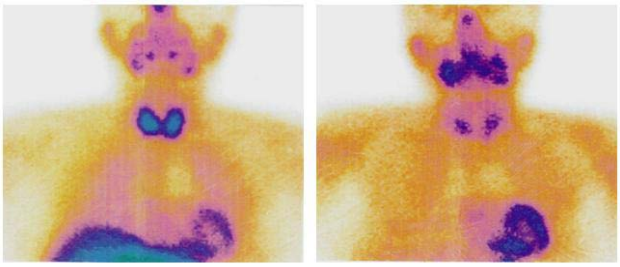

Figure 2: Dual-phase planar scintigraphy of parathyroid glands with ^{99}mTc-MIBI and SPECT 04.02.2015: 10' and 2 hours after administering radiotracer, no focal concentrations of the radiotracer in the neck area which could match a parathyroid adenoma were revealed.

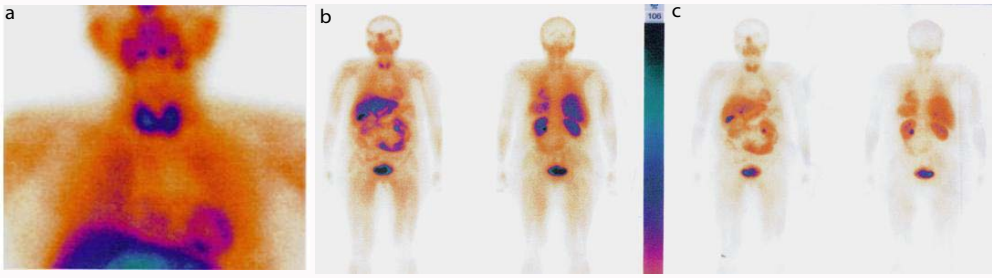

Figure 3a, 3b: Planar scintigraphy of parathyroid glands with ^{99}mTc-MIBI, SPECT and fusion with CT imaging 10.09.2015: no focal concentrations of the radiotracer in the neck and whole body area.

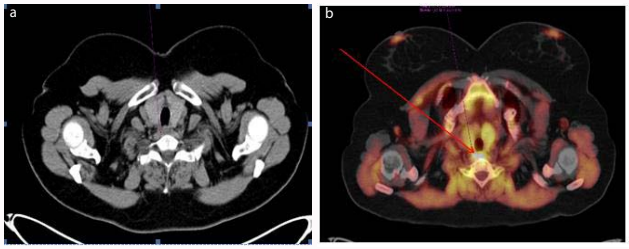

Figure 4a, 4b: PET/CT with 11C-methionine (04.04.2016): oval lesion measuring 7 mm × 9 mm, suggesting parathyroid adenoma.

which could match a parathyroid adenoma were revealed (Figure 2). Thereafter in September 2015 in the same Nuclear Medicine Department the extended parathyroid scintigraphy was repeated (planar method+SPECT+fusion with CT imaging), 20 mCi of ^{99m}Tc-MIBI was administered and, as previously, in the static imaging performed 10 h and 2 h after administering radiotracer and in SPECT imaging, no focal concentrations of ^{99m}Tc-MIBI in the neck and whole body area which could match a parathyroid adenoma were revealed (Figure 2b and 3a). Thus, in this dual-phase method imaging, the location of parathyroid adenoma was not determined. The patient was referred to a surgical consultation for parathyroidectomy; however, due to the planned surgery with conventional neck exploration, she did not consent to the procedure (fearing its negative effect or possible complications).

The patient was monitored for disturbances of calcium and phosphate metabolism while being treated pharmacologically (bisphosphonate, vitamin D3 preparation, furosemide), during the treatment PTH levels fell between 150 to 180 pg/ml and levels of ionized calcium were within the 1.45 to 1.56 mmol/l range.

In the course of further search for hyperactive parathyroid gland, PET/CT with 11C-Methionine was performed on 4.04.2016, in which an oval lesion measuring 7 mm × 9 mm, suggesting parathyroid adenoma was imaged behind the lower pole of the right thyroid lobe, tangentially against the right side of the esophagus (Figure 4a, 4b). The patient continued the pharmacological treatment and after the reconsultation with the results of aforementioned examinations, the patient was qualified for minimally invasive parathyroidectomy i.e. resection of the aforementioned lesion of the bottom right thyroid gland. The surgery took place on 18.04.2016, and the histopathological diagnosis of resected lesion was parathyroid adenoma.

Discussion

Hereby we present the case of a patient diagnosed with primary hyperparathyroidism and difficulties in diagnostic imaging that emerged due to the location of parathyroid adenoma.

In dual-phase ^{99m}Tc-MIBI parathyroid scintigraphy, which was performed twice, no focal concentrations of the radiotracer which could match a presence of parathyroid adenoma were revealed. These scans were performed using planar technique with SPECT (in the first imaging) and planar method+SPECT+fusion with CT imaging (in the second imaging).

According to the available literature data, the sensitivity of ^{99m}Tc-MIBI parathyroid scintigraphy is about 63% to 84% [6,7].

In the further location diagnostics of the parathyroid adenoma, the patient had 11C-MET PET imaging performed, in which a focal concentration of the radiotracer (measuring about 7 mm to 9 mm), suggesting an adenoma of bottom right parathyroid gland, was imaged behind the lower pole of the right thyroid lobe.

1174 studies from the available medical databases were qualified to the meta-analysis conducted by Kluijfhout et al. [6], of which 14 were dedicated to 11C-MET (327 patients with 364 abnormalities concerning parathyroid glands were analyzed). Collective sensitivity of this method in the detection of pathological parathyroid glands was proven circa 77% (70-86) [6].

In other authors' research assessing the sensitivity of 11C-Met PET, e.g. according to Caldarella et al. from 2012, it was even greater and amounted to 81% [13].

The 11C-Met PET efficiency was comparable to the conventional ^{99m}Tc-sestamibi SPECT (sensitivity 79%), but significantly lower in comparison to sestamibi SPECT/CT (sensitivity 88%) [14,15]. 11C-MET PET is the most suitable imaging test in patients with negative/incompatible with conventional imaging (neck ultrasound and MIBI parathyroid scintigraphy) and should therefore be considered as a second-line imaging method.

The effectiveness of 11C-Met PET in the diagnostics of hyper plastic parathyroid glands, according to literature data, was lower compared to patients with adenoma. In the largest study by Weber et al. [16], pooled sensitivity in the diagnostics of parathyroid adenomas was 83% compared with 33% for proliferative lesions. According to these scientists, in patients who underwent neck surgery (including the surgery of the thyroid); the sensitivity of this method was higher compared to the whole group (94 compared to 83%). Discrepancies in the assessment of the sensitivity of this diagnostic method may arise, among others, from the fact that the thyroid tissue which forms the background impedes interpretation of parathyroid scans through its physiological 11C-MET uptake [17]. Furthermore, acquisitions can be made at various intervals from the intravenous injection of radiotracer, depending on the examination protocol of the particular medical centre (immediately after the injection, in 10th and 40th

minute after the administration of radiopharmaceutical) [18,19]. Nonetheless, acquisitions after 40 min gave an insufficient number of counts, due to the short half-life of 11C-Met (20 min). Both short half-life and a complicated procedure of methionine labeling constitute a restriction of this method. Therefore, a centre must be equipped with a cyclotron, since its transport from another facility would take too much time. Some scientists also consider other factors which may contribute to the sensitivity in the location of parathyroid adenoma, such as concomitant goiter, thyroiditis, PTH and calcium levels.

In the current year a study by García-Talavera San Miguel P et al. [12], which constitutes an update of diagnostic methods of nuclear medicine in the preoperative location of focal lesion in the primary hyperparathyroidism, appeared. 11C-MET PET/CT is a procedure recommended for patients in whom other imaging techniques did not allow for locating pathological parathyroid gland [20-22]. Noltes et al. [23] examined 28 patients using this technique, preceded by the initial standard diagnosis (neck ultrasound and SPECT/CT with MIBI) which was negative or not allowing locating the lesion in the parathyroid glands.

PET/CT with methionine enabled a correct location of adenoma in 18 patients (sensitivity 72%) which resulted in shortening the duration of adenoma surgery and reduction of health care costs with regard to patients with false negative results [7]. Likewise, Weber et al. [24] examined 50 patients (57 glands), to conclude whether PET/CT with 11C-methionine is able to locate parathyroid adenomas not visible in MIBI. They demonstrated that this technique is effective in identification of hyperactive glands in 74% of patients. Overall, 70% of hyperactive adenomas were located, which allowed for a successful surgery.

In the meta-analysis by Caldarella et al. [25] 258 patients were examined in 9 studies. The pooled sensitivity and Detection Rate (DR) were 81 and 70% respectively, which implies that PET with methionine is a reliable and sensitive technique in patients suspected of having a parathyroid adenoma, whereas it is mostly useful if conventional imaging techniques are negative. Nonetheless, due to the limited availability of 11C-methionine and short half-life of 11C, it is rarely performed. To sum up, on the basis of meta-analysis by Kluijfhout et al. [6] and publication by García-Talavera San Miguel P et al. [12] as well as the clinical case described above, 11C-MET PET/CT appears to be a valuable addition in the diagnostics of parathyroid adenoma when it was not located in neck ultrasound and/or ^{99m}Tc-MIBI parathyroid scintigraphy [12,16].

Summary

According to our knowledge and based on update of the role of nuclear medicine techniques in the pre-surgical localization of primary hyperparathyroidism PET/CT scans are only recommended in cases of failure to locate pathological glands with scintigraphy or ultrasonography. 11C-MET PET/CT has been used for the detection of pathological parathyroid glands when it was not visualized in neck ultrasound and/or ^{99m}Tc-MIBI parathyroid scintigraphy and may be considered a reliable second-line imaging modality to enable minimally invasive parathyroidectomy.

References

1. Fraser WD. Hyperparathyroidism. Lancet. 2009;374(9684):145-58.
2. Choroby tarczycy i przytarczyc pod redakcją Jacka Gawrychowskiego i Barbary Jarząb. Medipage, 2014: 232.
3. Udelsman R, Åkerström G, Biagini C, Duh QY, Miccoli P, Niederle B, et al. The surgical management of asymptomatic primary hyperparathyroidism: proceedings of the Fourth International Workshop. J Clin Endocrinol Metab. 2014;99(10):3595–606.
4. Nieciecki M, Cacko M, Królicki L. The role of ultrasound and nuclear medicine methods in the preoperative diagnostics of primary hyperparathyroidism. J Ultrason. 2015;15(63):398-409.
5. Irvin GL, Carneiro DM, Solorzano CC. Progress in the operative management of sporadic primary hyperparathyroidism over 34 years. Ann Surg. 2004;239(5):704–708.
6. Kluijfhout WP, Pasternak JD, Drake FT, Beninato T, Gosnell JE, Shen WT, et al. Use of PET tracers for parathyroid localization: a systematic review and meta-analysis. Langenbecks Arch Surg. 2016;401(7):925-35.
7. Wei WJ, Shen CT, Song HJ, Qiu ZL, Luo QY. Comparison of SPET/CT, SPET and planar imaging using 99mTc-MIBI as independent techniques to support minimally invasive parathyroidectomy in primary hyperparathyroidism: A meta-analysis. Hell J Nucl Med. 2015;18(2):127-35.
8. Hunter GJ, Schellingerhout D, Vu TH, Perrier ND, Hamberg LM. Accuracy of four-dimensional CT for the localization of abnormal parathyroid glands in patients with primary hyperparathyroidism. Radiology. 2012;264(3):789-95.
9. Kukar M, Platz TA, Schaffner TJ, Elmarzouky R, Groman A, Kumar S, et al. The use of modified four-dimensional computed tomography in patients with primary hyperparathyroidism: an argument for the abandonment of routine sestamibi single-positron emission computed tomography (SPECT). Ann Surg Oncol. 2015;22(1):139-45.
10. Starker LF, Mahajan A, Bjorklund P, Sze G, Udelsman R, Carling T. 4D parathyroid CT as the initial localization study for patients with de novo primary hyperparathyroidism. Ann Surg Oncol. 2011;18(6):1723-8.
11. Sacconi B, Argirò R, Diacinti D, Iannarelli A, Bezzi M, Cipriani C, et al. MR appearance of parathyroid adenomas at 3 T in patients with primary hyperparathyroidism: what radiologists need to know for pre-operative localization. Eur Radiol. 2016;26(3):664-73.
12. García-Talavera San Miguel P, Gómez-Caminero López F, Villanueva Curto JG, Tamayo Alonso MP, Martín Gómez ME. Update of the role of Nuclear Medicine techniques in the pre-surgical localization of primary hyperparathyroidism. Rev Esp Med Nucl Imagen Mol. 2019;38(2):123-35.
13. Caldarella C, Treglia G, Isgro MA, Giordano A. Diagnostic performance of positron emission tomography using 11C-methionine in patients with suspected parathyroid adenoma: a meta-analysis. Endocrine. 2013;43(1):78-83.
14. Cheung K, Wang TS, Farrokhyar F, Roman SA, Sosa JA. A meta-analysis of preoperative localization techniques for patients with primary hyperparathyroidism. Ann Surg Oncol. 2012;19(2):577-83.
15. Treglia G, Sadeghi R, Schalin-Jäntti C, Caldarella C, Ceriani L, Giovanella L, et al. Detection rate of 99mTc-MIBI single photon emission computed tomography (SPECT)/CT in preoperative planning for patients with primary hyperparathyrodism: a meta-analysis. Head Neck. 2016;38(S1):E2159-72.
16. Weber T, Maier-Funk C, Ohlhauser D, Hillenbrand A, Cammerer G, Barth TF, et al. Accurate preoperative localization of parathyroid adenomas with C-11 methionine PET/CT. Ann Surg. 2013;257(6):1124–8.
17. Herrmann K, Takei T, Kanegae K, Shiga T, Buck AK, Altomonte J, et al. Clinical value and limitations of [11C]-methionine PET for detection and localization of suspected parathyroid adenomas. Mol Imaging Biol. 2009;11(5):356–63.
18. Martinez-Rodriguez I, Martinez-Amador N, de Arcocha-Torres M, Quirce R, Ortega-Nava F, Ibáñez-Bravo S, et al. Comparison of ^{99m}Tc-sestamibi and 11C-methionine PET/CT in the localization of parathyroid

adenomas in primary hyperparathyroidism. Rev Esp Med Nucl Imagen Mol. 2014;33(2):93–8.

19. Otto D, Boerner AR, Hofmann M, Brunkhorst T, Meyer GJ, Petrich T, et al. Pre-operative localisation of hyperfunctional parathyroid tissue with 11Cmethionine PET. Eur J Nucl Med Mol Imaging. 2004;31(10):1405-12.

20. Öksüz MO, Dittmann H, Wicke C, Müssig K, Bares R, Pfannenberg C, et al. Accuracy of parathyroid imaging: a comparison of planar scintigraphy, SPECT,SPECT-CT, and C-11 methionine PET for the detection of parathyroid adenomasand glandular hyperplasia. Diagn Interv Radiol. 2011;17(4):297-307.

21. Beggs AD, Hain SF. Localization of parathyroid adenomas using 11C-methioninepositron emission tomography. Nucl Med Commun. 2005;26(2):133-6.

22. Schmidt MC, Kahraman D, Neumaier B, Ortmann M, Stippel D. Tc-99m-MIBI-negative parathyroid adenoma in primary hyperparathyroidism detectedby C-11-methionine PET/CT after previous thyroid surgery. Clin Nucl Med. 2011;36(12):1153–5.

23. Noltes ME, Coester AM, van der Horst-Schrivers ANA, Dorgelo B, JansenL, Noordzij W, et al. Localization of parathyroid adenomas using 11C-methionine pet after prior inconclusive imaging. Langenbecks Arch Surg. 2017;402(7):1109–17.

24. Weber T, Gottstein M, Schwenzer S, Beer A, Luster M. Is C-11 methionine PET/CT able to localise sestamibi-negative parathyroid adenomas? World J Surg. 2017;41(4):980–5.

25. Caldarella C, Treglia G, Isgrò MA, Giordano A. Diagnostic performance of positronemission tomography using11C-methionine in patients with suspected parathy-roid adenoma: a meta-analysis. Endocrine. 2013;43(1):78-83.