Clinics in Oncology

Case Report
Published: 14 Nov, 2022

Two Cases of Thoracic SMARCA4-Deficient Undifferentiated Tumor: A Case Report

Zhang S[1], Xu W[2], Wu S[1], Chen M[1], Huang J[1], Sun Q[1] and Zhou Y[1]**

[1]Department of Radiation Oncology, First Affiliated Hospital, Bengbu Medical College, China

[2]Department of Pathology, First Affiliated Hospital, Bengbu Medical College, China

Abstract

Objective: To investigate the clinical and pathological features of thoracic SMARCA4-deficient undifferentiated tumor.

Methods: The clinical data, images, histopathological features, treatment regimens, and follow-up results of two cases of SMARCA4-deficient undifferentiated tumor diagnosed by clinicians at the First Affiliated Hospital of Bengbu Medical College were retrospectively analyzed.

Results: Both patients were male, aged 65 and 81 years, respectively, and both had a history of smoking. The images showed that both patients had lung masses and mediastinal enlarged lymph nodes. Histopathological analysis revealed that the tumor cells had a solid structure formed by epithelioid/rhabdoid cells, and the tumor cells were distributed in islands or scattered with extensively necrotic regions, and no evidence of epithelioid differentiation was observed. Immunohistochemical staining demonstrated that the cells were negative for SMARCA4 expression and positive for SOX2 and SMARCB1 expression. The overall survival rates of patients 1 and 2 were 12.0 and 3.2 months, respectively.

Conclusion: Thoracic SMARCA4-deficient undifferentiated tumor is a rare thoracic malignancy, and its diagnosis depends on histopathological and immunohistochemical analyses by experienced pathologists.

Keywords: Thoracic tumor; SMARCA4; Thoracic SMARCA4-deficient undifferentiated tumor; Immunohistochemistry

OPEN ACCESS

***Correspondence:**
Yufu Zhou, Department of Radiation Oncology, First Affiliated Hospital, Bengbu Medical College, Bengbu, Anhui 233004, China; E-mail: byyfyzyf@163.com
Qian Sun, Department of Radiation Oncology, First Affiliated Hospital, Bengbu Medical College, Bengbu, Anhui 233004, China; E-mail: sunqianby@163.com

Received Date: *17 Oct 2022*
Accepted Date*: 08 Nov 2022*
Published Date*: 14 Nov 2022*

Citation:
Zhang S, Xu W, Wu S, Chen M, Huang J, Sun Q, et al. Two Cases of Thoracic SMARCA4-Deficient Undifferentiated Tumor: A Case Report. Clin Oncol. 2022; 7: 1964.
ISSN: 2474-1663

Introduction

The Switch/Sucrose-Nonfermenting (SWI/SNF) chromatin remodeling complex (also known as the BAF complex) plays an important role in regulating transcription and consists of multiple protein subunits [1]. The BRG1 protein, which constitutes one of the subunits of the SWI/SNF chromatin remodeling complex, is encoded by the SMARCA4 gene located on chromosome 19p. The homologous subunit, which is comprised of the BRM protein with ATPase catalytic activity, is encoded by the SMARCA2 gene. The remaining subunits are SMARCB1 (INI1), ARID1A, and ARID1B [1]. Growing evidence suggests that these complexes have broad roles in tumor suppression. In recent years, inactivating mutations in the SWI/SNF complex subunits have been identified in a variety of cancers. In 2015, Loarer et al. [2] first reported cases of SMARCA4-deficient thoracic undifferentiated malignant tumors and described these tumors as similar to BAF-deficient sarcoma at the transcriptomic level. The authors defined this tumor type as "SMARCA4-Deficient Thoracic Sarcoma (SMARCA4-DTS)" [2]. Previous studies demonstrated that patients with SMARCA4-DTS have a wide age range (28 to 90 years old) [2-6] and the images showed compressive and infiltrative chest masses, most of which metastasized to adrenal glands, bones, and lungs at the initial diagnosis. The pathology exhibited epithelioid/rhabdoid morphological features, and the immunohistochemical staining was sensitive and specific. However, there is currently no effective treatment plan, and the prognosis is poor [2-8]. In 2021, the World Health Organization (WHO) re-named SMARCA4-DTS as "thoracic SMARCA4-deficient Undifferentiated Tumor (SMARCA4-UT)" and considered this tumor type to be a separate from SMARCA4-deficient non-small cell lung cancer [9]. It has been reported that SMARCA4-UT is caused by mutations in the SWI/SNF complex, which induce malignant rhabdoid tumors [10,11] and Small Cell Carcinoma of the Ovary Hypercalcemic Type (SCCOHT) [12-15]. This study reports two patients with SMARCA4-UT confirmed by immunohistochemical staining.

Case Presentation

Clinical features

Patient 1: A 65-years old men with a history of smoking (20+ years, 20 to 40 cigarettes/day), complained of "dry cough with facial edema for more than two months". Chest Computed Tomography (CT) showed a mass in the right upper lobe (about 5.7 cm × 1.7 cm) with multiple enlarged lymph nodes in the mediastinum and minimal effusion in the right pleural cavity (Figure 1A, 1B).

Patient 2: A 81-years old men with a history of smoking (50+ years, 20 to 40 cigarettes/day), complained of "pain in the right scapula for more than 1 month". Chest CT/Positron Emission Tomography (PET)/CT imaging showed a mass in the right lung apex with multiple enlarged lymph nodes in the right hilar and mediastinum, minimal effusion in the right pleural cavity, liver metastases, multiple bone metastases throughout the body, and soft tissue metastases in the iliac fossa of the right pelvis (Figures 1C-1E).

Histopathological features

The tissues of both patients were puncture specimens, and the morphology was similar under the microscope. By low-power microscopy, the tumor cells were arranged in solid sheets or islands and associated with large necrotic regions. Collagen fibers proliferated in some regions of the interstitium. By high-power microscopy, the tumor cells showed epithelioid or rhabdoid differentiation. In addition, they were rich in cytoplasm and eosinophilic, some nuclei were misplaced, Partial nuclei exhibited vesicular chromatin, and poor adhesion. Tumor cells showed large, hyperchromatic nuclei that were slightly pleomorphic, and strange giant cells with prominent nucleoli and easily visible mitotic features (Figures 2A-2D).

Immunohistochemical features

For patient 1, the results of immunohistochemistry showed the following: SMARCA4 (-), SMARCB1 (+), SOX2 (+), AE1/AE3 (a small amount of paranuclear staining), HMB45 (-), Desmin (-), CK (-), CK5/6 (-), CK7 (-), TTF-1 (-), S100 (-), Vim (3+), CD3 (-), CD20 (-), CD30 (-), CD34 (-), SALL4 (-), CD99 (-), and Ki-67 >30%.

For patient 2, the results of immunohistochemistry showed the following: SMARCA4 (-), SMARCB1 (+), SOX2 (+), AE1/AE3 (-), HMB45 (-), Desmin (-), CK (-), CK7 (-), TTF-1 (-), S100 (-), Vim (1+), CD34 (2+), CD45 (-), CD56 (-), Melan-A (-), MyoD1 (-), Syn (-), and Ki-67 (hot spot 3+, 70%) (Figures 2E-2H).

Treatment and follow-up results

Patient 1 received one cycle of intravenous chemotherapy of "cisplatin 60 mg D1–D2 + pemetrexed 0.85 g D1". The patient and his family refused further treatment. The patient's overall survival was 12.0 months.

Patient 2 underwent radiotherapy of the right lung (60 Gy/30 fr) and right scapula ((30 Gy/10 fr)). After radiotherapy, two cycles of "tislelizumab injection 200 mg 3w IV GTT + anlotinib hydrochloride capsules 12 mg d1-14 po" were given. The patient's overall survival was 3.2 months.

Written informed consent was obtained from the patient for the publication of all clinical data and images.

Discussion

SMARCA4-UT is a newly reported and extremely rare SMARCA4-deficient thoracic malignancy. Previous studies have demonstrated that SMARCA4-UT is a highly invasive malignant tumor. It is more common in adult male smokers, and is often accompanied by a history of emphysema/bulla [3,6,8,16-19]. Primary thoracic tumors include those of the chest wall, thoracic cavity, mediastinum, and lung. They are large, compressive, and infiltrative masses accompanied by an indeterminate number of necrotic lymph nodes. They easily metastasize and relapse, with initial metastasis to lymph nodes, bones, liver, brain and other organs [2-8,20]. Patients may have symptoms such as dyspnea, chest tightness, shoulder and back pain, pleural effusion, and superior vena cava syndrome. The effects of chemotherapy drugs are poor, and the median overall survival is 4 to 7 months [2,5,6,21]. The results of immunohistochemistry have demonstrated that this type of tumor has sensitivity and specificity, which is helpful in the diagnosis of SMARCA4-UT.

MARCA4-UT is characterized by the significantly decreased or lack of SMARCA4 (BRG1) expression [9]. In most cases, SMARCA2 is co-depleted, and SMARCB1 is positively expressed. Moreover, the stem cell markers SOX2, CD34, and SALL4 are positively expressed,

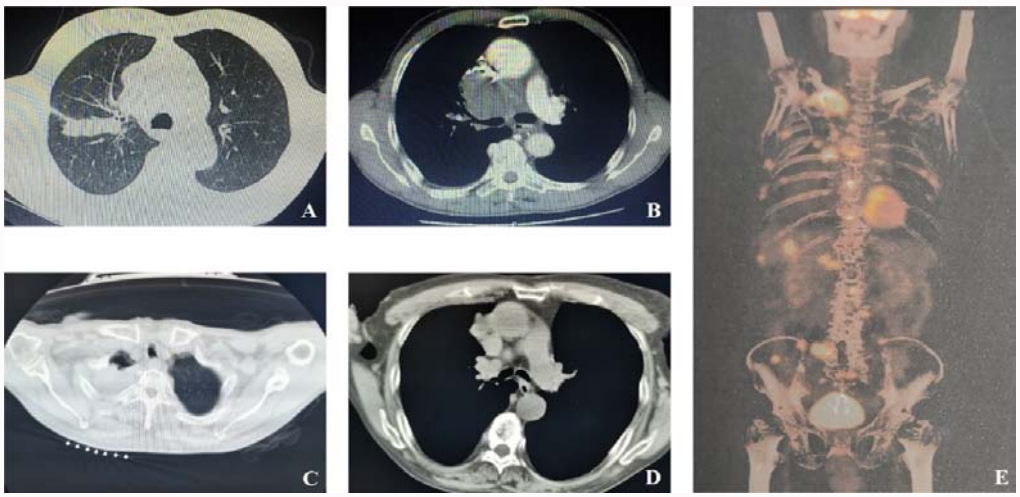

Figure 1: A, B: CT showing mass in the upper lobe of the right lung with multiple enlarged lymph nodes in the mediastinum. C, D: CT showing right lung apex mass with enlarged right hilar and mediastinal lymph node metastasis. E: PET-CT showing right lung apex mass with right hilar and mediastinal lymph node metastasis, right pleural metastasis, liver metastasis, right scapula, sternum, multiple ribs on both sides, spine, pelvic bones, femoral metastases, and soft tissue metastases in the right pelvic iliac fossa.

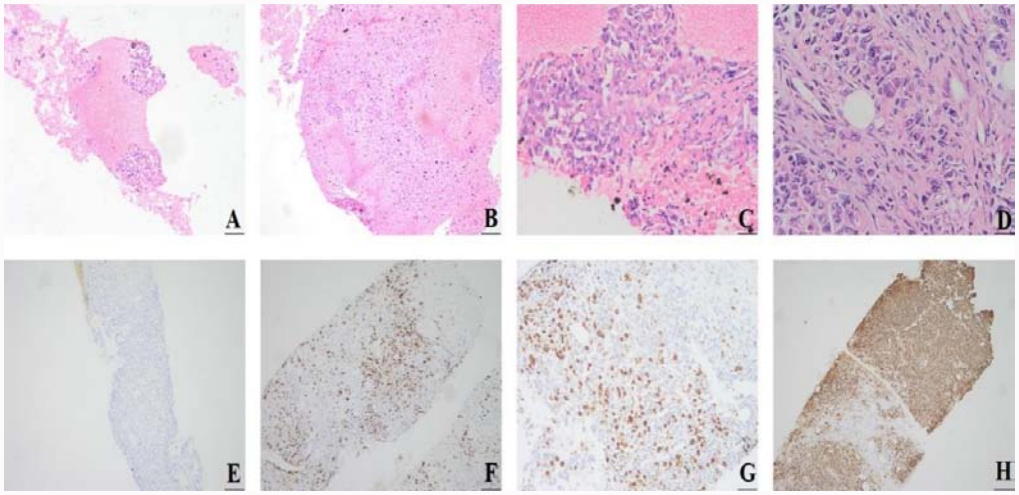

Figure 2: A: Distribution of tumor cells within islands (HE, x100); B: Large regions of necrosis within the tumor (x200); C, D: Tumor cells were epithelioid or rhabdomyoblast-like, with poor adhesion and visible nucleoli. Giant cells and mitotic features are easily visible (HE, x400) E: SMARCA4 tumor nuclei lacked expression (x100); F: SMARCB1 positive (x100); G: SOX2 positive (x200); H: CD34 strongly positive (x100).

and cytokeratin is usually focally/weakly expressed [2,4-6,9,16]. Previous studies have demonstrated that in malignant rhabdoid tumors with SMARCB1 or SMARCA4 deletion, SMARCB1-deficient epithelioid sarcoma, SMARCA4-deficient lung cancer, and other morphologically similar tumors such as SCCOHT, SOX2 staining was overwhelmingly negative [2,4-6]. Therefore, Loarer et al. [2] suggested that SOX2 serve as a surrogate marker of SMARCA4-UT. The immunohistochemical staining of both patients in this report were SMARCA4 (-), SMARCB1 (+), and SOX2 (+).

In conclusion, SMARCA4-DTS is a highly malignant tumor with a poor prognosis that needs to be differentiated from a variety of diseases. There are currently no effective systemic treatment options, and in the future, immune checkpoint inhibitors may become a potential treatment option for patients with SMARCA4-UT.

Acknowledgement

This research was funded by the Natural Science Research Project of Bengbu Medical College (Grant Number: 2020byzd068).

References

1. Wilson BG, Roberts CW. SWI/SNF nucleosome remodelers and cancer. Nat Rev Cancer. 2011;11(7):481-92.
2. Le Loarer F, Watson S, Pierron G, de Montpreville VT, Ballet S, Firmin N, et al. SMARCA4 inactivation defines a group of undifferentiated thoracic malignancies transcriptionally related to BAF-deficient sarcomas. Nat Genet. 2015;47(10):1200-5.
3. Crombe A, Alberti N, Villard N, Pilleul F, Buy X, Le Loarer F, et al. Imaging features of SMARCA4-deficient thoracic sarcomas: A multi-centric study of 21 patients. Eur Radiol. 2019;29(9):4730-41.
4. Perret R, Chalabreysse L, Watson S, Serre I, Garcia S, Forest F, et al. SMARCA4-deficient thoracic sarcomas: Clinicopathologic study of 30 cases with an emphasis on their nosology and differential diagnoses. Am J Surg Pathol. 2019;43(4):455-65.
5. Sauter JL, Graham RP, Larsen BT, Jenkins SM, Roden AC, Boland JM. SMARCA4-deficient thoracic sarcoma: A distinctive clinicopathological entity with undifferentiated rhabdoid morphology and aggressive behavior. Mod Pathol. 2017;30(10):1422-32.
6. Yoshida A, Kobayashi E, Kubo T, Kodaira M, Motoi T, Motoi N, et al. Clinicopathological and molecular characterization of SMARCA4-deficient thoracic sarcomas with comparison to potentially related entities. Mod Pathol. 2017;30(6):797-809.
7. Kuwamoto S, Matsushita M, Takeda K, Tanaka N, Endo Y, Yamasaki A, et al. SMARCA4-deficient thoracic sarcoma: Report of a case and insights into how to reach the diagnosis using limited samples and resources. Hum Pathol. 2017;70:92-7.
8. Matsushita M, Kuwamoto S. Cytologic features of SMARCA4-deficient thoracic sarcoma: A case report and comparison with other SWI/SNF complex-deficient tumors. Acta Cytol. 2018;62(5-6):456-62.
9. Nicholson AG, Tsao MS, Beasley MB, Borczuk AC, Brambilla E, Cooper WA, et al. The 2021 WHO classification of lung tumors: Impact of advances since 2015. J Thorac Oncol. 2022;17(3):362-87.
10. Rao Q, Xia QY, Wang ZY, Li L, Shen Q, Shi SS, et al. Frequent co-inactivation of the SWI/SNF subunits SMARCB1, SMARCA2 and PBRM1 in malignant rhabdoid tumors. Histopathology. 2015;67(1):121-9.
11. Schneppenheim R, Fruhwald MC, Gesk S, Hasselblatt M, Jeibmann A, Kordes U, et al. Germline nonsense mutation and somatic inactivation of SMARCA4/BRG1 in a family with rhabdoid tumor predisposition syndrome. Am J Hum Genet. 2010;86(2):279-84.
12. Foulkes WD, Clarke BA, Hasselblatt M, Majewski J, Albrecht S, McCluggage WG. No small surprise - small cell carcinoma of the ovary, hypercalcaemic type, is a malignant rhabdoid tumour. J Pathol. 2014;233(3):209-14.
13. Karnezis AN, Wang Y, Ramos P, Hendricks WP, Oliva E, D'Angelo E, et al. Dual loss of the SWI/SNF complex ATPases SMARCA4/BRG1 and SMARCA2/BRM is highly sensitive and specific for small cell carcinoma of the ovary, hypercalcaemic type. J Pathol. 2016;238(3):389-400.
14. Ramos P, Karnezis AN, Craig DW, Sekulic A, Russell ML, Hendricks WP, et al. Small cell carcinoma of the ovary, hypercalcemic type, displays frequent inactivating germline and somatic mutations in SMARCA4. Nat Genet. 2014;46(5):427-9.
15. Witkowski L, Carrot-Zhang J, Albrecht S, Fahiminiya S, Hamel N, Tomiak E, et al. Germline and somatic SMARCA4 mutations characterize small cell carcinoma of the ovary, hypercalcemic type. Nat Genet. 2014;46(5):438-43.
16. Chatzopoulos K, Boland JM. Update on genetically defined lung neoplasms: NUT carcinoma and thoracic SMARCA4-deficient undifferentiated tumors. Virchows Arch. 2021;478(1):21-30.
17. Iijima Y, Sakakibara R, Ishizuka M, Honda T, Shirai T, Okamoto T, et

al. Notable response to nivolumab during the treatment of SMARCA4-deficient thoracic sarcoma: A case report. Immunotherapy. 2020;12(8):563-9.

18. Kunimasa K, Nakamura H, Sakai K, Tamiya M, Kimura M, Inoue T, et al. Patients with SMARCA4-deficient thoracic sarcoma and severe skeletal-related events. Lung Cancer. 2019;132:59-64.

19. Kunimasa K, Okami J, Takenaka S, Honma K, Kukita Y, Nagata S, et al. Conversion surgery for advanced thoracic SMARCA4-deficient undifferentiated tumor with atezolizumab in combination with bevacizumab, paclitaxel, and carboplatin treatment: A case report. JTO Clin Res Rep. 2021;2(11):100235.

20. Stewart BD, Kaye F, Machuca T, Mehta HJ, Mohammed TL, Newsom KJ, et al. SMARCA4-deficient thoracic sarcoma: A case report and review of literature. Int J Surg Pathol. 2020;28(1):102-8.

21. Rekhtman N, Montecalvo J, Chang JC, Alex D, Ptashkin RN, Ai N, et al. SMARCA4-deficient thoracic sarcomatoid tumors represent primarily smoking-related undifferentiated carcinomas rather than primary thoracic sarcomas. J Thorac Oncol. 2020;15(2):231-47.