Clinics in Oncology

Mini Review
Published: 01 Dec, 2021

The Many Faces of the Chest Radiograph in COVID-19: A Pictorial Essay

Maria M D'souza[1], Jeanne Maria D'souza[2], Abhinav Jaimini[1], Pawan Kumar[1], Santosh Pandey[1], Sanjiv Kumar Saw[1], Yachna Solanki[1] and Prabhjot Kaur[1]*

[1]*Division of PET Imaging, Institute of Nuclear Medicine and Allied Sciences, India*

[2]*Kasturba Medical College, India*

Introduction

Within less than 3 months of its discovery, the Coronavirus Disease 2019 (COVID-19) was declared a global pandemic by the World Health Organization on March 11th, 2020 [1]. It has ravaged all parts of the world, infecting millions of people and claiming the lives of many. Cancer patients are at risk of higher mortality and morbidity from COVID infection. Not surprisingly, medical personnel from all disciplines have been involved in the management of this unprecedented emergency. The Chest Radiograph (CXR) has been the most widely used imaging investigation in COVID-19. Its wide availability, ease of use, repeatability, portability, low radiation burden and low cost has made it a popularly used modality across the globe throughout the pandemic. It is imperative that medical personnel should familiarize themselves with the imaging appearances of COVID-19 on the CXR. The purpose of this essay is to highlight the common CXR manifestations of COVID-19 through a series of images.

Learning Points

The CXR is presently the most widely used imaging investigation serving as a complementary tool in the diagnosis, triage and disease progression of COVID-19. It has a lower sensitivity as compared to CT, especially in the detection of early-stage disease [2]. However, with the current strain on resources and logistics imposed by the pandemic, its lower radiation burden, rapidity of scanning, feasibility of bedside use, ease of inter-scan decontamination, lower risk of cross-contamination and low cost have made it the most utilized imaging modality today. Nevertheless, it is important to note that as per the current guidelines of the Fleischner Society, the CXR or any other form of imaging is not routinely indicated in all patients suspected of COVID-19 or those with mild clinical features unless they are at risk for disease progression. It is indicated in a patient with COVID-19 and worsening respiratory status. In a resource constrained environment, it has also been recommended for medical triage of patients suspected with COVID-19, with moderate to severe clinical features and a high pretest probability of disease [3].

While the initial CXR may be normal, the disease could show progression with time, with peak radiological severity seen at days 10 to 12 of symptom onset [4]. Like other viral pneumonias, COVID-19 typically produces bilateral lung involvement. This is in contrast to bacterial pneumonias

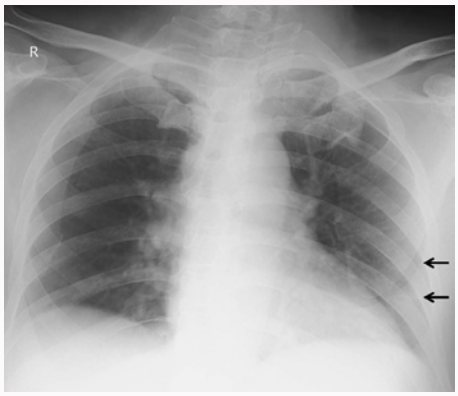

Figure 1: AP chest radiograph of 62-year-old male showing ground-glass opacification in periphery of left lower zone (arrows).

OPEN ACCESS

Correspondence:
Maria M D'souza, Division of PET Imaging, Institute of Nuclear Medicine and Allied Sciences, Brig SK Majumdar Marg, Delhi, 110054, India, E-mail: maria.md@rediffmail.com

Received Date: *24 Oct 2021*
Accepted Date*: 10 Nov 2021*
Published Date*: 01 Dec 2021*

Citation:
D'souza MM, D'souza JM, Jaimini A, Kumar P, Pandey S, Saw SK, et al. The Many Faces of the Chest Radiograph in COVID-19: A Pictorial Essay. Clin Oncol. 2021; 6: 1883.
ISSN: 2474-1663

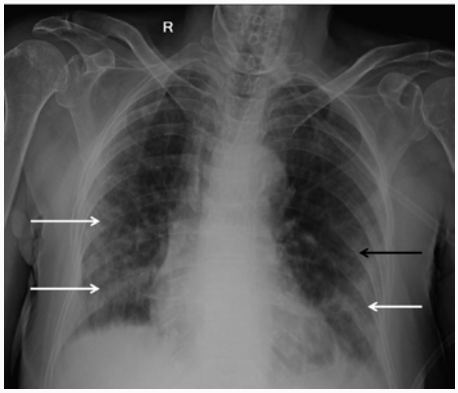

Figure 2: AP chest radiograph of 75-year-old female showing ground-glass opacification in left mid zone (black arrow) with admixture of GGO and consolidation in right mid, right lower and left lower zones (white arrows).

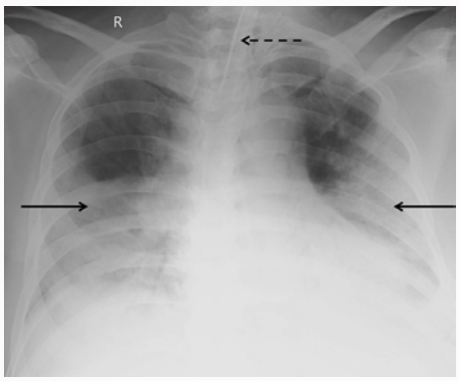

Figure 3: AP chest radiograph of 54-year-old male showing consolidation involving bilateral mid and lower zones (black arrows). Note the endotracheal tube *in situ* (dashed arrow).

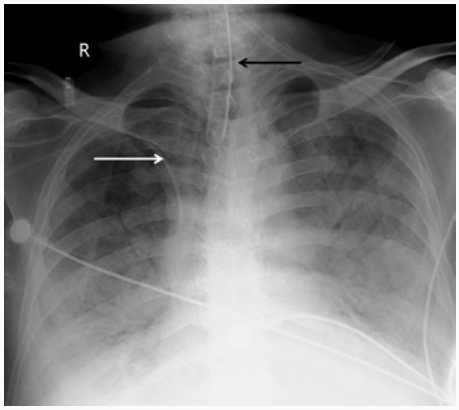

Figure 4: AP chest radiograph of 67-year-old female showing diffuse consolidation with air-bronchogram effect involving bilateral lung fields. Note the presence of endotracheal tube (black arrow) and CVP line (white arrow) *in situ*.

which usually produce unilateral, generally lobar involvement [5]. The initial pattern of involvement is typically peripheral and lower zone in distribution, which is replaced by a diffuse pattern as the disease progresses [6]. The earliest change is usually a subtle Ground Glass Opacification (GGO), which refers to an increased haziness in the lung fields (Figure 1), partially obscuring the underlying bronchovascular markings. This may be associated with peripheral, coarse white lines, bands or reticular changes [7]. With further progression, the

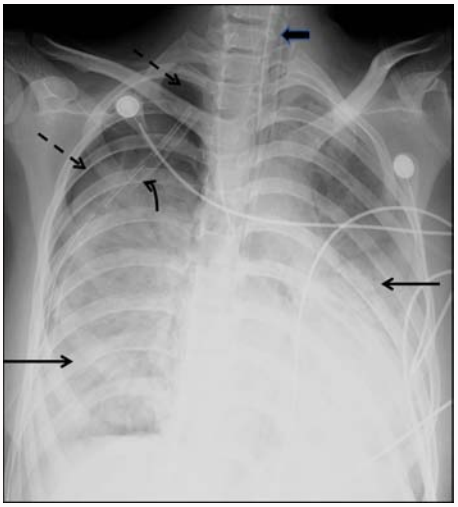

Figure 5: AP chest radiograph of 20-year-old female showing diffuse consolidation bilateral lung fields (black arrow) with a right sided pneumothorax devoid of bronchovascular markings (dashed arrow) with chest tube *in situ* (curved arrow). Also note the endotracheal tube *in situ* (block arrow).

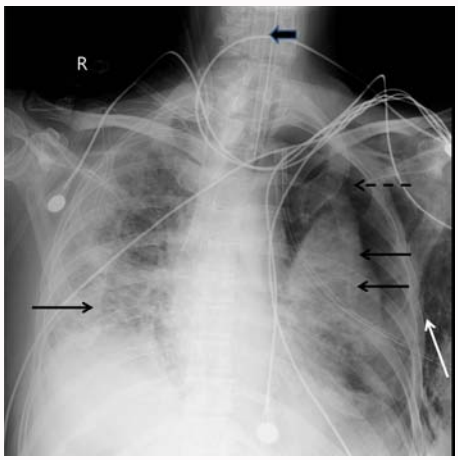

Figure 6: AP chest radiograph of 66-year-old male showing diffuse consolidation bilateral lung fields (black arrow). Note the left pneumothorax devoid of bronchovascular markings (dashed arrow), overlying the collapsed – consolidated left lung (double arrows). There is evidence of subcutaneous emphysema seen as air lucencies in the soft tissue (white arrow). Also note the endotracheal tube *in situ* (block arrow).

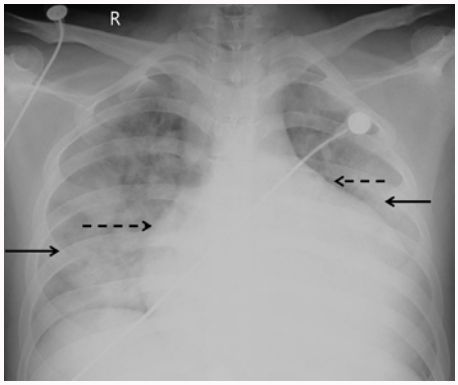

Figure 7: AP chest radiograph of 23-year-old male with dilated cardiomyopathy showing diffuse consolidation bilateral lung fields (black arrows). Note the gross cardiomegaly (dashed arrows).

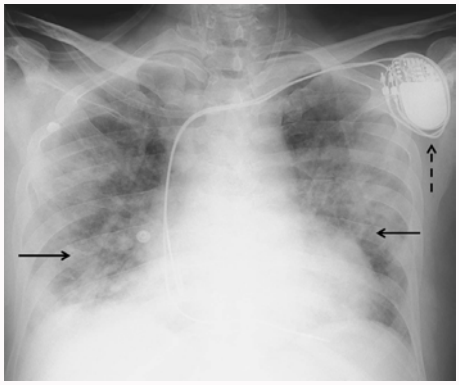

Figure 8: AP chest radiograph of 57-year-old male, known case of cardiac arrhythmia; with diffuse air space opacification bilateral lung fields (black arrows). Note the presence of pacemaker *in situ* (dashed arrow).

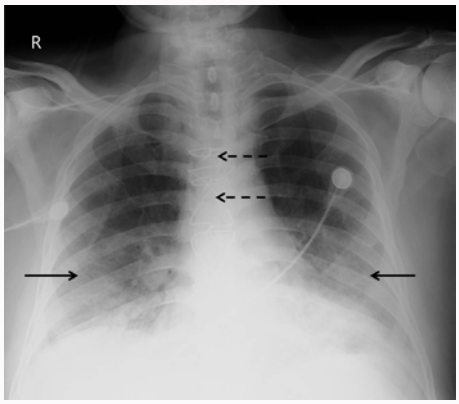

Figure 9: AP chest radiograph of 76-year-old male, known case of coronary artery disease (post CABG), with diffuse air space opacification bilateral mid and lower zones (black arrows). Note the presence of sternal sutures *in situ* (dashed arrow).

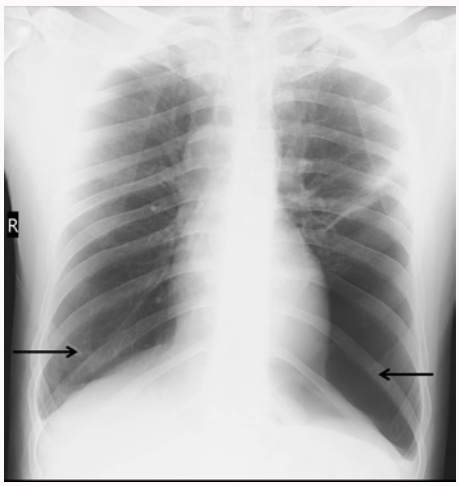

Figure 10: AP chest radiograph of 47-year-old male, known case of bullous emphysema. Note the large emphysematous bullae bilateral lower zones with paucity of bronchovascular markings (arrows). Although patient had no CXR manifestation of COVID pneumonia, he had prolonged hospitalization with supplemental oxygen administration.

subtle haze is replaced by increased opacification leading to complete obscuration of underlying bronchovascular markings (Figure 2). This is called consolidation, which may be accompanied by the air-

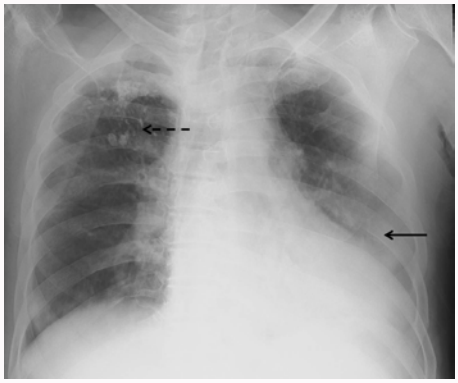

Figure 11: AP chest radiograph of 72-year-old male, known case of pulmonary tuberculosis with air space opacification involving left mid and lower zone (black arrows). Note the presence of fibro-infiltrative lesion with calcification in right upper zone (dashed arrow).

bronchogram effect (Figure 3, 4). This refers to the phenomenon of the radiolucent air-filled bronchi being made visible by the opacification of surrounding alveoli. Both GGO and consolidation may frequently co-exist on the same radiograph. Both constitute different forms of air space opacification, a term used when alveolar air is replaced by fluid, pus, blood, cells, or other material. Semi quantitative CXR scoring systems have been developed for the assessment of disease severity. The two widely established CXR scoring systems include the Brixia [8] and the Radiographic Assessment of Lung Edema (RALE) scoring systems [9].

Some of the well-recognized complications of COVID-19 which can be discerned on the CXR include the development of Acute Respiratory Distress Syndrome (ARDS), pneumothorax (Figure 5), pneumomediastinum and subcutaneous emphysema (Figure 6). These should be specially looked for in patients with a rapidly deteriorating clinical status. Additionally, the CXR may also provide an opportunity for the physician to detect the presence of co-morbidities especially those arising from the cardio-vascular (Figures 7-9) and respiratory system (Figure 10, 11). The presence of lung nodules, pleural effusions etc., are rare in COVID-19, and may point towards the presence of co-morbidities [7].

Clinical Significance

COVID-19 has a characteristic, though by no means specific pattern of radiographic involvement. The common pattern of evolution of CXR findings from GGO to consolidation, and from peripheral, lower zone predilection to diffuse spread enables the physician to assess disease progression and severity [10]. Thus, in addition to diagnosis and triage, the CXR has a significant predictive potential and may enable the identification of patients at risk of complications, who need urgent management [11].

References

1. Guan WJ, Ni ZY, Hu Y, Liang WH, Ou CQ, He JX, et al. Clinical characteristics of coronavirus disease 2019 in China. N Engl J Med. 2020;382(18):1708-20.

2. Balbi M, Caroli A, Corsi A, Milanese G, Surace A, Di Marco F, et al. Chest X-ray for predicting mortality and the need for ventilatory support in COVID-19 patients presenting to the emergency department. Eur Radiol. 2021;31(4):1999-2012.

3. Rubin GD, Ryerson CJ, Haramati LB, Sverzellati N, Kanne JP, Raoof S, et al. The role of chest imaging in patient management during the COVID-19

pandemic: A multinational consensus statement from the Fleischner society. Chest. 2020;158(1):106-16.

4. Pan F, Ye T, Sun P, Gui S, Liang B, Li L, et al. Time course of lung changes on chest CT during recovery from 2019 novel Coronavirus (COVID19) pneumonia. Radiology 2020;295(3):715-7.
5. Jacobi A, Chung M, Bernheim A, Eber C. Portable chest X-ray in Coronavirus Disease-19 (COVID-19): A pictorial review. Clin Imaging. 2020;64:35-42.
6. Wong HYF, Lam HYS, Fong AHT, Leung ST, Chin TW, Lo CSY, et al. Frequency and distribution of chest radiographic findings in patients positive for COVID-19. Radiology. 2020;296(2):E72-8.
7. Cleverley J, Piper J, Jones MM. The role of chest radiography in confirming COVID-19 pneumonia. BMJ. 2020;370:m2426.
8. Borghesi A, Zigliani A, Masciullo R, Golemi S, Maculotti P, Farina D, et al. Radiographic severity index in COVID-19 pneumonia: Relationship to age and sex in 783 Italian patients. Radiol Med. 2020;125(5):461-4.
9. Hui TCH, Khoo HW, Young BE, HajaMohideen SM, Lee YS, Lim CJ, et al. Clinical utility of chest radiography for severe COVID-19. Quant Imaging Med Surg. 2020;10(7):1540-50.
10. Al-Smadi AS, Bhatnagar A, Ali R, Lewis N, Johnson S. Correlation of chest radiography findings with the severity and progression of COVID-19 pneumonia. Clin Imaging. 2021;71:17-23.
11. Toussie D, Voutsinas N, Finkelstein M, Cedillo MA, Manna S, Maron SZ, et al. Clinical and chest radiography features determine patient outcomes in young and middle-aged adults with COVID-19. Radiology. 2020;297(1):E197-206.