Clinics in Oncology

Case Report
Published: 12 Sep, 2018

Technique for Tongue Release in Patients Submitted to Glossectomy and Primary Closure

*Laurindo Moacir Sassi, Bruna da Fonseca Wastner and William Phillip Pereira da Silva**

Department of Oral and Maxillofacial Surgery, Erasto Gaertner Hospital, Brazil

Abstract

The rehabilitation of speech and swallowing are critical for patients submitted to tumor resection on the tongue and, in cases of extensive lesions, with even greater impairment, serious damage to the quality of life of individuals are expected. When excision of the tumor followed by a primary closure is the defined treatment, the patient may experience difficulty in phonation by reducing the tongue mobility, which may be associated with dysphagia and even impossibility of adapting conventional complete dentures. Thus, the aim of this paper is to present a surgical technique for cancer release in cancer patients, specifically those patients with tongue and floor of the mouth tumors on I and II who underwent surgical resection. The technique is easy and quick, possible to be performed under local anesthesia and with low complications.

Keywords: Tongue; Prosthesis; Tumor

Introduction

Patients with tumors in the head and neck, in general, are likely to functional and aesthetic losses resulting from the treatment of the disease, which is usually composed by surgery and radiotherapy. In these cases, rehabilitation of speech and swallowing are critical and, in cases of extensive lesions, with even greater impairment, serious damage to the quality of life of individuals is expected [1]. Functional deficits depend mainly on factors such as location and tumor stage, type of treatment, extent of resection in surgical cases, type of reconstruction and possibility of professional physiotherapy and speech therapy. Even in non-surgical cases, as isolated irradiation or irradiation combined with chemotherapy, there are functional sequelae associated mainly with the fibrosis of the tissues [2].

In the tongue and mouth floor tumors on stages I and II, there is the possibility of more conservative surgery, without reconstruction with flaps. In such cases, it is carried out the primary closure of the wound after resection of the lesion with suitable margins, usually using the tongue to assist in the construction on the new floor of the mouth [3]. Through this technique, the patient may experience difficulty in phonation by reducing the tongue mobility, which may be associated with dysphagia, which can lead to nutritional impairment of patients. Another relevant factor is the difficulty and even impossibility of adapting conventional complete dentures, removed from its position by the remaining tongue that is attached to the ridge and form the new floor of the mouth [4].

Thus, the aim of this paper is to present a surgical technique for cancer release in cancer patients, specifically those patients with tongue and floor of the mouth tumors on I and II who underwent surgical resection.

Technique

The surgery begins with the demarcation of the incision area on the edge of the tongue on the affected side, which extends throughout the region where there is entrapment of the tongue. The incision is performed with cold scalpel 15 blade in a thickness of approximately 3 mm (Figure 1) thru the region of the floor of the mouth. So, held the divulsion of tongue tissue in the anterior and posterior regions in a lower direction in order to release the regions of intense fibrosis. Then, bending the incised tissue to position it below the tongue, forming the new mouth floor (Figure 2). This tissue is sutured to the mouth floor with Vicryl 3-0 with U stitches, in order to obtain a more secure anchoring. The edges of the wound that are bloody may receive simple sutures with the purpose of hemostasis, which may be replaceable by cauterization by electro cautery (Figure 3). During the perioperative time, the release of the tongue and a greater mobility is visible (Figure 4). The surgery

OPEN ACCESS

***Correspondence:**
William Phillip Pereira da Silva, Department of Oral and Maxillofacial Surgery, Erasto Gaertner Hospital, Ovande do Amaral Street, 201, Jardim das Américas, Curitiba, Paraná, 81520-060, Brazil,
E-mail: william_phillip@hotmail.com

Received Date: *10 Aug 2018*
Accepted Date*: 03 Sep 2018*
Published Date*: 12 Sep 2018*

Citation:
Sassi LM, da Fonseca Wastner B, da Silva WPP. Technique for Tongue Release in Patients Submitted to Glossectomy and Primary Closure. Clin Oncol. 2018; 3: 1517.

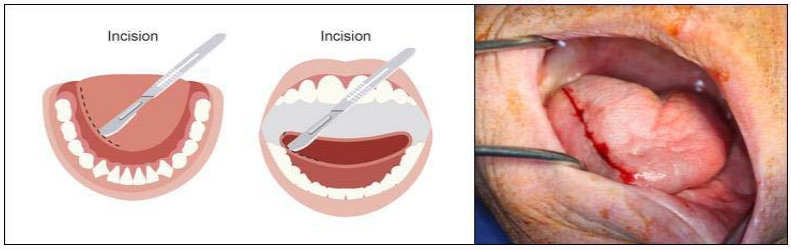

Figure 1: On the left side, schema of the incision on a superior and anterior view. On the right, clinical image of the incision.

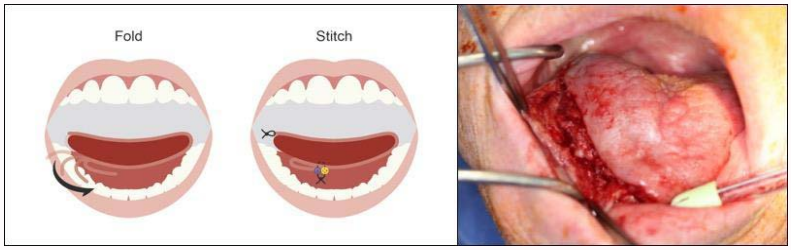

Figure 2: On the left side, schema of the divulsion and folding of the tissue, with the sutures. On the left, clinical image showing aspect after divulsion, preparing to folder the tissue.

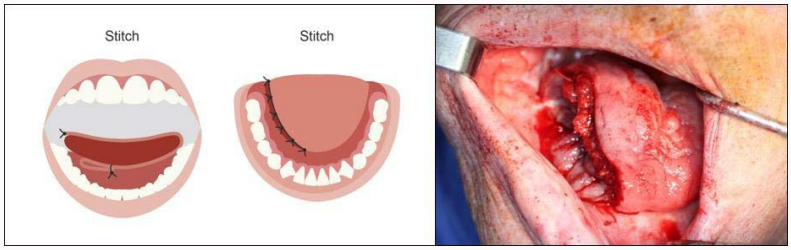

Figure 3: On the left side, final aspect with the sutures. On the right, clinical image of a patient with the sutures in position.

may be performed with general or local anesthesia, depending on the extent of the area and patient cooperation. It is recommended to keep liquid cold diet in the first 3 days postoperatively, starting early with tongue mobilization exercises accompanied by speech therapist. The use of antibiotics is limited to the hospital stay, according to the protocol of each institution.

Discussion

A successful treatment for patients with tumors in the head and neck is achieved not only by surgical or non-surgical modalities (radiotherapy and chemotherapy) aimed at the elimination of injury, but also additional treatment by a multidisciplinary team of physical therapists, dieticians, speech therapists and dentists, among others [5]. Studies show that although more than half of patients with head and neck cancer present dysphagia after treatment, usually this problem is not noticed spontaneously by the patient [6]. A pre-treatment dental evaluation is critical for these patients, regardless of treatment modality, considering that the rehabilitation of speech and swallowing may be compromised by dental conditions, especially in those with dental prosthesis [7].

The mobility of the tongue is one of the most critical components of the beginning of swallowing and subsequent stimulus to the stimulation of the pharyngeal phase [8]. Overall, resections that preserve the local innervation combined with reconstruction techniques that allow residual movement of the tongue, especially on the posterior regions and the base, result in improved speech and swallowing. The articulation and the oral stage of swallowing are most severely affected when the tongue is sutured in the floor of the mouth or the vestibule [4,9].

Figure 4: On the right side, clinical image during the surgery showing the greater mobility of the tongue that should be observed in this period.

Eventually, only physic and speech therapies are not sufficient to offset the deficits acquired with glossectomy and pelvectomy. At this point, one may highlight the role of complementary surgeries in order to release the area for better local mobilization and development of functional rehabilitation. Such techniques, as described in this paper

also facilitate the adaptation of dental prosthesis and avoid areas of trauma and ulcerations in cases where the teeth in the region were preserved.

References

1. Kenneth HJ Wu. The management of head and neck cancer. Surgery. 2009;27(12):540-5.
2. Smith RV, Kotz T, Beitler JJ, Wadler S. Long-term swallowing problems after organ preservation therapy with concomitant radiation therapy and intravenous hydroxyurea: initial results. Arch Otolaryngol Head Neck Surg. 2000;126(3):384-9.
3. National Comprehensive Cancer Network. NCCN guidelines for treatment of cancer by site.
4. Sun J, Weng Y, Li J, Wang G, Zhang Z. Analysis of Determinants on Speech Function After Glossectomy. J Oral Maxillofac Surg. 2007;65(10):1944-50.
5. Langendijk JA, Doornaert P, Rietveld DH, Verdonck-de Leeuw IM, Leemans CR. A predictive model for swallowing dysfunction after curative radiotherapy in head and neck cancer. Radiother Oncol. 2009;90(2):189-95.
6. Pauloski BR, Rademaker AW, Logemann JA, Stein D, Beery Q, Newman L, et al. Pretreatment swallowing function in patients with head and neck cancer. Head Neck. 2000;22(5):474-82.
7. Martins MVG, Vale-Prodomo LP, Carrara-de Angelis E. Effect of palatal augmentation prosthesis in swalling and speech articulation in a patient submitted to total glossectomy: Case report. Revista Fonoaudiologia Brasil. 2005;4:1-4.
8. Brown JS, Rogers SN, Lowe D. A comparison of tongue and soft palate squamous cell carcinoma treated by primary surgery in terms of survival and quality of life outcomes. Int J Oral Maxillofac Surg. 2006;35(3):208-14.
9. Kimata Y, Sakuraba M, Hishinuma S, Ebihara S, Hayashi R, Asakage T, et al. Analysis of the relations between the shape of the reconstructed tongue and postoperative functions after subtotal or total glossectomy. Laryngoscope. 2003;113(5):905-9.