



Pancytopenia: An Unusual Presentation of Breast Cancer: A Case Report

Burak Ilhan^{1*}, Berkay Kılıç², Süleyman Bademler², Rüştü Türkay³, Fatma Şen⁴ and Hasan Karanlık²

¹Department of General Surgery, Istanbul University, Istanbul Medical Faculty, Turkey

²Surgical Oncology Unit, Institute of Oncology, Istanbul University, Turkey

³Department of Radiology, Istanbul Bakirkoy Dr. Sadi Konuk Training and Research Hospital, Turkey

⁴Department of Medical Oncology, Institute of Oncology, Istanbul University, Turkey

Abstract

Case Report: This present study reports the case of a forty nine years old female with a story of paleness, palpitations and fatigue. Complete Blood Count (CBC) has pointed pancytopenia. A bone marrow biopsy was performed and the analysis was revealed metastasis of carcinoma. Patient was diagnosed as bilateral breast carcinoma with bone marrow involvement after physical examination and specific imaging methods. No further metastases were identified and taxane and 5-fluorouracil (5-FU) based chemotherapy with steroid therapy was started. Surgical intervention of the bilateral breast was performed following chemotherapy. Patient was disease free during the 4 years of follow-up.

Conclusion: It is important to attract clinicians attention, if a patient admitted with pancytopenia, the source can be breast cancer.

Keywords: Bone marrow; Breast neoplasm; Pancytopenia

Introduction

The most common metastatic lesion of the breast cancer is metastasis to contralateral breast [1,2]. Twenty percent of women with operable breast cancer eventually relapse, with about 70% of the relapses as distant metastases [3,4]. Skeletal metastases were seen in patients with metastatic breast cancer, which causes pathologic fractures, spinal cord compression as the result of vertebral compression fracture or extension of the tumor beyond the epidural space, and hypercalcemia. Skeletal metastases have rarely results with destruction of the bone tissue matrix by tumor cells. Alkaline phosphatase level in the bone marrow metastasis is worth especially where a high osteoblastic activity is typical of breast and prostate cancer metastasis. But metastasis of breast cancer directly to bone marrow is uncommon. Bone marrow micrometastases are in 30.6% of Stage I through III breast cancer patients, total bone marrow involvement and pancytopenia was extremely rare [5].

Case Presentation

Forty nine years-old woman had presented to our surgery clinic with one month story of paleness, palpitations and fatigue. Pancytopenia was determined with CBC. White Blood Cell (WBC) count was 1.4 K/ μ L, hemoglobin (hgb) was 8.2 K/ μ L, and platelet count was 112 K/ μ L. She was referred to hematology unit with the suspicion of chronic myeloid leukemia. Carcinoma metastasis was determined at the bone marrow biopsy (Figure 1).

Breast masses were determined in the left breast and axillary region in physical examination. At mammogram, ultrasonography (Figure 2) and MRI an irregular 3 cm mass in the left, 2 cm in the right breast and pathologic left axillary lymph node was determined. A tru-cut biopsy from irregular mass of the bilateral breasts and fine needle biopsy from left axillary lymph node were performed under ultrasonographic guidance. Bilateral invasive lobular carcinoma was determined (Figure 3). Bilateral breast biopsy revealed tripple negative tumor positron emission tomography was performed and high metabolic activity was found in upper outer quadrant of the left breast (SUVmax = 9.2) and in the left axillary lymph nodes (SUVmax = 6.7). Metabolic activity was moderetaly increased in the bone marrow (SUVmax = 3.2). Taxotere (75 mg/m²) and caphesitabine (500 mg p.o. daily) treatment

OPEN ACCESS

*Correspondence:

Burak Ilhan, Department of General Surgery, Istanbul Faculty of Medicine, Istanbul University, Millet Caddesi, 34093 Fatih, Istanbul, Turkey, E-mail: burakmd@yahoo.com

Received Date: 14 Nov 2016

Accepted Date: 03 Jan 2017

Published Date: 30 Jan 2017

Citation:

Ilhan B, Kılıç B, Bademler S, Türkay R, Şen F, Karanlık H. Pancytopenia: An Unusual Presentation of Breast Cancer: A Case Report. *Clin Oncol.* 2017; 2: 1191.

Copyright © 2017 Burak Ilhan. This is an open access article distributed under the Creative Commons Attribution License, which permits unrestricted use, distribution, and reproduction in any medium, provided the original work is properly cited.

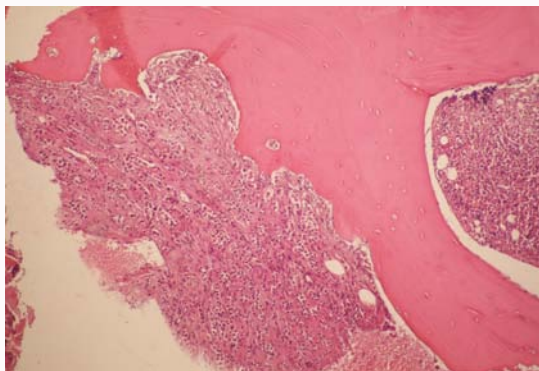


Figure 1: Bone marrow biopsy (Colored by H-E x 40).

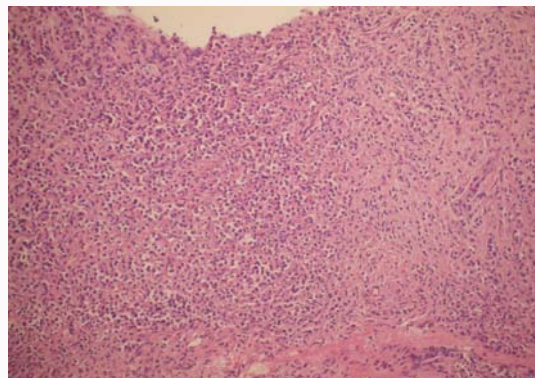


Figure 3: Breast tru-cut biopsy (colored by H-E x 40).

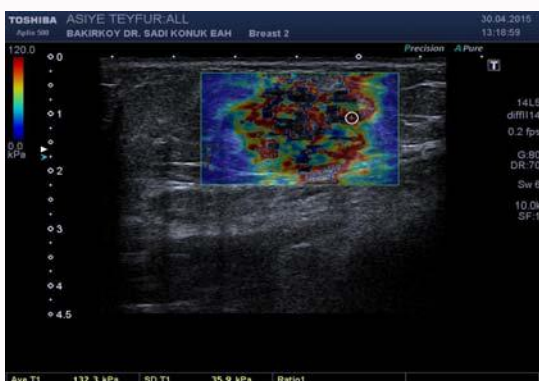


Figure 2: USG imaging.

with steroid therapy. Bilateral mastectomy, left axillary dissection and sentinel lymph node biopsy of right axilla were performed. No metastasis was found on right sentinel lymph node biopsy. The histopathologic evaluation of bilateral mastectomy specimens revealed pathological partial response in both breast tumor. The patient went on to receive further 6 cycles of capecitabine (2000 mg/m² per day on days 1 to 14, repeated every 21 days) for her breast cancer. Patient was disease-free in 4 years follow-up, with complete recovery of normal bone marrow function.

Discussion

Bone marrow infiltration with pancytopenia due to breast cancer metastasis was very uncommon. Bone marrow failure with pancytopenia as a precursor of the disease is not typically seen [6]. Bone marrow metastasis could frequently occur with advanced or metastatic breast cancer. There were limited data for treating patient safely and efficiently, which has pancytopenia due to metastatic breast tumor involvement. Because clinical trials usually include patient with near-normal hematologic parameters, the patients with cytopenias due to bone marrow metastases of breast cancer are also generally excluded from clinical trials [7]. Additionally, in patients with hormone receptor negative breast cancer, the myelosuppressive effect of most cytotoxic drugs complicates attempts at chemotherapy [8]. Thus, in the literature data about the results of systemic chemotherapy including response to chemotherapy, severity of side effects and outcome of the disease is insufficient to guide systemic therapy in patients with bone marrow metastasis of breast cancer [9].

In this case, there was increased and highly important infection risk due to leukopenia, also paleness, throb and fatigue were occurred because of anemia. Thrombocytopenia was not so deep. The

patient's dramatic response to chemotherapy with full leukocyte and hemoglobin recovery was highly unusual. Pancytopenia is not a common presentation in patients with metastatic breast cancer. In rare studies, bicytopenia was noted, which has presented by immune thrombocytopenic purpura and anemia [10].

In our study, bone marrow infiltration with metastatic breast cancer was the primary cause of pancytopenia. This has rarely been described in the literature and includes both patients with positive and negative outcomes from therapy. Another study reported that capecitabine combined with steroid treatment has provided excellent response, so that treatment has allowed surgery [6]. A patient received treatment with continuous doxorubicin and zoledronic acid followed by endocrine therapy, which resulted in complete recovery of normal bone marrow function with good performance status. Several reports highlight patients who have responded to systemic therapy including low dose capecitabine, endocrine therapy and trastuzumab monotherapy [11-13].

As a conclusion, the authors had aimed to determine the management of this rare disease. A combination chemotherapy consisting of docetaxel (75 mg/m² intravenously on day 1) and capecitabine (1000 mg/m² per day on days 1 to 14), each repeated every 21 days and steroid therapy were initiated in cooperation with oncology. After two cycles of chemotherapy, all the cellular components in blood completely recovered without additional G-CSF support or transfusion of blood components. Furthermore, primary tumor regressed without any serious adverse effects. She completed a total of six cycles of combination chemotherapy. She was willing to undergo breast operation. Thus, bilateral mastectomy, left axillary dissection and sentinel lymph node biopsy of right axilla were performed. No metastasis was found on right sentinel lymph node biopsy. After adjuvant therapy patient was disease-free in 4 years follow-up, with complete recovery of normal bone marrow function. Bone marrow involvement of breast cancer accepted isolated metastasis and curative surgical treatment provided prolonged disease-free survival.

Ethics Committee Approval

The Ethics committee approval is Not Available (N/A).

Informed Consent

Written informed consent was obtained from the patient.

Conflict of Interests

Authors have declared that no competing interests exist.

References

1. Georgiannos SN, Chin J, Goode AW, Sheaff M. Secondary neoplasms of the breast: a survey of the 20th Century. *Cancer*. 2001; 92: 2259-2266.
2. Kennecke H, Yerushalmi R, Woods R, Cheang MC, Voduc D, Speers CH, et al. Metastatic behavior of breast cancer subtypes. *J Clin Oncol*. 2010; 28: 3271- 3277.
3. Manders K, van de Poll-Franse LV, Creemers GJ, Vreugdenhil G, van der Sangen MJ, Nieuwenhuijzen GA, et al. Clinical management of women with metastatic breast cancer: a descriptive study according to age group. *BMC Cancer*. 2006; 6: 179.
4. Ahn SG, Lee HM, Cho SH, Lee SA, Hwang SH, Jeong J, et al. Prognostic factors for patients with bone-only metastasis in breast cancer. *Yonsei Med J*. 2013; 54: 1168-1177.
5. Hüsemann Y, Geigl JB, Schubert F. Systemic spread is an early step in breast cancer. *Cancer Cell*. 2008; 13: 58-68.
6. Vo JL, Yang L, Kurtz SL, Smith SG, Koppolu BP, Ravindranathan S, et al. Neoadjuvant immunotherapy with chitosan and interleukin-12 to control breast cancer metastasis. *Oncoimmunology*. 2015; 3: e968001.
7. Wong KF, Chan JK, Ma SK. Solid tumour with initial presentation in the bone marrow-a clinicopathologic study of 25 adult cases. *Hematol Oncol*. 1993; 11: 35-42.
8. Rodriguez-Kraul R, Hortobagyi GN, Buzdar AU, Blumenschein GR. Combination chemotherapy for breast carcinoma metastatic to bone marrow. *Cancer*. 1981; 48: 227-232.
9. Ballot J, McDonnell D, Crown J. Successful treatment of thrombocytopenia due to marrow metastases of breast cancer with weekly docetaxel. *J Natl Cancer Inst*. 2003; 95: 831-832.
10. Kopp HG, Krauss K, Fehm T, Staebler A, Zahm J, Vogel W, et al. Symptomatic bone marrow involvement in breast cancer-clinical presentation, treatment, and prognosis: a single institution review of 22 cases. *Anticancer Res*. 2011; 31: 4025-4030.
11. Freyer G, Ligneau B, Trillet-Lenoir V. Palliative hormone therapy, low-dose chemotherapy, and bisphosphonate in breast cancer patients with bone marrow involvement and pancytopenia: report of a pilot experience. *Eur J Intern Med*. 2000; 11: 329-333.
12. Bjelic-Radisic V, Stöger H, Winter R, Beham-Schmid C, Petru E. Long-term control of bone marrow carcinosis and severe thrombocytopenia with standard-dose chemotherapy in a breast cancer patient: a case report. *Anticancer Res*. 2006; 26: 1627-1630.
13. Xu L, Guo F, Song S, Zhang G, Liu Y, Xie X. Trastuzumab monotherapy for bone marrow metastasis of breast cancer: a case report. *Oncol Lett*. 2014; 7: 1951-1953.