Clinics in Oncology

Clinical Image
Published: 23 Dec, 2017

# Lung Adenocarcinoma Mimicking Interstitial Lung Disease

*Füsun Şahin[1]* and Nural Ören[2]*

[1]*Department of Chest Disease, University of Health Sciences/Yedikule Chest Disease and Thoracic Surgery Health Practice and Research Center, Istanbul, Turkey*

[2]*Department of Pathology, University of Health Sciences/Yedikule Chest Disease and Thoracic Surgery Health Practice and Research Center, Istanbul, Turkey*

## Clinical Image

Lung adenocarcinoma can have highly variable clinical presentation, and range from a small solitary nodule or limited number of nodules, to more extensive miliary disease, or diffuse parenchymal infiltrates that are similar in appearance to bacterial pneumonia. The exact mechanism of lung adenocarcinoma pathogenesis is still being investigated, however it appears that tumor proliferation is eclipsed by noticeable inflammation and fibrosis that mimic a benign inflammation, thus confusing physicians and consequently delaying diagnosis, as well as affecting quality of patients' life [1]. Lung adenocarcinoma shows specific staining patterns, which are useful in the differential diagnosis of poorly differentiated neoplasms. These patterns are positive: TTF-1, napsin A, CK 7, mucicarmine, PAS-D [2,3].

Our case was a 51-year-old male patient who was admitted to our outpatient clinic with complaints of dry cough, shortness of breath with exertion and pain at the joints for the last 2 months. Postero-anterior chest X-ray showed bilateral infiltration in the lower zones (Figure 1). Thorax computed tomography showed widespread frosted glass and interstitial thickening, more prominent in the lower lobes in both lungs (Figure 2 and 3). No pathology was found in hemogram,

**Figure 1**: Postero-Anterior Chest X-Ray İmage.

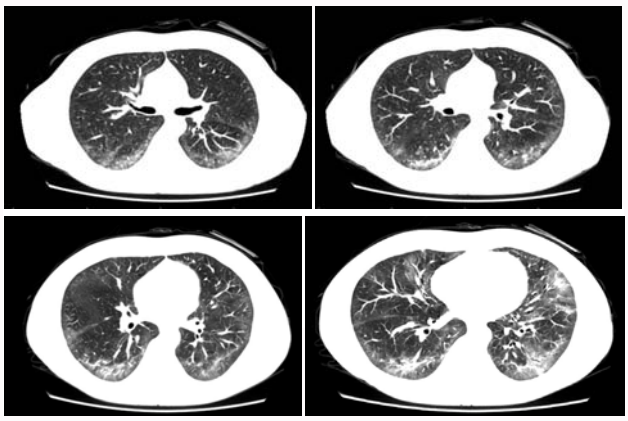

**Figure 2**: Thorax Computed Tomography Images.

**OPEN ACCESS**

***Correspondence:***
*Füsun Şahin, Department of Chest Disease, University of Health Sciences/ Yedikule Chest Disease and Thoracic Surgery Health Practice and Research Center, Istanbul, Turkey,*
*E-mail: fusunsahin19700@hotmail.com*

**Received Date**: *13 Nov 2017*
**Accepted Date***: 28 Nov 2017*
**Published Date***: 23 Dec 2017*

***Citation:***
*Şahin F, Ören N. Lung Adenocarcinoma Mimicking Interstitial Lung Disease. Clin Oncol. 2017; 2: 1388.*

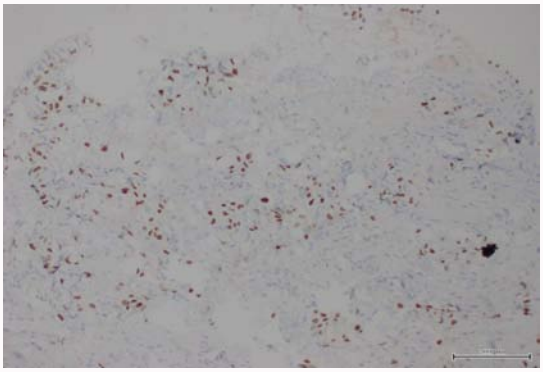

**Figure 3**: TTF1 (+) in immunohistochemical staining.

biochemistry and serological blood tests of the patient. In order to investigate the etiology of interstitial lung disease, collagen tissue markers were requested and all were negative. The patient underwent bronchoscopy. Both bronchial systems are normal and open. Transbronchial parenchyma biopsies were taken from the lateral and posterior segments of the left lower lobe. Pathological consequences of transbronchial biopsies performed by immunohistochemical staining are "Pancytokeratin and TTF 1 (+). Lung adenocarcinoma, which produces diffuse infiltration in the sub epithelial area under the bronchial epithelium ". PET/CT was requested for body scanning. SUV max: 3.2 interstitial involvement was observed in PET/CT, especially in the bilateral lung subfields, and there was no pathological involvement in other systems. The patient was sent to oncology clinic with diagnosis of inoprabl lung adenocarcinoma. Our case is presented because of its interesting radiological appearance and emphasizing that it may be especially adenocarcinoma in the etiology of interstitial lung diseases.

## References


1. Lantuejoul S, Colby TV, Ferretti GR, et al. Adenocarcinoma of the lung mimicking inflammatory lung disease with honeycombing. Eur Respir J. 2004; 24(3): 502-5.
2. Shah RN, Badve S, Papreddy K, Schindler S, Laskin WB, Yeldandi AV, et al. Expression of cytokeratin 20 in mucinous bronchioloalveolar carcinoma. Hum Pathol. 2002; 33(9): 915-20.
3. Raparia K, Ketterer J, Dalurzo ML, Chang YH, Colby TV, Leslie KO. Lung tumors masquerading as
4. desquamative interstitial pneumonia (DIP): report of 7 cases and review of the literature. Am J Surg Pathol. 2014; 38: 921-924.