



An Unusual Presentation of Metastatic Gastric Cancer with EML4-ALK Rearrangement Treated with Alectinib

Ee Jie Yeo¹, Lih Ling Goh² and Heong Valerie^{1*}

¹Department of Medical Oncology, Tan Tock Seng Hospital, Singapore

²Molecular Diagnostic Laboratory, Tan Tock Seng Hospital, Singapore

Abstract

Background: In the age of precision oncology, molecular profiling has become increasingly available, which provides the potential to guide treatment options especially for patients where the site of origin is difficult to determine. Here, we present a case of a patient with EML4-ALK rearrangement in a gastric cancer, where molecular profiling helped guide therapeutic options.

Case Report: Mr. C is a 54-year-old, Asian, male, non-smoker, who initially presented with hematemesis, melena and gradual reduction of exercise tolerance. Staging scans revealed lesions in bladder, bone and lymphagitis. A transurethral resection of bladder tumor was done that revealed signet ring carcinoma. Subsequent oesophageal-gastro-duodenoscopy biopsied a gastric ulcer with similar morphology. After failing first line treatment of platinum-based chemotherapy, molecular profiling was performed which showed EML4-ALK fusion and after discussion with the patient, Alectinib was initiated. Patient responded well to Alectinib, with improvements both clinically and radiologically.

Conclusion: The case study highlights the utility of molecular profiling in clinical practice to help guide the use of targeted treatment. This case was complicated by his unusual presentation and was initially treated with standard of care chemotherapy. With next generation sequencing tools available at our centre, we were able to provide treatment based on presumed oncogenic drivers which proved beneficial in his case. However, this approach would need to be validated in larger tumour-agnostics' basket studies based on molecular markers of interest.

OPEN ACCESS

*Correspondence:

Valerie Heong, Department of Medical Oncology, Tan Tock Seng Hospital, 11, Jalan Tan Tock Seng, 308433, Singapore, Tel: +65 62566011; E-mail: valerie_ym_heong@tsh.com.sg

Received Date: 23 Aug 2021

Accepted Date: 13 Sep 2021

Published Date: 17 Sep 2021

Citation:

Yeo EJ, Goh LL, Valerie H. An Unusual Presentation of Metastatic Gastric Cancer with EML4-ALK Rearrangement Treated with Alectinib. *Clin Oncol.* 2021; 6: 1859.

ISSN: 2474-1663

Copyright © 2021 Heong Valerie. This is an open access article distributed under the Creative Commons Attribution License, which permits unrestricted use, distribution, and reproduction in any medium, provided the original work is properly cited.

Introduction

Molecular profiling has allowed targeted therapies for various cancers. This is especially useful when the site of origin for cancer is indeterminate. The Princess Margaret IMPACT/COMPACT trial has demonstrated higher response rates in patients treated on genotype-matched trials (19%) when compared with genotype unmatched trials (9%) [1]. Given such response rates, molecular profiling should be offered as first line treatment or earlier lines of treatment. This case study highlights the potential benefit of molecular profiling guiding treatment. For this case study, we will be reviewing a patient with EML4-ALK rearrangement profile that clinically and radiologically responded to Alectinib.

Case Presentation

Mr. C is a 54-year-old Male, initially presented with hematemesis, melena associated with epigastric pain, and gradual worsening of shortness of breath on exertion for 6 months. A Computed Tomography (CT) pulmonary angiogram was performed which revealed lymphangitis carcinomatosa with numerous sclerotic bone lesions. Subsequent CT scan of the abdomen and pelvis revealed nodularity along the urinary bladder and proximal ureter as seen in Figure 1. A bone scan confirmed multiple osteoblastic foci along spine and ribs corresponding to sclerotic lesions on the CT scan.

He subsequently had a Magnetic Resonance Imaging (MRI) of the prostate and a CT Urogram which revealed filling defects in the left proximal ureter and bladder suspicious for urothelial malignancy while MRI prostate confirmed the appearance of multiple sub-centimeter nodules along the wall of the urinary bladder (Figure 1). He subsequently underwent a flexible cystoscopy which showed multiple sessile tumors over left and right lateral walls, and trigone as seen in Figure 2. A transurethral resection of bladder tumour, with left ureteroscopy and retrograde pyelography was performed and histological examination showed invasive carcinoma with signet ring cells that is

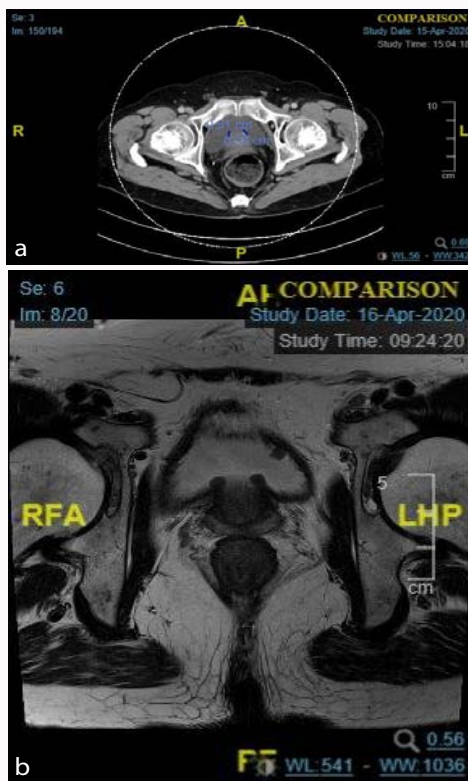


Figure 1: (Left to Right) a) CT AP showing nodular foci in bladder b) MRI pelvis with imaging of bladder.

positive for p63 and 34BE12. Discussion at tumour board between the proceduralist and pathologist concluded that lesions appear more in keeping with metastatic deposits rather than primary urothelial lesions.

1 patient de-identified. Consent has been obtained from the patient to publish information and to use images from scans as well as scopes for the purpose of the case report and patient is agreeable.

As Mr. C initially presented with melena and hematemesis, he underwent a colonoscopy and Oesophageal-Gastro-Duodenoscopy (OGD) which found a forest 3 gastric lesion (Figure 2), hemorrhoids, left sided colonic diverticulosis, and colonic polyps. Histology from the colonic lesions were tubular adenoma with low grade dysplasia but the gastric lesion was found to be consistent with a signet ring adenocarcinoma. The lesion was stained for Human Epidermal growth factor Receptor 2 (HER 2) which was negative.

Based on his presentation and histological findings, he was treated for metastatic gastric cancer. He received Oxaliplatin (130 mg/m²) once every 3 weeks and Capecitabine (1000 mg/m²) twice a day for 14 days every 3 weeks. However, after 2 cycles of treatment, he started experiencing worsening chest pain and shortness of breath. A staging CT chest/abdomen and pelvis after cycle 2 revealed left middle lobes collapsed/consolidation (Figure 3B) and new right sided pleural effusion with worsening bone metastasis. At this time, tissue from the bladder was used for NGS molecular profiling (Foundation One) [2], which revealed an EML4-ALK rearrangement (Table 1). After a long discussion with his primary oncologist, he opted for tyrosine kinase inhibitor, Alectinib instead of second line chemotherapy. A month after commencing Alectinib, his chest pains resolved and after 2 months, his exercise tolerance had improved. Five months after initiation of Alectinib, subsequent CT scans showed improvement in ground glass changes in the lungs and stable bone lesions (Figure 3C). In view of prolonged QTc and bradycardic episodes, with a known background of heart failure, cardiology consult was initiated. His heart failure was medically managed and he continues to tolerate Alectinib. At time of writing this case report, Mr. C is still on Alectinib >12 months after starting treatment with ongoing improved clinical

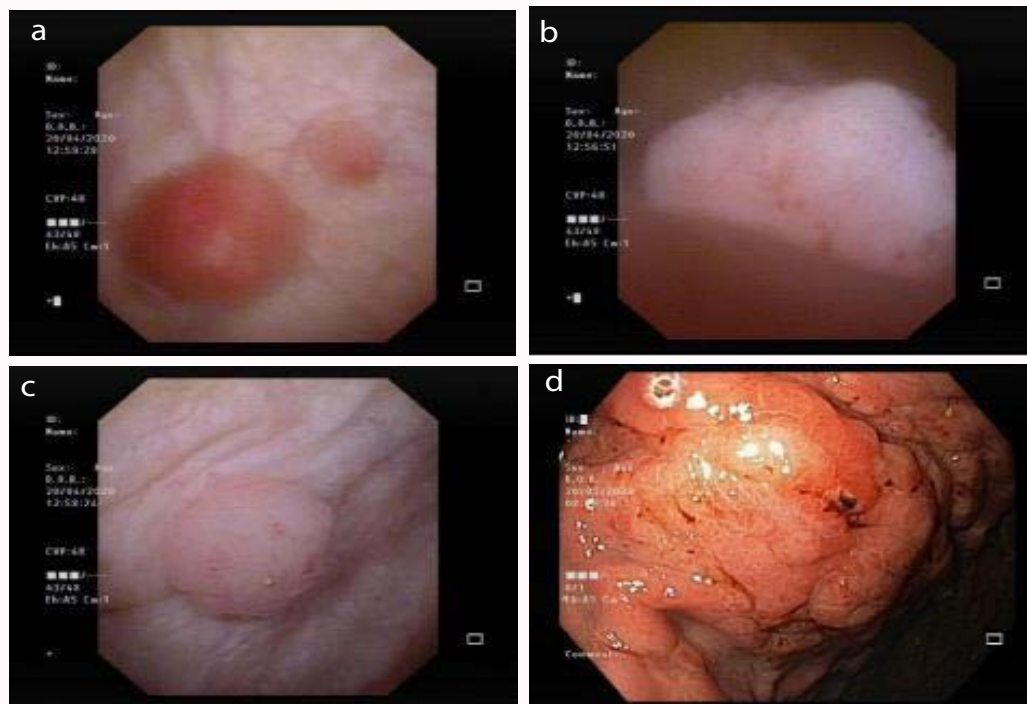


Figure 2: Images of cystoscopy and OGD (Left to right) a) left lateral wall of bladder, b) trigone of bladder, c) right lateral bladder, d) Forest 3 ulceration seen which histology showed signet ring carcinoma.

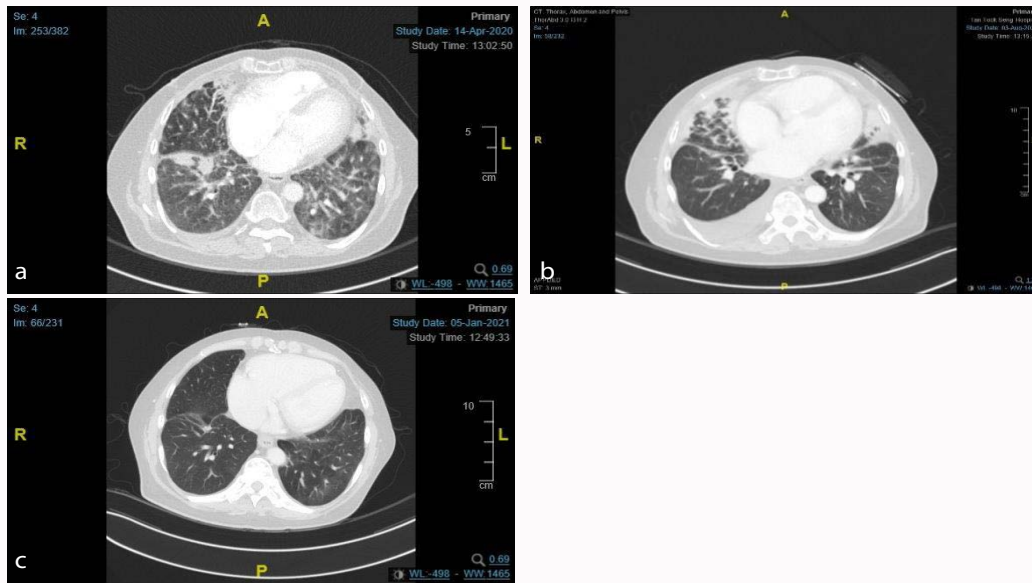


Figure 3: (Clockwise, starting from left a) CT Pulmonary angiogram showing lymphangitis in April 2020, b) CT scan post 2 cycles of CAPOX, c) CT thorax done in Jan 2021 after initiation of alectanib.

Table 1: Showing foundation 1 results for Mr. C.

Biomarker Findings	Genomic Findings
Microsatellite status: Microsatellite stable	ALK: EML4-ALK fusion (Variant 1)
Tumour Mutational Burden: 4 Muts/Mb	

and radiological response.

Discussion

EML4-ALK rearrangements are seen in 3% to 13% of lung cancers, with majority of these patients being East Asian descent, younger, non-smokers and tend to be adenocarcinomas with predominant signet ring features [3-6]. EML4-ALK fusions typically presents with adenocarcinomas histology with EGFR/KRAS negative mutations [4,6,7]. Variants of the fusion have been identified as EML4 is truncated to fuse with domain of ALK that begins in the end portion of exon 20, with the most common being variant 1 and variant 3 [3-6,8,9]. A systematic review conducted by He et al. [9] reviewed 39 articles, observed the prevalence of variants 1 to 3 was 81.84%, with a sub analysis showing prevalence of variant 1 to be 40.38% (95% CI: 34.83% to 45.93%) and 26% (95% CI: 20.89% to 32.2%) for variant 3 [9]. These fusions have also been observed in non-tumour lung samples, with 4 out of 67 (6%) have displayed presence of variant 1 while and 6/67 showed variant 3 [10].

Among the variants of EML4-ALK fusion, a greater number of ALK resistance is seen in variant 3 as compared to variant 1 [8,11]. Study by Su et al. [11] showed that EML4-ALK positive non-small cell lung cancer harboring variants 3 and 5 displaying significantly lower progression free survival (8.6 vs. 11.3 months, p=0.046) and overall survival (31.0 vs. 37.6 months, p=0.026) when patients receive crizotinib.

As mentioned above, one of the features of EML4-ALK is presence of signet ring histology. A retrospective population-based analysis conducted by Ou et al. [12] looked at signet ring cell of lung cancer in California Cancer Registry between 1989 to 2006 found 262 histologically diagnosed primary signet ring cancers as compared to

50,089 lung adenocarcinomas. Another study by Boland et al. [13] revealed that 7% (n=53) of 763 cases were signet ring carcinoma, with KRAS mutations being the most common (29%). Both studies also found that patients with signet ring histology often confer to poorer prognosis, and a younger patient population. Commonly found in lung adenocarcinoma with signet ring cell component is a co-expression of TTF-1 and p63 as reported in study by Yoshida et al. [14]. A few studies have shown treatment response with Crizotinib for patients signet ring carcinoma lung cancer [15,16]. A single case study has demonstrated in the possibility of using leucovorin and 5-fluorouracil to treat lung cancers with signet ring histology [17].

EML4-ALK mutations although most commonly seen in NSCLC, have also been found in breast, thyroid, colorectal and gastric cancers [18,19]. A study published by Chon et al. [20] showed of the 455 gastric cancer tumors sampled of varying histology, with 73 patients having signet ring histology, 8.4% (n=38) were ALK positive by Immunohistochemistry (IHC). ALK positive patients tend to be younger, have signet ring components (n=38), with increased risk of recurrence. Other studies have demonstrated approximately 2% of gastric cancers having ALK mutations on IHC [21,22]. One of the possible reason for lung cancers to develop signet ring histology (and conversely presence of ALK mutations in gastric cancer), is possibly due to embryological origins. Embryologically, the gut and lung originate from the endoderm, with respiratory system derivatives from the formation of endodermal diverticulum. Foregut endoderm will evaginate and pushes surrounding mesenchyme to form the lung buds [23].

Given the unusual presentation of Mr. C and the subsequent response to Alectinib, a primary NSCLC without a discernible lung lesion may still be possible. Though tumour was present in the

bladder, the features and appearance of the tumour did not appear to originate from the bladder. Both gastric and lung cancer rarely metastasize to the bladder. Bates et al. [24] conducted a study on 282 secondary bladder neoplasms. The study showed that 13 cases (4.3%) of tumors that metastasize to bladder were from gastric cancer, while only 8 (2.8%) cases of lung primary metastasized to the bladder. A systematic review by Sanguedolce et al. [25] found 11 cases of bladder metastasis from lung primary between 2006-2014, with 45% (n=5) of them presenting with hematuria, while 36% (n=4) presented with hydronephrosis neither of which was evident in our patient.

This case highlights the utility of molecular profiling in personalizing treatment approaches and guiding treatment selection for our patients. Through molecular profiling via the NGS platform, we were able to identify an actionable mutation which was generally not considered relevant in gastric cancers to counsel the patient and ultimately guide treatment selection which proved efficacious in our patient. Similarly, several case studies have shown Alectinib being efficient at treating primary tumors that harbor EML4-ALK mutations other than lung cancer, such as colorectal cancer [26,27], papillary renal cell carcinoma [28], and cancer of unknown primary [29].

In summary, Mr. C is a gentleman, who presented with hematemesis, melena associated with abdominal pain who failed 1st line standard chemotherapy for metastatic gastric carcinoma. He was later found to harbor an EML4-ALK rearrangement in his tumour and was subsequently treated with Alectinib with durable response. Our case highlights the utility of molecular profiling in the management of complicated patients and suggests targeted therapies specific for a particular molecular aberration may be beneficial regardless of the primary site of tumor. This would need to be further evaluated in larger basket studies targeting biomarkers of relevance for all solid malignancies agnostic to primary site of disease to further understand the role of these oncogenic drivers in different cancer types.

References

1. Stockley TL, Oza AM, Berman HK, Leighl NB, Knox JJ, Shepherd FA, et al. Molecular profiling of advanced solid tumors and patient outcomes with genotype-matched clinical trials: The princess Margaret impact/compact trial. *Genome Med.* 2016;8(1):109.
2. Foundation Medicine. FoundationOne[®] CDx. FoundationOne CDx | Foundation Medicine.
3. Horn L, Pao W. EML4-ALK: Honing in on a new target in non-small-cell lung cancer. *J Clin Oncol.* 2009;27(26):4232-5.
4. Sasaki T, Rodig SJ, Chirieac LR, Jänne PA. The biology and treatment of EML4-ALK non- small cell lung cancer. *Eur J Cancer.* 2010;46(10):1773-80.
5. Palmer R. Faculty Opinions recommendation of EML4-ALK fusion gene and efficacy of an ALK kinase inhibitor in lung cancer. Faculty Opinions – Post-Publication Peer Review of the Biomedical Literature.
6. Shaw AT, Yeap BY, Mino-Kenudson M, Digumarthy SR, Costa DB, Heist RS, et al. Clinical features and outcome of patients with non-small-cell lung cancer who harbor EML4-ALK. *J Clin Oncol.* 2009;27(26):4247-53.
7. Zhang X, Zhang S, Yang X, Yang J, Zhou Q, Yin L, et al. Fusion of EML4 and ALK is associated with development of lung adenocarcinomas lacking EGFR and KRAS mutations and is correlated with ALK expression. *Mol Cancer.* 2010;9(1):188.
8. Lin JJ, Zhu VW, Yoda S, Yeap BY, Schrock AB, Dagogo-Jack I, et al. Impact of EML4-ALK variant on resistance mechanisms and clinical outcomes in ALK-positive lung cancer. *J Clin Oncol.* 2018;36(12):1199-206.
9. He Y, Sun LY, Gong R, Liu Q, Long YK, Liu F, et al. The prevalence of EML4- ALK variants in patients with non-small-cell lung cancer: A systematic review and meta-analysis. *Biomark Med.* 2019;13(12):1035-44.
10. Palmer R. Faculty Opinions recommendation of EML4-ALK rearrangement in non-small cell lung cancer and non-tumor lung tissues. Faculty Opinions – Post-Publication Peer Review of the Biomedical Literature.
11. Su Y, Long X, Song Y, Chen P, Li S, Yang H, et al. Distribution of ALK fusion variants and correlation with clinical outcomes in Chinese patients with non-small cell lung cancer treated with crizotinib. *Target Oncol.* 2019;14(2):159-68.
12. Ou SH, Ziogas A, Zell JA. Primary Signet-Ring Carcinoma (SRC) of the lung: A population- based epidemiologic study of 262 cases with comparison to adenocarcinoma of the lung. *J Thorac Oncol.* 2010;5(4):420-7.
13. Boland JM, Wampfler JA, Jang JS, Wang X, Erickson-Johnson MR, Oliveira AM, et al. Pulmonary adenocarcinoma with signet ring cell features. *Am J Surg Pathol.* 2014;38(12):1681-8.
14. Yoshida A, Tsuta K, Watanabe S, Sekine I, Fukayama M, Tsuda H, et al. Frequent ALK rearrangement and TTF-1/p63 co-expression in lung adenocarcinoma with signet- ring cell component. *Lung Cancer.* 2011;72(3):309-15.
15. Hao YQ, Tang HP, Liu HY. Primary signet-ring cell carcinoma of the lung treated with crizotinib: A case report. *Oncol Lett.* 2015;9(5):2205-7.
16. Duan X, Zhao X, Wang S. An ALK-positive lung adenocarcinoma with gastric and skin metastasis: A case report and literature review. *Ann Palliat Med.* 2021;10(5):5797-807.
17. Maemondo M, Saijo Y, Ebina M, Abe T, Yaekashiwa M, Satoh K, et al. Rapidly progressive primary adenocarcinoma of the lung with signet-ring cells responding to 5-fluorouracil and leucovorin: A case report. *Int J Clin Oncol.* 1997;2(1):47-50.
18. Lin E, Li L, Guan Y, Soriano R, Rivers CS, Mohan S, et al. Exon array profiling detects EML4-ALK fusion in breast, colorectal and non-small cell lung cancers. *Mol Cancer Res.* 2009;7(9):1466-76.
19. Aydemirli MD, van Eendenburg JDH, van Wezel T, Oosting J, Corver WE, Kapiteijn E, et al. Targeting EML4-ALK gene fusion variant 3 in thyroid cancer. *Endocr Relat Cancer.* 2021;28(6):377-89.
20. Chon HJ, Kim HR, Shin E, Kim C, Heo SJ, Lee C, et al. The clinicopathologic features and prognostic impact of ALK positivity in patients with resected gastric cancer. *Ann Surg Oncol.* 2015;22(12):3938-45.
21. Alese OB, El-Rayes BF, Sica G, Zhang G, Alexis D, La Rosa FG, et al. Anaplastic Lymphoma Kinase (ALK) gene alteration in signet ring cell carcinoma of the gastrointestinal tract. *Ther Adv Med Oncol.* 2015;7(2):56-62.
22. Zhao R, Jiang W, Li X, Zhang W, Song L, Chang Z, et al. Anaplastic Lymphoma Kinase (ALK) gene alteration in gastric signet ring cell carcinoma. *Cancer Biomark.* 2016;16(4):569-74.
23. Faure S, de Santa Barbara P. Molecular embryology of the foregut. *J Pediatr Gastroenterol Nutr.* 2011;52(Suppl 1):S2-3.
24. Bates AW, Baithun SI. Secondary neoplasms of the bladder are histological mimics of nontransitional cell primary tumours: Clinicopathological and histological features of 282 cases. *Histopathology.* 2000;36(1):32-40.
25. Sanguedolce F, Loizzi D, Sollitto F, Di Bisceglie M, Lucarelli G, Carrieri G, et al. Bladder metastases from lung cancer: Clinical and pathological implications: A systematic review. *Oncology.* 2017;92(3):125-34.
26. Hsiao SY, He HL, Weng TS, Lin CY, Chao CM, Huang WT, et al. Colorectal cancer with EML4-ALK fusion gene response to alectinib: A case report

- and review of the literature. *Case Rep Oncol.* 2021;14(1):232-8.
27. He X, Jiao XD, Liu K, Qin BD, Wu Y, Ling Y, et al. Clinical responses to crizotinib, alectinib, and lorlatinib in a metastatic colorectal carcinoma patient with ALK gene rearrangement: A case report. *JCO Precis Oncol.* 2021;(5):771-8.
28. Pal SK, Bergerot P, Dizman N, Bergerot C, Adashek J, Madison R, et al. Responses to alectinib in ALK-rearranged papillary renal cell carcinoma. *Eur Urol.* 2018;74(1):124-8.
29. Sugiyama K, Izumika A, Iwakoshi A, Nishibori R, Sato M, Shiraishi K, et al. Successful alectinib treatment for carcinoma of unknown primary with EML4-ALK fusion gene: A case report. *Curr Oncol.* 2021;28(3):1938-45.