



An Unexpected Finding at Bronchoscopy

Carlos Figueiredo* and Dionísio Maia

Department of Pulmonology, Santa Marta Hospital, Portugal

Keywords

Lung neoplasms; Bronchoscopy; Larynx; Superior vena cava syndrome

Clinical Image

A 64-years-old man was diagnosed with stage IV lung squamous cell carcinoma following investigation of right pleural effusion. The patient was under second line treatment with nivolumab when a worsening of cough with purulent sputum prompted a chest-X-ray that revealed total right hemithorax opacification. Bronchoscopy was performed to exclude infection and verify airway patency. Unexpectedly, we observed a right aryepiglottic fold edema and discoloration (Figure 1); without endobronchial tumor. Following the exam, the patient confirmed a progressive slight right periorbital and superior limb swelling in the last days during the morning; no collateral circulation or skin discoloration was observed on the neck or torso. Emergent contrast-enhanced chest-CT was performed and Superior Vena Cava Syndrome (SVCS) was confirmed (Figure 2). He was submitted to palliative radiotherapy. Hoarseness and laryngeal edema can be caused by SVCS [1] and we underline the importance of larynx observation at bronchoscopy.

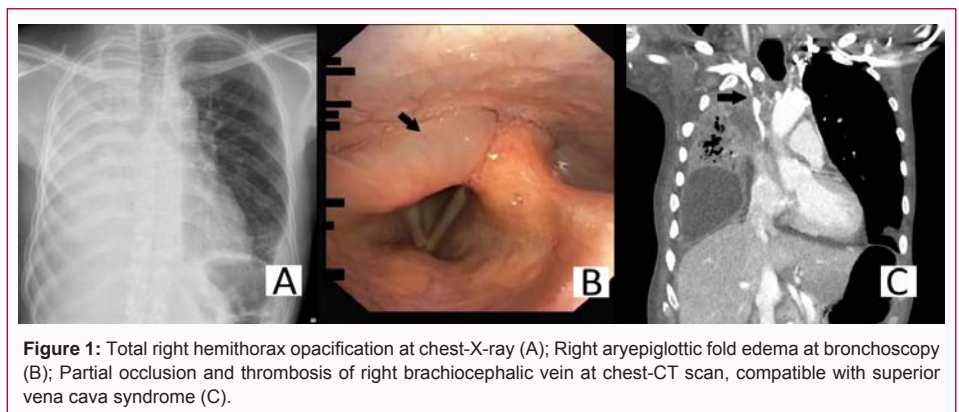


Figure 1: Total right hemithorax opacification at chest-X-ray (A); Right aryepiglottic fold edema at bronchoscopy (B); Partial occlusion and thrombosis of right brachiocephalic vein at chest-CT scan, compatible with superior vena cava syndrome (C).

OPEN ACCESS

*Correspondence:

Carlos Figueiredo, Department of Pulmonology, Santa Marta Hospital, Rua Santa Marta 50C, 1150-299 Lisboa, Portugal, E-mail: figueiredocarloslopes@gmail.com

Received Date: 03 Feb 2022

Accepted Date: 19 Feb 2022

Published Date: 01 Mar 2022

Citation:

Figueiredo C, Maia D. An Unexpected Finding at Bronchoscopy. *Clin Oncol.* 2022; 7: 1906.

ISSN: 2474-1663

Copyright © 2022 Carlos Figueiredo.

This is an open access article distributed under the Creative Commons Attribution License, which permits unrestricted use, distribution, and reproduction in any medium, provided the original work is properly cited.

References

1. Bassiouni M, Olze H, Dommerich S. Superior vena cava syndrome with laryngeal edema mimicking drug-induced angioedema: Implications for Otolaryngology. *Ear Nose Throat J.* 2020;100(8):NP379-80.